This is a digital copy of a book that was preserved for generations on library shelves before it was carefully scanned by Google as part of a project to make the world's books discoverable online.

It has survived long enough for the copyright to expire and the book to enter the public domain. A public domain book is one that was never subject to copyright or whose legal copyright term has expired. Whether a book is in the public domain may vary country to country. Public domain books are our gateways to the past, representing a wealth of history, culture and knowledge that's often difficult to discover.

Marks, notations and other marginalia present in the original volume will appear in this file - a reminder of this book's long journey from the publisher to a library and finally to you.

Usage guidelines

Google is proud to partner with libraries to digitize public domain materials and make them widely accessible. Public domain books belong to the public and we are merely their custodians. Nevertheless, this work is expensive, so in order to keep providing this resource, we have taken steps to prevent abuse by commercial parties, including placing technical restrictions on automated querying.

We also ask that you:

+ *Make non-commercial use of the files* We designed Google Book Search for use by individuals, and we request that you use these files for personal, non-commercial purposes.

+ *Refrain from automated querying* Do not send automated queries of any sort to Google's system: If you are conducting research on machine translation, optical character recognition or other areas where access to a large amount of text is helpful, please contact us. We encourage the use of public domain materials for these purposes and may be able to help.

+ *Maintain attribution* The Google "watermark" you see on each file is essential for informing people about this project and helping them find additional materials through Google Book Search. Please do not remove it.

+ *Keep it legal* Whatever your use, remember that you are responsible for ensuring that what you are doing is legal. Do not assume that just because we believe a book is in the public domain for users in the United States, that the work is also in the public domain for users in other countries. Whether a book is still in copyright varies from country to country, and we can't offer guidance on whether any specific use of any specific book is allowed. Please do not assume that a book's appearance in Google Book Search means it can be used in any manner anywhere in the world. Copyright infringement liability can be quite severe.

About Google Book Search

Google's mission is to organize the world's information and to make it universally accessible and useful. Google Book Search helps readers discover the world's books while helping authors and publishers reach new audiences. You can search through the full text of this book on the web at `http://books.google.com/`

B 3 9015 00212 249 0
University of Michigan – BUHR

Digitized by Google



Digitized by Google

610.5
P3
S7
LFt

Digitized by Google

Digitized by Google

TRANSACTIONS

OF THE

PATHOLOGICAL SOCIETY OF LONDON.

92785

VOLUME THE FIFTIETH.

COMPRISING THE REPORT OF THE PROCEEDINGS FOR THE SESSION 1898-99.

LONDON:
SMITH, ELDER & CO., 15, WATERLOO PLACE.
1899.

Digitized by Google

THE present publication, being the Fiftieth Volume of Transactions, constitutes the Fifty-third published Annual Report of the Pathological Society's Proceedings.

The COUNCIL think it right to repeat that the exhibitors are alone responsible for the descriptions given of the Specimens exhibited by them, the only change made in the Reports furnished by the authors being such verbal alterations as were absolutely necessary.

20, HANOVER SQUARE, W.;
November, 1899.

Digitized by Google

TABLE OF CONTENTS

OF VOLUME L.

	PAGE
List of Presidents of the Society	iv
List of Officers and Members for 1898–99	v
Annual Report of the Council for 1898–99	xxix
List of Specimens Exhibited during the Session 1898–99	xxxiii
List of Specimens Reported on by the Committee on Morbid Growths	xlii
List of Plates	xliii
List of Figures in the Text	xlv
Diseases, etc., of the Nervous System	1
Diseases, etc., of the Organs of Respiration	30
Diseases, etc., of the Organs of Circulation	41
Diseases, etc., of the Organs of Digestion	61
Diseases, etc., of the Genito-urinary Organs	179
Diseases, etc., of Bone and of the Organs of Locomotion	185
Diseases, etc., of the Ductless Glands	202
Diseases, etc., of the Skin	220
Morbid Growths	223
Bacteriology and Pathological Chemistry	256
Miscellaneous Communications	319
Discussion on Pseudo-Tuberculosis	331
Index	365

Digitized by Google

Presidents of the Society.

ELECTED	
1846	CHARLES J. B. WILLIAMS, M.D., F.R.S.
1848	CHARLES ASTON KEY.
1850	PETER MERE LATHAM, M.D.
1852	CÆSAR H. HAWKINS, F.R.S.
1853	BENJAMIN GUY BABINGTON, M.D., F.R.S.
1855	JAMES MONCRIEFF ARNOTT, F.R.S.
1857	Sir THOMAS WATSON, Bart., M.D., F.R.S.
1859	Sir WILLIAM FERGUSSON, Bart., F.R.S.
1861	JAMES COPLAND, M.D., F.R.S.
1863	Sir PRESCOTT G. HEWETT, Bart., F.R.S.
1865	THOMAS BEVILL PEACOCK, M.D.
1867	Sir JOHN SIMON, K.C.B., D.C.L., F.R.S.
1869	Sir RICHARD QUAIN, Bart., M.D., LL.D., F.R.S.
1871	JOHN HILTON, F.R.S.
1873	Sir WILLIAM JENNER, Bart., M.D., G.C.B., D.C.L., F.R.S.
1875	GEORGE D. POLLOCK.
1877	CHARLES MURCHISON, M.D., LL.D., F.R.S.
1879	JONATHAN HUTCHINSON, F.R.S.
1881	Sir SAMUEL WILKS, Bart., M.D., F.R.S.
1883	JOHN WHITAKER HULKE, F.R.S.
1885	JOHN SYER BRISTOWE, M.D., F.R.S.
1887	Sir JAMES PAGET, Bart.. D.C.L., LL.D., F.R.S.
1889	WILLIAM HOWSHIP DICKINSON, M.D.
1891	Sir GEORGE MURRAY HUMPHRY, M.D., LL.D., F.R.S.
1893	FREDERICK WILLIAM PAVY, M.D., LL.D., F.R.S.
1895	HENRY TRENTHAM BUTLIN, D.C.L.
1897	JOSEPH FRANK PAYNE, M.D.
1899	WILLIAM WATSON CHEYNE, F.R.S.

Digitized by Google

OFFICERS AND COUNCIL

OF THE

Pathological Society of London,

ELECTED AT

THE GENERAL MEETING, MAY 16th, 1899,

FOR THE SESSION 1899–1900.

President.

WILLIAM WATSON CHEYNE, F.R.S.

Vice-Presidents.

F. W. MOTT, M.D., F.R.S.
G. NEWTON PITT, M.D.
F. CHARLEWOOD TURNER, M.D.
GERMAN SIMS WOODHEAD, M.D.
ANTHONY A. BOWLBY.
A. PEARCE GOULD, M.S.
G. H. MAKINS.
CHARTERS J. SYMONDS, M.S.

Treasurer.

SIDNEY COUPLAND, M.D.

Council.

JOHN ABERCROMBIE, M.D.
J. ROSE BRADFORD, M.D., F.R.S.
SHERIDAN DELÉPINE, M.B.
JAMES GALLOWAY, M.D.
ARCHIBALD E. GARROD, M.D.
HERBERT P. HAWKINS, M.D.
R. G. HEBB, M.D.
WILLIAM HUNTER, M.D.
CYRIL OGLE, M.B.
J. W. WASHBOURN, M.D.
WILLIAM H. BATTLE.
CECIL F. BEADLES.
F. G. HOPKINS, M.B.
H. A. LEDIARD, M.D.
JOHN R. LUNN.
JOHN McFADYEAN, M.B.
D'ARCY POWER, M.B.
J. H. TARGETT, M.S.
FREDERICK C. WALLIS, M.B.
EDGAR WILLETT, M.B.

Honorary Secretaries

HUMPHRY D. ROLLESTON, M.A., M.D.
CHARLES ALFRED BALLANCE, M.S.

Trustees.

SIR SAMUEL WILKS, BART., M.D., F.R.S.
JOSEPH FRANK PAYNE, M.D.
HENRY MORRIS, M.A.

Digitized by Google

Members of the Morbid Growths Committee.

RICHARD G. HEBB, M.D.
NORMAN MOORE, M.D.
HUMPHRY D. ROLLESTON, M.D.
HOWARD HENRY TOOTH, M.D.
GERMAN SIMS WOODHEAD, M.D.

ANTHONY A. BOWLBY.
D'ARCY POWER, M.B.
SAMUEL G. SHATTOCK.
W. G. SPENCER, M.S.
JAMES HENRY TARGETT, M.S.

Digitized by Google

*** *Members are requested to inform the Senior Secretary of any corrections which may be necessary.*

LIST OF MEMBERS OF THE SOCIETY.

Honorary Members.

BOUCHARD, C., M.D., Professor of General Pathology, Paris.
CHAUVEAU, A., M.D., Professor of Physiology at the Medical School of Lyons.
KOCH, R., M.D., Director of Institute for Infective Diseases, Berlin.
The Right Honourable Lord LISTER, P.R.S., F.R.C.S., 12, Park crescent, Portland place, W.
METCHNIKOFF, E., M.D., Directeur de l'Institut Pasteur, Paris.
RINDFLEISCH, EDOUARD, M.D., Professor of Pathological Anatomy in the University of Bonn.
SIMON, SIR JOHN, K.C.B., D.C.L., LL.D., F.R.S., 40, Kensington square, W.
VIRCHOW, RUDOLF, M.D., Professor of Pathological Anatomy in the University of Berlin.
WELCH, W. H., M.D., Professor of Pathology, Johns Hopkins University.
ZIEGLER, E., M.D. Professor of Pathological Anatomy, Freiburg.

EXPLANATION OF ABBREVIATIONS.

O.M.—Original Member.
P.—President.
T.—Treasurer.
V.-P.—Vice-President.
S.—Secretary.
C.—Member of Council.
M.G.C.—Member of the Morbid Growths Committee.

The surnames of Members who have compounded for their subscriptions are printed in this type (TYPE). The surnames of Members who have paid the Composition Fee for the 'Transactions' are printed in this type (Type).

Digitized by Google

GENERAL LIST OF MEMBERS.

Elected

1891 ABBOTT, FRANCIS CHARLES, M.S., 44, Welbeck street, W.
1879 **ABERCROMBIE**, JOHN, M.D., 23, Upper Wimpole street, W. (C. 1897—.)
1885 ABRAHAM, PHINEAS S., M.A., M.D., 2, Henrietta street, W.
1896 ABRAHAMS, BERTRAM LOUIS, B.Sc., M.B., 14, Welbeck street, W.
1858 ACLAND, Sir HENRY WENTWORTH, Bart., K.C.B., M.D., F.R.S., Broad street, Oxford.
1883 ACLAND, THEODORE DYKE, M.D., 74, Brook street, W. (C. 1892-4.)
1891 ADAMI, J. GEORGE, M.A., M.D., Montreal, Canada.
1890 ADAMS, JAMES, M.D., 4, Chiswick place, Eastbourne.
O.M. **ADAMS**, WILLIAM, 7, Loudoun road, St. John's Wood, N.W. (C. 1851-4. V.-P. 1867-9.)
1848 **AIKIN**, CHARLES A., 12, Ladbroke terrace, W. (C. 1864-6.)
1872 AIKIN, CHARLES EDMUND, 12, Ladbroke terrace, W.
1897 ALCOCK, S. K., M.D., Portland House, Burslem.
1882 **ALLCHIN**, WILLIAM HENRY, M.D., 5, Chandos street, W.
1884 ANDERSON, ALEXANDER RICHARD, 5, East Circus street, Nottingham.
1871 ANDERSON, WILLIAM, 5, Cavendish square, W. (C. 1888-90.)
1897 ANDREWES, F. W., M.D., Highwood, Hampstead lane, Highgate, N.
1883 ASHBY, HENRY, M.D., 13, St. John street, Manchester.

1863 BAGSHAWE, FREDERICK, M.A., M.D., 35, Warrior square, St. Leonard's-on-Sea.
1856 **Balding**, DANIEL BARLEY, Royston, Herts.
1881 BALLANCE, CHARLES A., M.S., 106, Harley street, W. (HON. SECRETARY). (C. 1890-2. S. 1899—.)
1875 BARKER, ARTHUR E. J., 87, Harley street, W. (C. 1884-6. V.P. 1896-7.)
1885 BARLING, GILBERT, M.B., 85, Edmund street, Birmingham. (C. 1894-7.)
1874 **BARLOW**, THOMAS, M.D., B.S., 10, Wimpole street, W. (C. 1879-81. V.-P. 1894-6.)
1899 BARRATT, JOHN OGLETHORPE WAKELIN, M.D., West Riding Asylum, Wakefield, Yorks.
1877 BARROW, A. BOYCE, 37, Wimpole street, W.
1881 BARRS, ALFRED GEORGE, M.D., 22, Park place, Leeds.
1853 **BARWELL**, RICHARD, 55, Wimpole street, W. (C. 1862-4. V.-P. 1889-90.)
1861 **BASTIAN**, H. CHARLTON, M.A., M.D., F.R.S., 8A, Manchester square, W. (C. 1869-71. V.-P. 1885-7.)
1877 BATEMAN, ARTHUR W., B.A., Tenterfield, New South Wales.

Digitized by Google

Elected

1895 BATTEN, FREDERICK E., M.D., 124, Harley street, W.

1876 **BATTESON**, JOHN, Carnforth, Chiswick lane, W.

1882 BATTLE, WILLIAM HENRY, 49, Harley street, W. (C. 1898—.)

1870 BÄUMLER, CHRISTIAN G. H., M.D., University of Erlangen.

1874 BEACH, FLETCHER, M.B., 64, Welbeck street, W., and Winchester House, Kingston Hill, Surrey.

1892 BEADLES, CECIL F., Colney Hatch Lunatic Asylum, N. (C. 1898—.)

1879 BEALE, EDWIN CLIFFORD, M.B., 23, Upper Berkeley street, W.

1852 **BEALE**, LIONEL S., M.B., F.R.S., 61, Grosvenor street, W. (C. 1858-9. V.-P. 1874-5.)

1856 BEALEY, ADAM, M.D., M.A., Felsham Lodge, Hollington park, St. Leonard's-on-Sea.

1897 BEDDARD, A. P., M.D., 44, Seymour street, W.

1865 BEEBY, WALTER, M.D., Bromley, Kent.

1880 **BEEVOR**, CHARLES EDWARD, M.D., 33, Harley street, W. (C. 1888-90.)

1886 BENNETT, FREDERICK JOSEPH, 17, George street, Hanover square, W.

1877 BENNETT, WILLIAM HENRY, 1, Chesterfield street, W. (C. 1891-3.)

1889 BENTLEY, ARTHUR, J. M., M.D., Mena House, Pyramids, Cairo, Egypt.

1878 BERNARD, FRANCIS R., M.D., Prawls, Stone, near Tenterden, Kent.

1882 BERRIDGE, WILLIAM ALFRED, Redhill, Surrey.

1886 BERRY, JAMES, M.B., 21, Wimpole street, W. (C. 1895-7.)

1891 BEVILLE, FREDERICK WELLS, 19, New Cavendish street, W.

1856 **Bickersteth**, EDWARD R., 2, Rodney street, Liverpool.

1882 BINDLEY, PHILIP HENRY, M.B., Branksome road, St. Leonard's-on-Sea.

1850 **BIRKETT**, EDMUND LLOYD, M.D., Westbourne Rectory, Emsworth, Hampshire. (C. 1856-7.)

1865 BISSHOPP, JAMES, Mount Pleasant, Tunbridge Wells.

1889 BLACK, ROBERT, M.D., 14, Pavilion Parade, Brighton.

1863 BLANCHET, JEAN B., M.D., M.S., Montreal, Quebec, Canada.

1879 BOILEAU, J. P. H., M.D., Brigade-Surgeon, Army.

1876 BOND, THOMAS, M.B., 7, The Sanctuary, Westminster, S.W.

1869 BOURNE, WALTER, M.D. (Travelling).

1861 BOWER, RICHARD NORRIS (Travelling).

1881 BOWLBY, ANTHONY A., 24, Manchester square, W. (M.G.C. 1884—. C. 1886-8, 1895-7. S. 1893-4. V.-P. 1898—.)

1895 BOX, CHARLES R., M.D., St. Thomas's Hospital, S.E.

1892 BOYCE, RUBERT WILLIAM, M.B., University College, Liverpool.

1882 BOYD, STANLEY, M.B., 134, Harley street, W. (C. 1893-6. V.-P. 1897-9.)

1889 BRADFORD, JOHN ROSE, M.D., F.R.S., 8, Manchester square, W. (C. 1897—.)

1880 BRAMWELL, BYROM, M.D., 23, Drumsheugh gardens West, Edinburgh.

1889 BREDIN, J. NOBLE, Linden Lodge, Potton, Beds.

1877 BRIDGES, ROBERT, M.B., M.A., Manor House, Yattendon, Berks.

1867 **Bridgewater**, THOMAS, LL.D. Glas., M.B. Lond., Harrow-on-the-Hill, Middlesex.

Digitized by Google

Elected

1873 Briggs, Jacob Myers, M.D., Coeymans, New York, U.S.A.
1868 Bright, George Charles, M.D., Cannes, Alpes Maritimes, France.
1857 Briscoe, John, 5, Broad street, Oxford.
1885 Briscoe, John F., Westbrooke House, Alton, Hants.
1860 **Broadbent**, Sir William Henry, Bart., M.D., 84, Brook street, W. (C. 1871-3. V.P. 1882-4.)
1886 Brockatt, Andrew Alexander, M.D., Hazeldean, Malvern.
1852 **Brodhurst**, Bernard E., 21, Portland place, W. (C. 1862-4.)
1884 Brodie, Charles Gordon, Fernhill, Wootton Bridge, Isle of Wight.
1865 **Brown**, Augustus, M.D., Felsberg, Wilton road, Shanklin, I.W.
1871 Brown, Frederick Gordon, 17, Finsbury circus, E.C.
1866 **Browne**, Lennox, 15, Mansfield street, W.
1877 Bruce, J. Mitchell, M.D., 23, Harley street, W.
1890 Brunton, T. Lauder, M.D., D.Sc., LL.D., F.R.S., 10, Stratford place, W.
1898 Bryant, John Henry, M.D., 8, St. Thomas's street, London bridge, S.E.
1855 **Bryant**, Thomas, M.Ch., 65, Grosvenor street, W. (C. 1863-6. V.-P. 1877-9.)
1894 Buchanan, George Seaton, M.D., 9, Hammersmith terrace, W.
1890 Buckland, Francis O., M.A., M.B., C.M., 10, Egerton place, S.W.
1891 Burghard, Frederic François, M.D., M.S., 86, Harley street, W.
1880 Burton, Samuel Herbert, M.B., 50, St. Giles' street, Norwich.
1872 **Butlin**, Henry Trentham, D.C.L., 82, Harley street, W. (M.G.C. 1875-86. C. 1876-8, 1887-9. S. 1884-6. V.-P. 1891-2. P. 1895-7.)
1883 **Buxton**, Dudley W., M.D., 82, Mortimer street, W.
1856 **Buzzard**, Thomas, M.D., 74, Grosvenor street, W. (C. 1869-70. V.-P. 1881-3.)

1899 Caddy, Arnold, 2/2, Harington street, Calcutta.
1885 Cahill, John, M.D., 12, Seville street, Lowndes square, S.W.
1893 Caley, Henry Albert, M.D., 24, Upper Berkeley street, W.
1897 Calvert, James, M.D., The Warden's House, St. Bartholomew's Hospital, E.C.
1892 Campbell, Henry Johnstone, M.D., 36, Manningham lane, Bradford.
1891 Carless, Albert, M.S., 10, Welbeck street, W.
1891 Carr, John Walter, M.D., 19, Cavendish place, W.
1876 Carter, Robert Brudenell, 31, Harley street, W., and Kenilworth, Clapham common, S.W.
1897 Carwardine, T., M.S., 16, Victoria square, Clifton, Bristol.
1877 Casson, John Hornsey, H.B.M. Legation, Teheran, Persia.
1899 Cautley, Edmund, M.D., 15, Upper Brook street, W.
1868 **Cavafy**, John, M.D., 10, Fourth Avenue, Hove, Sussex. (C. 1881-3.)
1864 Cay, Charles Vidler, Deputy Surgeon General, 25, Newton place, Glasgow.

Digitized by Google

Elected

1863 CAYLEY, WILLIAM, M.D., 27, Wimpole street, W. (M.G.C. 1869-84. C. 1870-1, 1875-8. S. 1872-4. V.-P. 1884-6. T. 1888-93.)

1869 CHAFFERS, EDWARD, Keighley, Yorkshire.

1884 CHAFFEY, WAYLAND CHARLES, M.D., 13, Montpellier road, Brighton.

1891 CHAPLIN, ARNOLD, M.D., 41, Finsbury square, E.C.

1884 CHAVASSE, THOMAS FREDERICK, M.D., C.M., 22, Temple row, Birmingham.

1879 CHEYNE, WILLIAM WATSON, M.B., C.M., F.R.S. (PRESIDENT), 75, Harley street, W. C. 1885-7. (M.G.C. 1890-6. V.-P. 1892-3. P. 1899—.)

1873 CHISHOLM, EDWIN, M.D., Abergeldie, Ashfield, near Sydney, New South Wales [care of Messrs. Dawson, 121, Cannon street, E.C.].

1865 **CHURCH**, WILLIAM SELBY, P.R.C.P., 130, Harley street, W. (M.G.C. 1869-74. C. 1871-3. V.-P. 1894-6.)

1868 **CHURCHILL**, FREDERICK, M.D., 4, Cranley gardens, Queen's gate, S.W.

1898 CHURTON, THOMAS, M.D., 35, Park square, Leeds.

1861 **CLAPTON**, EDWARD, M.D., Towercroft, 41, Eltham road, Lee, S.E.

1872 CLARK, ANDREW, 71, Harley street, W.

1886 CLARK, FRANCIS WILLIAM, M.B., Victoria, Hong Kong.

1891 CLARKE, J. JACKSON, M.B., 9, Old Cavendish street, W.

1885 CLARKE, JOHN MICHELL, M.D., 28, Pembroke road, Clifton, Bristol.

1881 CLARKE, W. BRUCE, M.B., 51, Harley street, W. (C. 1892-4.)

1875 **CLUTTON**, HENRY HUGH, M.A., 2, Portland place, W. (C. 1884-6. M.G.C. 1889-94. V.-P. 1892-3.)

1865 **Coates**, CHARLES, M.D., 10, Circus, Bath.

1856 COCKLE, JOHN, M.A., M.D., The Lodge, West Molesey.

1892 COLE, ROBERT HENRY, M.D., 53, Upper Berkeley street, W.

1886 COLLIER, WILLIAM, M.D., High street, Oxford.

1888 COLLINS, WILLIAM JOB, M.D., M.S., 1, Albert terrace, Regent's park, N.W.

1878 COLLYNS, R. T. POOLE, 20, Lingfield road, Wimbledon.

1888 COLMAN, WALTER STACY, M.D., 22, Wimpole street, W.

1882 COLQUHOUN, DANIEL, M.D., Dunedin, New Zealand.

1896 CONNELL, W. T., M.D., Kingston, Canada.

1891 COOK, HERBERT G. GRAHAM, M.D., 22, Newport road, Cardiff.

1858 COOKE, R. T. E. BARRINGTON, 15, St. Nicholas cliff, Scarborough, Yorkshire.

1866 COOMBS, ROWLAND HILL, M.D., Mill street, Bedford.

1892 COOPER, C. DUDLEY,

1899 CORNER, HARRY, M.D., Brook House, Southgate, N.

1876 COTTLE, WYNDHAM, M.D., 39, Hertford street, W.

1861 **COUPER**, JOHN, 80, Grosvenor street, W. (C. 1870-2.)

Digitized by Google

Elected

1878 COUPLAND, SIDNEY, M.D. (TREASURER), 16, Queen Anne street, W. (M.G.C. 1882-6. C. 1878-81, 1889-91. S. 1886-8. V.-P. 1892-3. T. 1894—.)

1897 CRAWFURD, R. H. P., M.D., 71, Harley street, W.

1884 CRICHTON, GEORGE, M.D., 96, Earl's Court road, W.

1878 CRIPPS, WILLIAM HARRISON, 2, Stratford place, W. (C. 1883-5. V.-P. 1893-4.)

1877 **CROCKER**, HENRY RADCLIFFE, M.D., 121, Harley street, W. (C. 1887-9. V.-P. 1897-9.)

1856 CROFT, JOHN, 6, Mansfield street, W. (C. 1870-2. V.-P. 1882-4.)

1886 CROOKSHANK, EDGAR, M.B., Saint Hill, East Grinstead, Sussex. (C. 1890-3.)

1875 CROSS, FRANCIS RICHARDSON, 5, The Mall, Clifton, Bristol.

1890 CROWLE, THOMAS H. RICKARD, 56, Harley street, Cavendish square, W.

1889 CUFF, ROBERT, M.B., 1, The Crescent, Scarborough.

1885 CULLINGWORTH, CHARLES JAMES, M.D., 14, Manchester square, W.

1871 CUMBERBATCH, A. ELKIN, 80, Portland place, W.

1873 CURNOW, JOHN, M.D., 9, Wimpole street, Cavendish square, W. (C. 1882-4.)

1893 CURTIS, HENRY JONES, M.D., 60, Gower street, W.C.

1884 DAKIN, W. RADFORD, M.D., B.S., 18, Grosvenor street, Grosvenor square, W.

1883 DALTON, NORMAN, M.D., 4, Mansfield street, W.

1873 DAVIDSON, ALEXANDER, M.D., 2, Gambier terrace, Liverpool.

1869 **DAVIES-COLLEY**, J. NEVILLE C., M.C., 36, Harley street, W. (C. 1880-2. V.-P. 1890-1.)

1883 DAVIS, EDWIN HARRY, West Hartlepool.

1859 **Davis**, FRANCIS WILLIAM, R.N.

1879 DAVY, HENRY, M.D., 29, Southernhay, Exeter.

1894 DAWSON, BERTRAND, M.D., 110, Harley street, W.

1899 DEAN, GEORGE, M.D., The Jenner Institute of Preventive Medicine, Grosvenor road, Chelsea Bridge, S.W.

1889 DEAN, HENRY PERCY, M.B., M.S., 69, Harley street, W.

1887 DELÉPINE, SHERIDAN, M.B., C.M., Owens College, Manchester. (C. 1899—.)

1880 DENT, CLINTON T., 61, Brook street, W.

1871 DICKINSON, EDWARD HARRIMAN, M.A., M.D., 51A, Rodney street, Liverpool.

1858 **DICKINSON**, WILLIAM HOWSHIP, M.D., 9, Chesterfield street, W. (C. 1866-8. S. 1869-71. V.-P. 1872-4. P. 1889-90.)

1890 **DICKINSON**, WILLIAM LEE, M.D., 9, Chesterfield street, W.

1872 DIVER, EBENEZER, M.D., 30, Devonshire street, W.

1872 DORAN, ALBAN HENRY GRIFFITHS, 9, Granville place, W. (C. 1882-4. V.-P. 1894-6.)

Digitized by Google

Elected

1866 DOUGLAS-POWELL, Sir RICHARD, Bart., M.D., 62, Wimpole street, W. (C. 1873-5, 1881-3. S. 1877-9. V.-P. 1887-8.)

1893 DOWSON, WALTER, M.D., 46, Alleyn road, West Dulwich.

1877 DRAKE-BROCKMAN, E. F., 14, Welbeck street, W.

1880 DRESCHFELD, JULIUS, M.D., 3, St. Peter's square Manchester. (C. 1896-9.)

1896 DREW, DOUGLAS, M.B., 58, Brook street, W.

1879 DREWITT, F. G. DAWTREY, M.D., 2, Manchester square, W. (C. 1890-2.)

1893 DRYSDALE, JOHN HANNAH, M.D., 25, Welbeck street, W.

1865 **DUCKWORTH**, Sir DYCE, M.D., LL.D., 11, Grafton street, Bond street, W. (C. 1877.)

1847 **DUDGEON**, ROBERT E., M.D., 63, Upper Berkeley street, W.

1871 DUKES, CLEMENT, M.D., B.S., Sunnyside, Rugby.

1877 DUNBAR, J. J. MACWHIRTER, M.D., Hedingham House, Clapham common, S.W.

1889 DUNCAN, JOHN, M.D., St. Petersburg.

1884 DUNN, LOUIS ALBERT, M.B., M.S., The College, Guy's Hospital, S.E.

1879 DURHAM, FREDERIC, M.B., 82, Brook street, W.

1893 ECCLES, WILLIAM MCADAM, M.S., 124, Harley street, W.

1892 EDDOWES, ALFRED, M.D., 28, Wimpole street, W.

1880 **EDMUNDS**, WALTER, M.C., 75, Lambeth Palace road, S.E. (C. 1892-4.)

1882 EDWARDS, F. SWINFORD, 55, Harley street, W.

1889 ELAM, WILLIAM HENRY, New Barnet, Herts.

1883 ELDER, GEORGE, M.D., 17, Regent street, Nottingham.

1867 ELLIS, JAMES, M.D., Coburg street, Fratton, Portsmouth, and California.

1863 ENGELMANN, GEORGE JULIUS, M.D., A.M., 336, Beacon street, Boston, Mass., U.S.A.

1875 EVANS, JULIAN AUGUSTUS, A.M., M.D., 123, Finborough road, Redcliffe-square, S.W.

1894 EVANS, WILLMOTT H., M.D., 13, Taviton street, Gordon square, W.C.

1872 EVE, FREDERIC S., 125, Harley street, W. (M.G.C. 1884-94. C. 1885-7. V.-P. 1895-7.)

1876 EWART, JAMES COSSAR, M.B., C.M., F.R.S., School of Medicine, Edinburgh.

1881 EWART, Sir JOSEPH, M.D., Bewcastle, Dyke road, Brighton.

1877 **EWART**, WILLIAM, M.D., 33, Curzon street, W. (C. 1889-91.)

1859 **Ewens**, JOHN, 17, Redland Grove, Bristol.

1887 EYLES, CHARLES HENRY, Gold Coast Colony.

1897 EYRE, J. W. H., M.D., 14, Trinity square, S.E.

1889 FAIRBANK, FREDERICK ROYSTON, M.D., Hillside, Westcott, Dorking.

1894 FAWCETT, JOHN, M.D., 24, St. Thomas's street, S.E.

Digitized by Google

Elected

1872 FENN, EDWARD L., M.D., Grey Friars, Colchester.
1883 FENWICK, E. HURRY, 14, Savile row, W. (C. 1894-7.)
1872 FENWICK, JOHN C. J., M.D., Long Framlington, Morpeth.
1863 **FENWICK** SAMUEL, M.D., 29, Harley street, W.
1892 FENWICK, W. SOLTAU, M.D., 8, Devonshire street, W.
1885 FÉRÉ, CHARLES, M.D., Médecin de Bicêtre; Boulevard St. Michel 37, Paris.
1897 FISHER, THEODORE, M.D., 25, Pembroke road, Clifton, Bristol.
1882 FLEMING, GEORGE, C.B., LL.D., Higher Leigh, Combe Martin, North Devon.
1893 FLETCHER, H. MORLEY, M.A., M.D., B.C., 98, Harley street, W.
1872 FORBES, DANIEL MACKAY, 32, Oakfield road, West Croydon.
1866 **Foster**, Sir BALTHAZAR WALTER, M.D., M.P., 80, Grosvenor road, Westminster.
1872 FOTHERBY, HENRY I., M.D., Woodthorpe Cote, Reigate.
1891 FOULERTON, ALEXANDER GRANT RUSSELL, Dunsdale, Mulgrave road, Sutton.
1880 FOWLER, JAMES KINGSTON, M.A., M.D., 35, Clarges street, W. (C. 1887-8.)
1878 FOX, THOMAS COLCOTT, B.A., M.B., 14, Harley street, W. (C. 1892-4.)
1858 FRANCIS, CHARLES RICHARD, M.B., 15, Spencer park, New Wandsworth, S.W.
1896 FREYBERGER, LUDWIG, M.D., 41, Regent's park road, N.W.
1891 FRIPP, ALFRED DOWNING, M.S., 19, Portland place, W.
1864 FRODSHAM, JOHN MILL, M.D., Streatham, S.W.
1894 FURNIVALL, PERCY, 39, Welbeck street, W.
1893 FYFFE, WILLIAM KINGTON, M.B., 1, Boullcott street, Wellington, New Zealand.

1880 GABBETT, HENRY SINGER, M.D., 8, Chiswick place, Eastbourne.
1858 **Gairdner**, Sir WILLIAM TENNANT, K.C.B., M.D., LL.D.Edin., F.R.S., 225, St. Vincent street, Glasgow. (V.-P. 1891-2.)
1890 GALLOWAY, JAMES, M.A., M.D., 54, Harley street, W. (C. 1899—.)
1870 GALTON, JOHN H., M.D., Sylvan road, Upper Norwood, S.E.
1846 **GARROD**, Sir ALFRED BARING, M.D., F.R.S., 10, Harley street, W. (C. 1851. V.-P. 1863-5.)
1892 GARROD, ARCHIBALD EDWARD, M.D., 9, Chandos street, Cavendish square, W. (C. 1898—.)
1879 GARSTANG, THOMAS WALTER HARROPP, Headingley House, Knutsford, Cheshire.
1872 GARTON, WILLIAM, M.D., Inglewood, Aughton, near Ormskirk, Lancashire.
1880 GIBBES, HENEAGE, M.B., University of Michigan, Ann Arbor, Michigan, U.S.A.
1853 **GIBBON**, SEPTIMUS, M.D., 39, Oxford terrace, Hyde park, W.
1878 GIBBONS, R. A., M.D., 29, Cadogan place, S.W.

Digitized by Google

Elected

1893 Gibbs, Charles, 115, Harley street, W.
1872 Gilbart-Smith, Thomas, M.D., 68, Harley street, W.
1876 Gill, John, M.D., 30, West mall, Clifton, Bristol.
1881 Glynn, Thomas Robinson, M.D., 62, Rodney street, Liverpool.
1898 Goadby, Kenneth Weldon, 6, Holly road, Cambridge park, Leytonstone, Essex.
1873 Godlee, Rickman John, M.B., M.S., 19, Wimpole street, W. (M.G.C. 1875-84. C. 1877-80, 1891-2. S. 1887-9. V.-P. 1893-4.)
1878 Golding-Bird, Cuthbert H., M.B., B.S., 12, Queen Anne street, W. (C. 1885-7. V.-P. 1894-6.)
1890 Goodall, E. Wilberforce, M.D., The Eastern Hospital, Homerton, N.E.
1871 Goodhart, James Frederic, M.D., 25, Portland place, W. (M.G.C. 1874-86. C. 1876-8, 1886-8. S. 1883-5. V.-P. 1892-3.)
1894 Gossage, Alfred Milne, M.B., B.Ch., 54, Upper Berkeley street, W.
1875 Gould, Alfred Pearce, M.S., 10, Queen Anne street, W. (C. 1883-5. V.-P. 1898—.)
1870 Gowers, Sir William, M.D., F.R.S., 50, Queen Anne street, W. (C. 1878-9. V.P. 1896-7.)
1888 Grant, J. Dundas, M.A., M.D., C.M., 8, Upper Wimpole street, W.
1867 Green, T. Henry, M.D., 74, Wimpole street, W. (M.G.C. 1869-83. C. 1871-3, 1878-9. S. 1875-6. V.-P. 1886-8.)
1895 Green, Charles David, M.D., The Ferns, South street, Romford.
1873 Greenfield, William Smith, M.D., B.S., 7, Heriot row, Edinburgh. (M.G.C. 1874-81. C. 1877-80. V.-P. 1893-4.)
1886 Greves, Edwin Hyla, M.D., Rodney House, Suffolk road, Bournemouth.
1897 Griffith, J., 16, Harley street, W.
1887 Griffiths, Joseph, M.D., C.M., 63, Trumpington street, Cambridge.
1876 Griffiths, Thomas D., M.D., Hearne Lodge, Swansea.

1887 Habershon, Samuel Herbert, M.D., 88, Harley street, W.
1851 HACON, E. Dennis, 269, Mare street, Hackney, N.E. (C. 1872.)
1892 Hadley, Wilfred James, M.D., 58, Harley street, W.
1882 Haig, A., M.D., 7, Brook street, W.
1899 Hall, A. J., M.B., 342, Glossop road, Sheffield.
1894 Hallidie, Andrew Hallidie Smith, M.B., 50, Noord street, Johannesburg.
1886 Hamilton, David James, M.B., 41, Queen's road, Aberdeen.
1890 Handfield-Jones, Montagu, M.D., 35, Cavendish square, W.
1886 Handford, Henry, M.D., 6, Regent street, Nottingham.
1891 Hankin, E. H., Agra, India.
1882 Harbinson, Alexander, M.D., County Lunatic Asylum, Lancaster.
1893 Harley, Vaughan, M.D., 25, Harley street, W.
1879 Harris, Vincent Dormer, M.D., 22, Queen Anne street, W.

Digitized by Google

Elected

1891 HASLAM, WILLIAM F., 54, Newhall street, Birmingham.

1870 HAWARD, JOHN WARRINGTON, 57, Green street, Grosvenor square, W. (C. 1879-81. V.-P. 1890-1.)

1899 HAWKES, CLAUDE SOMERVILLE, Rockhampton, Queensland, Australia.

1886 HAWKINS, FRANCIS HENRY, M.B., 73, London street, Reading.

1890 HAWKINS, HERBERT PENNELL, M.D., 56, Portland place, W. (C. 1898—.)

1856 **HEATH**, CHRISTOPHER, 36, Cavendish square, W. (C. 1866-7. V.-P. 1879-81.)

1892 HEATON, GEORGE, M.B., B.Ch., 33, Temple row, Birmingham.

1881 HEBB, RICHARD G., M.A., M.D., 9, Suffolk street, S.W. (M.G.C. 1891—. C. 1891-3. 1898—. S. 1896-7.)

1884 HEBBERT, CHARLES ALFRED, care of C. Baylor, 7, Water street, Boston, U.S.A.

1878 HELLIER, JOHN B., M.D., 37, Park square, Leeds.

1879 HENDERSON, GEORGE COURTENAY, M.D., Kingston, Jamaica, West Indies.

1869 HENSLEY, PHILIP J., M.D., 4, Henrietta street, W.

1884 HERRINGHAM, WILMOT PARKER, M.D., 13, Upper Wimpole street, W. (C. 1894-7.)

1892 HEWLETT, RICHARD TANNER, M.D., Jenner Institute of Preventive Medicine, Chelsea gardens, Grosvenor road, S.W.

1897 HICHENS, P. S., M.B., Bch., Hospital for Consumption, Brompton, W.

1880 HOBSON, JOHN MORRISON, M.D., Glendalough, Morland road, Croydon.

1854 **HOLMES**, TIMOTHY, 6, Sussex place, Hyde park, W. (C. 1862-3 S. 1864-7. C. 1868. V.-P. 1869-71.)

O.M. HOLTHOUSE, CARSTEN, Helidon House, Shoeburyness, Essex. (C. 1852-4. V.-P. 1874-5.)

1878 HOOD, DONALD WILLIAM CHARLES, M.D., 43, Green street, Park lane, W.

1864 HOOD, WHARTON P., M.D., 11, Seymour street, W.

1895 HOPKINS, F. G., M.B., New Museums, Cambridge. (C. 1899—.)

1897 HORNE, W. J., M.B., 27, New Cavendish street, Portland place, W.

1879 HORROCKS, PETER, M.D., 45, Brook street, W.

1883 HORSLEY, VICTOR, M.B., B.S., F.R.S., 25, Cavendish square, W. (C. 1888-9.)

1896 HORTON-SMITH, PERCIVAL, M.D., B.C., 15, Upper Brook street, W.

1880 **HOVELL**, T. MARK, 105, Harley street, W.

1893 HOWARD, ROBERT JAMES BLISS, M.D., 31, Queen Anne street, W.

1875 HOWSE, HENRY GREENWAY, M.S., 59, Brook street, W. (M.G.C. 1876-84. C. 1878-81.)

1856 **HUDSON**, JOHN, M.D., 11, Cork street, W.

1874 HUMPHREYS, HENRY, M.D., St. Mary Church road, Torquay.

1897 HUNT, E. L., 18, Dorset square, W.

1897 HUNT, G. B., M.D., 47, Albemarle crescent, Scarborough.

1888 HUNTER, WILLIAM, M.D., 103, Harley street, W. (C. 1897—.)

1852 **HUTCHINSON**, JONATHAN, F.R.S., 15, Cavendish square, W. (C. 1856-9. V.-P. 1872-3, 1881-3. P. 1879-80.)

Digitized by Google

Elected

1882 HUTCHINSON, JONATHAN, jun., 15, Cavendish square, W. (C. 1889-91.)

1884 HUTTON, HENRY RICHMOND, M.B., 8A, St. John street, Manchester.

1880 INGRAM, ERNEST FORTESCUE, Newcastle, Natal, S. Africa.

1886 JACKSON, ARTHUR MOLYNEUX, M.D., Kent County Asylum, Barming Heath, Maidstone.

1865 JACKSON, J. HUGHLINGS, M.D., F.R.S., 3, Manchester square, W. (C. 1872-3. V.-P. 1888-9.)

1886 JACKSON, PHILIP J., 216, Great Dover street, S.E.

1875 JALLAND, WILLIAM HAMERTON, St. Leonard's House, Museum street, York.

1897 JAMES, G. T. B., Carlisle mansions, Victoria street, S.W.

1888 JAMES, JAMES THOMAS, M.D., 30, Harley street, W.

1858 **Jardine**, JOHN LEE, Capel, near Dorking, Surrey.

1897 **JENNER**, LOUIS, M.B., 4A, Bloomsbury square, W.C.

1881 JENNINGS, WILLIAM OSCAR, M.D., Rue Marbœuf, Avenue des Champs Elysées, Paris.

1879 JESSOP, CHARLES MOORE, Clare Lodge, Redhill.

1866 JESSOP, THOMAS RICHARD, 31, Park square, Leeds.

1878 JOHNSON, ARTHUR JUKES, Yorkville, Ontario, Canada.

1876 JOHNSON, CHARLES HENRY, Winton House, Basingstoke, Hants.

1888 JOHNSON, RAYMOND, M.B., B.S., 11, Wimpole street, Cavendish square, W. (C. 1896-9.)

1854 JOHNSTONE, ATHOL A. W., St. Moritz House, 61, Dyke road, Brighton.

1853 **JONES**, SYDNEY, M.B., 18, Portland place, W. (C. 1864-6. V.-P. 1886-7.)

1888 JONES, TALFOURD, M.B., Eastbourne.

1862 **JONES**, THOMAS RIDGE, M.D., 4, Chesham place, S.W. (C. 1882-4.)

1886 JULER, HENRY EDWARD, 23, Cavendish square, W.

1898 KEEP, ARTHUR CORRIE, M.D., M.C., 7, Lower Seymour street, W.

1867 KELLY, CHARLES, M.D., Ellesmere, Gratwicke road, Worthing, Sussex. (M.G.C. 1872-4. C. 1874.)

1897 KELLY, C. E. M., M.D., 9, Highbury grove, N.

1879 KESTEVEN, WILLIAM HENRY, Hillwood, Waverley grove, Hendon, N.W

1859 KIALLMARK, HENRY WALTER, 5, Pembridge gardens, W. (C. 1875-6.)

1882 KIDD, PERCY, M.D., 60, Brook street, W. (C. 1889-91.)

1867 KING, EDWIN HOLBOROW, 30, Norfolk square, Hyde park, W.

1871 KING, ROBERT, M.B., Boyfield House, Moulton, Spalding, Lincolnshire.

1852 **KINGDON**, J. ABERNETHY, Threadneedle street, E.C.

1888 KYNSEY, Sir WILLIAM RAYMOND, K.C.M.G., Oriental Club, Hanover square, W.

1878 LANCEREAUX, ETIENNE, M.D., 44, Rue de la Bienfaisance, Paris.

Digitized by Google

Elected

1882 LANE, WILLIAM ARBUTHNOT, M.B., M.S., 21, Cavendish square, W. (C. 1891-3.)

1869 LARCHER, O., M.D.Par., 97, Rue de Passy, Paris. [M. Kliensieck, Libraire, Rue de Lille 11, Paris, per Messrs. Longmans.]

1884 LARDER, HERBERT, Whitechapel Infirmary, Baker's row, N.E.

1897 LATHAM, A. C., M.B., 44, Brook street, W.

1873 LATHAM, PETER WALLWORK, M.D., 17, Trumpington street, Cambridge.

1876 LAW, WILLIAM THOMAS, M.D., 5, Duchess street, Portland place, W.

1853 LAWRENCE, HENRY JOHN HUGHES, Picton House, Llandowror, St. Clears (C. 1873-5.)

1892 LAWRENCE, THOMAS WILLIAM PELHAM, M.B., 64, South hill park, N.W.

1893 LAWSON, ARNOLD, M.D., 12, Harley street, W.

1859 LAWSON, GEORGE, 12, Harley street, W. (C. 1870-1. V.-P. 1884-5.)

1879 LAYCOCK, GEORGE LOCKWOOD, M.B., Melbourne, Victoria, Australia.

1891 LAZARUS-BARLOW, WALTER SYDNEY, M.D., Cecil House, Cavendish road, Sutton, Surrey.

1875 LEDIARD, HENRY AMBROSE, M.D., 35, Lowther street, Carlisle. (C. 1897—.)

1879 LEECH, DANIEL JOHN, M.D., 96, Mosley street, Manchester.

1877 **LEES**, DAVID B., M.D., 22, Weymouth street, W. (C. 1890-2.)

1867 LEES, JOSEPH, M.D., 21, Brixton road, S.W.

1877 LEESON, JOHN RUDD, M.D., C.M., 6, Clifden road, Twickenham.

1868 LEGG, JOHN WICKHAM, M.D. (Travelling.) (C. 1874-5.)

1892 LEITH, ROBERT FRASER CALDIE, M.B., C.M., B.Sc.

1892 **Leudet**, ROBERT, 16, Rue du Contrat Social, Rouen, France.

1861 LICHTENBERG, GEORGE, M.D., 47, Finsbury square, E.C.

1897 LISTER, THOMAS DAVID, 95, Wimpole street, W.

1895 LITTLE, ERNEST GRAHAM GORDON, M.D., 61, Wimpole street, W.

1889 LITTLE, JOHN FLETCHER, M.B., 32, Harley street, W.

1862 **LITTLE**, LOUIS S., Shanghai, China.

1896 LITTLEWOOD, HARRY, 40, Park square, Leeds.

1874 LIVEING, EDWARD, M.D., 52, Queen Anne street, W.

1863 **LIVEING**, ROBERT, M.D., 11, Manchester square, W. (C. 1876.)

1882 LOCKWOOD, C. B., 19, Upper Berkeley street, W. (C. 1893-6.)

1881 LUBBOCK, MONTAGU, M.D., 19, Grosvenor street, W.

1897 LUCAS, ALBERT, 9, Easy row, Birmingham.

1873 LUCAS, R. CLEMENT, M.B., B.S., 50, Wimpole street, W. (C. 1883-5.)

1879 LUNN, JOHN REUBEN, St. Marylebone Infirmary; Rackham street, Ladbroke grove road, W. (C. 1897—.)

1887 LYON, THOMAS GLOVER, M.D., 8, Finsbury circus, E.C.

1871 **MAC CORMAC**, Sir WILLIAM, Bart., K.C.V.O., 13, Harley street, W. (C. 1878-80.)

Digitized by Google

Elected

1893 McFadyean, John, M.B., Royal Veterinary College, Great College street, N.W. (C. 1899—.)

1896 Macfadyen, Allan, M.D., B.Sc., Jenner Institute of Preventive Medicine, Chelsea bridge, S.W.

1882 Mackenzie, Frederic Morell, 29, Hans place, S.W.

1885 Mackenzie, Hector William Gavin, M.A., M.D., 59, Welbeck street, W. (C. 1895-7.)

1870 Mackenzie, John T., Bombay, India.

1878 Mackenzie, Stephen, M.D., 18, Cavendish square, W. (C. 1888-90.)

1879 Maclagan, Thomas John, M.D., 9, Cadogan place, S.W.

1865 MacLaurin, Henry Normand, M.D., 187, Macquarie street, Sydney, New South Wales.

1896 McWeeney, Edmond Joseph, M.D., M.Ch., 84, St. Stephen's green, Dublin.

1885 Maguire, Robert, M.D., 4, Seymour street, W.

1877 Makins, George Henry, 47, Charles street, Berkeley square, W. (C. 1889-91. V.-P. 1899—.)

1887 Malcolm, John David, M.B., C.M., 13, Portman street, W.

1892 Mann, Harold Edward, Alderney.

1890 Manson, Patrick, M.D., C.M., 21, Queen Anne street, W.

1876 Maples, Reginald, Kingsclere, near Newbury.

1868 Marsh, F. Howard, 30, Bruton street, W. (C. 1876-7.) (V.-P. 1889-90.)

1887 Martin, Sidney, M.D., B.S., F.R.S., 10, Mansfield street, W. (C. 1893-6.)

1889 Mason, David James, M.D., Rosemont, Maidenhead.

1867 Mason, Philip Brookes, Burton-on-Trent.

1898 Masterman, Ernest William Gurney, 3, Newnham terrace, Cambridge.

1892 Masters, John Alfred, M.D., 15, Half Moon street, Piccadilly, W.

1884 Maudsley, Henry Carr, M.D., 11, Spring street, Melbourne, Victoria.

1897 Maxwell, J. P., c/o E.P. Mission, Amoy, China.

1852 May, George, M.B., Reading.

1888 May, William Page, M.D., B.Sc., 49, Welbeck street, W., and Helouan, near Cairo, Egypt (November to April).

1881 Maylard, Alfred Ernest, M.B., 4, Berkeley terrace, Glasgow.

1874 Meredith, William Appleton, C.M., 21, Manchester square, W.

1894 Michels, Ernst, M.D., 6, West street, Finsbury circus, E.C.

1882 Money, Angel, M.D., Hunter street, Sydney, New South Wales.

1879 Moore, Norman, M.D., 94, Gloucester place, Portman square, W. (C. 1885-7. M.G.C. 1889—. V.-P. 1895-7.)

1875 Morgan, John H., 68, Grosvenor street, W. (C. 1886-8.)

1874 Morison, Alexander, M.D., C.M., 14, Upper Berkeley street, W.

1869 Morris, Henry, M.A. (Trustee), 8, Cavendish square, W. (C. 1877-9 1884-6. S. 1881-3. V.-P. 1888-9.)

Digitized by Google

Elected

1879 Morris, Malcolm Alexander, 8, Harley street, W.
1894 Morrice, George Gavin, M.D., Holy Trinity Vicarage, Weymouth.
1891 Morton, Charles A., 14, Vyvyan terrace, Clifton, Bristol.
1875 Morton, John, M.B., Guildford.
1884 Mott, Frederick Walker, M.D., F.R.S., 25, Nottingham place, W. (C. 1891-3. V.-P. 1899—.)
1893 Mummery, John Howard, 10, Cavendish place, W.
1876 Munro, William, M.D., C.M., 13, King William street, E.C.
1885 Murray, Hubert Montague, M.D., 25, Manchester square, W. (C. 1896-9.)
1894 Murray, John, M.B., B.Ch., 110, Harley street, W.

1887 Nason, Edward Noel, M.D., 80, Abbey street, Nuneaton.
1873 Nettleship, Edward, 5, Wimpole street, W. (C. 1882-4.)
1875 Newby, Charles Henry, 15, Landport terrace, Southsea, Hants.
1884 Newland-Pedley, F., 32, Devonshire place, Portland place, W.
1865 Newman, William, M.D., Stamford, Lincolnshire.
1895 Nias, J. Baldwin, M.D., 5, Rosary gardens, S. Kensington, S.W.
1868 Nicholls, James, M.D., Trekenning House, St. Columb, Cornwall.
1876 Nicholson, Frank, M.D., 29, Albion street, Hull.
1864 NORTON, Arthur T., C.B., Ashampstead, Berks. (C. 1877-9.)
1883 Norvill, Frederic Harvey, M.B., Dibrooghur, India.
1856 Nunn, Thomas William, 8, Stratford place, W. (C. 1864-6. V.-P. 1878-80.)

1880 O'Connor, Bernard, M.D., 25, Hamilton road, Ealing.
1873 O'Farrell, George Plunkett, M.D., 19, Fitzwilliam square, Dublin.
1894 Ogle, Cyril, M.B., 96, Gloucester place, W. (C. 1899—.)
1850 Ogle, John W., M.D., 96, Gloucester place, Portman square, W. (C. 1855-6. S. 1857-60. C. 1861-3. V.-P. 1865-8.)
1876 Oliver, John Ferens, M.D., 12, Old Elvet, Durham.
1888 Openshaw, Thomas Horrocks, M.S., 16, Wimpole street, W.
1875 Ord, William Miller, M.D., 37, Upper Brook street, W. (C. 1880-2. V.-P. 1893-4.)
1892 Ord, William Wallis, M.D., The Hall, Salisbury.
1879 Ormerod, J. A., M.D., 25, Upper Wimpole street, W. (C. 1887-9.)
1875 OSBORN, Samuel, 1a, Devonshire street, W., and Maisonnette, Datchet, Bucks.
1881 Owen, Isambard, M.D., 40, Curzon street, W.
1865 Owles, James Allden, M.D., Hill View, Woking, Surrey.

1870 Paget, Sir James, Bart., D.C.L., LL.D., F.R.S., 5, Park square West, Regent's park, N.W. (P. 1887-8.)
1884 Paget, Stephen, 70, Harley street, W. (C. 1894-7.)
1895 Pakes, Walter Charles, Guy's Hospital, S.E.

Digitized by Google

Elected

1897 PARFITT, CHARLES D., M.D., London, Canada.

1898 PARKER, ARTHUR PERCY, M.B., B.Ch., Middlesex Hospital, W.

1872 PARKER, ROBERT WILLIAM, 13, Welbeck street, W. (C. 1881-3. M.G.C. 1884-94. V.-P. 1897-9.)

1874 PARKER, RUSHTON, M.B., B.S., 59, Rodney street, Liverpool.

1853 PARKINSON, GEORGE, Halsdown House, Exmouth, South Devon.

1882 PASTEUR, WILLIAM, M.D., 4, Chandos street, W. (C. 1893-6.)

1885 PAUL, FRANK THOMAS, 38, Rodney street, Liverpool.

1865 PAVY, FREDERICK WILLIAM, M.D., LL.D., F.R.S., 35, Grosvenor street, W. (C. 1872-4. V.-P. 1891-2. P. 1893-4.)

1868 PAYNE, JOSEPH FRANK, M.D. (TRUSTEE), 78, Wimpole street, W. (M.G.C. 1872-85. C. 1873-5, 1883-5. S. 1880-2. V.-P. 1888-9. P. 1897-8.)

1872 PEARCE, JOSEPH CHANING, M.D., C.M., Montague House, St. Lawrence-on-Sea, Kent.

1879 PEEL, ROBERT, 130, Collins street East, Melbourne, Victoria.

1889 PENBERTHY, JOHN, Royal Veterinary College, Camden Town, N.W.

1887 PENROSE, FRANCIS GEORGE, M.D., 84, Wimpole street, W.

1884 PEPPER, AUGUSTUS JOSEPH, M.B., C.M., 13, Wimpole street, W.

1888 PERRY, EDWIN COOPER, M.D., Superintendent's House, Guy's Hospital, S.E.

1878 PHILIPPS, SUTHERLAND REES, M.D., St. Ann's heath, Virginia Water, Chertsey.

1878 PHILLIPS, JOHN WALTER, 30, Stanley street, West Melbourne, Victoria.

1863 PICK, THOMAS PICKERING, 18, Portman street, W. (M.G.C. 1869-73. C. 1870-1. V.-P. 1885-7.)

1896 PIGG, T. STRANGEWAYS, New Museums, Cambridge.

1893 PINKERTON, ROBERT A., M.A., M.D., 15, South Norwood hill, S.E.

1884 PITT, GEORGE NEWTON, M.D., 15, Portland place, W. (M.G.C. 1889-97. C. 1890-2, 1896-9. S. 1894-6. V.-P. 1899—.)

1876 PITTS, BERNARD, M.A., M.C., 109, Harley street, W. (C. 1888-90.)

1883 POLAND, JOHN, 4, St. Thomas's street, Southwark, S.E.

1882 POLLARD, BILTON, M.B., B.S., 24, Harley street, W. (C. 1895-7.)

1850 POLLOCK, JAMES EDWARD, M.D., 52, Upper Brook street, W. (C. 1862-4. V.-P. 1879-81.)

1870 POORE, GEORGE VIVIAN, M.D., 32, Wimpole street, W. (C. 1883-5.)

1879 POTTER, HENRY PERCY, M.D., St. Mary Abbotts' Infirmary, Marloes road, Kensington, W.

1884 POWER, D'ARCY, M.A., M.B., 10A, Chandos street, W. (C. 1891-3, 1899—. M.G.C. 1897—. S. 1897-9.)

1865 POWER, HENRY, 37A, Great Cumberland place, W. (C. 1876-7.)

1887 PRATT, WILLIAM SUTTON, M.D., Penrhos House, Rugby.

1884 PRICE, J. A. P., M.D., 124, Castle street, Reading.

1856 PRIESTLEY, Sir WILLIAM OVEREND, M.D., M.P., 17, Hertford street, W.

1888 PRIMROSE, ALEXANDER, M.B., C.M., 196, Simcoe street, Toronto, Canada.

Digitized by Google

Elected

1882 PRINGLE, J. J., M.B., C.M., 23, Lower Seymour street, W.
1895 PURVIS, WILLIAM PRIOR, M.D., 2, Avenue place, Southampton.
1865 PYE-SMITH, PHILIP HENRY, M.D., F.R.S., 48, Brook street, W. (C. 1874-7. V.-P. 1890-1.)

1897 RANKIN, GUTHRIE, M.D., 4, Chesham street, S.W.
1890 **Ransom,** WILLIAM BRAMWELL, M.D., The Pavement, Nottingham.
1891 RATCLIFFE, JOSEPH RILEY, M.B., C.M., Wake green, Moseley.
1887 RAVEN, THOMAS FRANCIS, Broadstairs, Kent.
1870 RAY, EDWARD REYNOLDS, 67, Grosvenor street, W.
1875 REID, ROBERT WILLIAM, M.D., C.M., 8, Queen's gardens, Aberdeen.
1881 RENNER, WILLIAM, Wilberforce street, Free Town, Sierra Leone.
1893 RENNIE, GEORGE EDWARD, M.D., College street, Hyde park, Sydney, N.S.W.
1895 RITCHIE, JAMES, M.D., 28, Beaumont street, Oxford.
1865 **Roberts,** DAVID LLOYD, M.D., 11, St. John's street, Manchester.
1871 ROBERTS, FREDERICK THOMAS, M.D., 102, Harley street, W. (C. 1883-5.)
1878 ROBERTS, WILLIAM HOWLAND, M.D., Surgeon, Madras Army.
1888 ROBERTSON, ROBERT, M.D., The Bungalow, Ventnor, Isle of Wight.
1885 ROBINSON, ARTHUR HENRY, M.D., Mile End Infirmary, Bancroft road, N.E.
1887 ROBINSON, HENRY BETHAM, M.S., 1, Upper Wimpole street, W. (C. 1896-9.)
1882 ROBINSON, TOM, M.D., 9, Princes street, Cavendish square, W.
1897 ROGER-SMITH, HUGH, M.D., 1, College terrace, Fitzjohn's avenue, N.W.
1888 ROLLESTON, HUMPHRY DAVY, M.A., M.D. (HON. SECRETARY), 112, Harley street. (C. 1894-7. M.G.C. 1895—. S. 1898—.)
1858 **ROSE,** HENRY COOPER, M.D., 16, Warwick road, Maida hill, N.W. (C. 1873-4.)
1876 ROSE, WILLIAM, M.B., B.S., 17, Harley street, W.
1875 ROSSITER, GEORGE FREDERICK, M.B., Cairo Lodge, Weston-super-Mare.
1877 **ROTH,** BERNARD, 38, Harley street, W., and "Wayside," 1, Preston park avenue, Brighton.
1888 ROUGHTON, EDMUND WILKINSON, M.D., 38, Queen Anne street, W.
1891 ROUILLARD, LAURENT ANTOINE JOHN, M.B., Durban, Natal.
1891 RÜFFER, MARC ARMAND, M.D., The Quarantine Board, Alexandria.
1897 RUNDLE, H., 13, Clarance parade, Southsea.
1895 RUSSELL, JAMES SAMUEL RISIEN, M.D., 4, Queen Anne street, W.
1891 RUSSELL, WILLIAM, M.D., 3, Walker street, Edinburgh.

1854 SANDERSON, Sir JOHN BURDON, Bart., M.D., D.C.L., F.R.S., 64, Banbury road, Oxford. (M.G.C. 1869-76. C. 1864-7. V.-P. 1873-4.)
1897 SANTI, P. R. W. DE, 42, Harley street, W.

Digitized by Google

Elected

1886 SAUNDBY, ROBERT, M.D., 83A, Edmund street, Birmingham.

1871 SAUNDERS, CHARLES EDWARD, M.D., Sussex County Lunatic Asylum, Hayward's Heath.

1890 SAUNDERS, FREDERICK WILLIAM, M.B., B.C., Chieveley House, Newbury.

1873 SAVAGE, GEORGE HENRY, M.D., 3, Henrietta street, Cavendish square, W. (C. 1881-3.)

1882 SAVILL, THOMAS DIXON, M.D., 60, Upper Berkeley street, W.

1891 SCHORSTEIN, GUSTAVE ISIDORE, M.B., B.Ch., 11, Portland place, W.

1877 SEMON, Sir FELIX, M.D., 39, Wimpole street, W. (C. 1885-7.)

1894 SEQUEIRA, JAMES HARRY, M.D., 13, Welbeck street, Cavendish square, W.

1872 SERGEANT, EDWARD, D.P.H., Town Hall, Preston, Lancashire.

1876 SHARKEY, SEYMOUR J., M.D., 22, Harley street, W. (M.G.C. 1884-95. C. 1884-6. V.-P. 1895-7.)

1880 SHATTOCK, SAMUEL G., 4, Crescent road, The Downs, Wimbledon, S.W (M.G.C. 1884—. C. 1885-7, 1893-6. S. 1890-2. V.-P. 1896-7.)

1898 SHAW, HAROLD BATTY, M.D., University College Hospital, Gower street, W.C.

1885 SHAW, LAURISTON ELGIE, M.D., 10, St. Thomas's street, S.E.

1886 **SHERRINGTON**, CHARLES SCOTT, M.D., F.R.S., Holt Prof. of Physiol., University College, Liverpool. (C. 1894-7.)

1856 **SHILLITOE**, BUXTON, 2, Frederick's place, E.C.

1875 SIDDALL, JOSEPH BOWER, M.D., C.M., Conybeare, Northam, Bideford.

1880 SILCOCK, A. QUARRY, M.D., B.S., 52, Harley street, W. (C. 1888-90.)

1866 SIMS, FRANCIS MANLEY BOLDERO, 12, Hertford street, W.

1892 SLATER, CHARLES, M.B., St. George's Hospital, S.W.

1887 SMALLPEICE, WILLIAM DONALD, 42, Queen Anne's gate, S.W.

1875 **Smee**, ALFRED HUTCHINSON, The Grange, Hackbridge, Carshalton, Surrey.

1879 SMITH, E. NOBLE, 24, Queen Anne street, W.

1887 SMITH, FREDERICK JOHN, M.D., 138, Harley street, W.

1875 SMITH, GEORGE JOHN MALCOLM, M.D., Hurstpierpoint, Sussex.

1894 SMITH, GUY BELLINGHAM, M.B., B.S., 24, St. Thomas's street, S.E.

1873 SMITH, RICHARD T., M.D., 117, Haverstock hill, N.W.

1883 SMITH, ROBERT PERCY, M.D., 36, Queen Anne street, W.

1869 SMITH, ROBERT SHINGLETON, M.D., Deepholm, Clifton Park, Bristol.

1892 SMITH, SOLOMON CHARLES, M.D., Four Oaks, Walton-on-Thames, Surrey.

1856 SMITH, Sir THOMAS, Bart., 5, Stratford place, W. (C. 1867-9. V.-P. 1877-8.)

1866 SMITH, WILLIAM, Melbourne, Australia.

1870 SMITH, WILLIAM JOHNSON, Seamen's Hospital, Greenwich, S.E. (C. 1879-81.)

1870 SNOW, WILLIAM VICARY, M.D., Richmond Gardens, Bournemouth.

1888 SOLLY, ERNEST, M.B., Strathlea, Harrogate, Yorks.

1887 SPENCER, WALTER GEORGE, M.S., 35, Brook street, W. (M.G.C. 1894—C. 1896-9.)

1861 SQUIRE, ALEXANDER BALMANNO, M.B., 24, Weymouth street, W.

Digitized by Google

Elected

1890 STABB, EWEN CARTHEW, 57, Queen Anne street, W.
1895 STARLING, ERNEST HENRY, M.D., F.R.S., 8, Park square West, Regent's park, N.W.
1896 STEPHENS, J. W. W., M.D., Pathological Laboratory, Cambridge.
1891 STILES, HAROLD JALLAND, M.B., C.M., 5, Castle terrace, Edinburgh.
1897 STILL, G. F., M.D., 46, Gower street, W.C.
1879 STIRLING, EDWARD CHARLES, C.M.G., M.D., F.R.S., Adelaide, South Australia [care of Messrs. Elder & Co., 7, St. Helen's place, E.C.].
1883 STOKER, GEORGE, 14, Hertford street, W.
1884 STONHAM, CHARLES, 4, Harley street, W. (C. 1893-6.)
1875 STURGE, W. A., M.D., 29, Boulevard Dubouchage, Nice.
1871 **SUTHERLAND**, HENRY, M.D., 21, New Cavendish street, W.
1867 SWAIN, WILLIAM PAUL, 17, The Crescent, Plymouth.
1881 SYMONDS, CHARTERS JAMES, M.S., 58, Portland place, W. (M.G.C. 1884-91. C. 1886-8. V.-P. 1899—.)

1886 TARGETT, JAMES HENRY, M.B., M.S., 6, St. Thomas's street, S.E. (M.G.C. 1894—. C. 1894-5, 1897—. S. 1895-7.)
1870 TAY, WARREN, 4, Finsbury square, E.C. (C. 1881-2.)
1871 **TAYLOR**, FREDERICK, M.D., 20, Wimpole street, W. (M.G.C. 1879-89. C. 1879-81. V.-P. 1897-9.)
1885 TAYLOR, HENRY H., 10, Brunswick place, Brighton.
1892 TAYLOR, JAMES, M.D., 49, Welbeck street, W.
1879 THIN, GEORGE, M.D., 63, Harley street, W. (C. 1889-90.)
1852 **THOMPSON**, Sir HENRY, Bart., 35, Wimpole street, W. (S. 1859-63. C. 1865-7. V.-P. 1868-70.)
1897 THOMSON, H. CAMPBELL, M.D., 34, Queen Anne street, W.
1891 THOMSON, HENRY ALEXIS, M.D., 32, Rutland square, Edinburgh.
1884 THOMSON, JOHN, M.D., C.M., 14, Coates crescent, Edinburgh.
1894 THOMSON, STCLAIR, M.D., 28, Queen Anne street, W.
1892 **Thorburn**, WILLIAM, B.S., 2, St. Peter's square, and Rusholme Lodge, Rusholme, Manchester.
1874 THORNTON, JOHN KNOWSLEY, M.B., Hildersham Hall, Cambridge.
1872 THORNTON, WILLIAM PUGIN, 35, St. George's place, Canterbury.
1880 TIBARD, NESTOR ISIDORE, M.D., 74, Harley street, W.
1884 TIVY, WILLIAM JAMES, 8, Lansdowne place, Clifton, Bristol.
1897 TOOGOOD, F. SHERMAN, M.D., The Infirmary, 282, High street, Lewisham, S.E.
1882 TOOTH, HOWARD HENRY, M.D., 34, Harley street, W. (C. 1892-4. M.G.C. 1895—.)
1886 TOTSUKA, KANKAI, Tokio.
1872 **TOWNSEND**, THOMAS SUTTON, 68, Queen's gate, S.W.
1888 TREVELYAN, E. F., M.D., 40, Park square, Leeds.
1881 TREVES, FREDERICK, 6, Wimpole street, W. (C. 1887-90. V.-P. 1895-7.)
1851 TROTTER, JOHN W., 4, St. Peter's terrace, York. (C. 1865-9.)

Digitized by Google

Elected

1895 Troutbeck, Henry, M.B., B.C., 148, Ashley gardens, S.W.
1859 **Truman**, Edwin Thomas, 23, Old Burlington street, W.
1888 Tubby, Alfred Herbert, M.S., 25, Weymouth street, Portland place, W.
1867 Tuckwell, Henry Matthews, M.D., 64, High street, Oxford.
1858 Tudor, John, Dorchester, Dorset.
1875 **Turner**, Francis Charlewood, M.D., 15, Finsbury square, E.C. (C. 1884-6, 1895-7. M.G.C. 1884-95. S. 1891-3. V.-P. 1898—.)
1882 Turner, George Robertson, 41, Half Moon street, W.
1863 Turner, James Smith, 12, George street, Hanover square, W.
1890 Turner, William Alderen, M.D., 13, Queen Anne street, W.
1893 Turney, Horace George, M.D., M.Ch., 68, Portland place, W.
1858 **Turtle**, Frederick, M.D., Kirkmead, Woodford, Essex.
1880 Tyson, William Joseph, M.D., 10, Langhorne gardens, Folkestone.

1867 Venning, Edgcombe, 30, Cadogan place, S.W.
1889 Voelcker, Arthur Francis, M.D., B.S., 31, Harley street, W. (C. 1895-7.)

1867 **Wagstaffe**, William Warwick, B.A., Purleigh, St. John's hill, Sevenoaks. (C. 1874, 1878-80. M.G.C. 1874-82. S. 1875-7.)
1885 Wakley, Thomas, jun., 5, Queen's gate, S.W.
1893 Walker, Norman Purvis, M.D., 7, Manor place, Edinburgh.
1881 Waller, Bryan Charles, M.D., Masongill House, Cowan bridge, Kirkby-Lonsdale.
1890 Wallis, Frederick Charles, M.B., B.C., 26, Welbeck street, W. (C. 1898—.)
1888 Walsham, Hugh, M.A., M.D., B.C., 114, Harley street, W.
1873 Walsham, William Johnson, M.B., C.M., 77, Harley street, W. (C. 1881-3.)
1859 Walters, John, M.B., Reigate, Surrey.
1892 Ward, Allan Ogier, M.D.Edin., Lansdowne House, Tottenham.
1892 Waring, Holburt Jacob, M.B., M.S., 9, Upper Wimpole street, W.
1889 Washbourn, John Wichenford, M.D., 6, Cavendish place, W. (C. 1897—.)
1891 Waterhouse, Herbert Furnivall, M.D., C.M., 81, Wimpole street, W.
1892 Weaver, Frederick Poynton, M.D., Cedar Lawn, Hampstead Heath, N.W.
1890 Webb, Charles Frere, M.D., New street House, Basingstoke.
1894 **Weber**, Frederick Parkes, M.D., 19, Harley street, W.
1858 **Weber**, Sir Hermann, M.D., 10, Grosvenor street, W. (C. 1867-70. V.-P. 1878-80.)
1864 Welch, Thomas Davies, M.D. (Travelling).
1894 Wells, Sydney Russell, M.D., 24, Somerset street, Portman square, W.

Digitized by Google

Elected

1892 WESBROOK, FRANK F., M.D.(Winnipeg).

1877 WEST, SAMUEL, M.D., 15, Wimpole street, W. (C.1884-6, 1891-3. S. 1889-90. V.-P. 1896-7.)

1888 WETHERED, FRANK J., M.D., 83, Harley street, W.

1891 WHEATON, SAMUEL WALTON, M.D., 76, The Chase, Clapham Common, S.W.

1867 WHIPHAM, THOMAS TILLYER, M.D., 11, Grosvenor street, W. (C. 1880-2.)

1869 WHIPPLE, JOHN H. C., M.D., Royal Army Medical Corps.

1877 WHITE, CHARLES HAYDON, 20, Shakespeare street, Nottingham.

1894 WHITE, CHARLES POWELL, M.B., 130, Hyde park road, Leeds.

1891 WHITE, GILBERT B. MOWER, M.B., B.S., 112, Harley street, W.

1881 WHITE, WILLIAM HALE, M.D., 65, Harley street, W. (C. 1888-90.)

1886 WHITE, WILLIAM HENRY, M.D., 43, Weymouth street, W.

1868 **Whitehead**, WALTER, 17, Market street, Manchester.

1897 WHITFIELD, ARTHUR, M.D., 12, Upper Berkeley street, Portman square, W.

1877 WHITMORE, WILLIAM TICKLE, 7, Arlington street, S.W.

1870 WICKSTEED, FRANCIS WILLIAM, 2, Prince's mansions, Victoria street, S.W.

1869 WILKIN, JOHN F., M.D., M.C., Rose Ash House, South Molton, N. Devon.

1871 WILKINSON, J. SEBASTIAN, The Laurels, Oakengates, Salop.

1855 **WILKS**, Sir SAMUEL, Bart., M.D., F.R.S. (TRUSTEE), 72, Grosvenor street, W. (C. 1857-60. V.-P. 1869-72, 1883-5. P. 1881-2.)

1879 WILLCOCKS, FREDERICK, M.D., 14, Mandeville place, W.

1886 WILLETT, EDGAR, M.B., 25, Welbeck street, W. (C. 1897—.)

1869 WILLIAMS, ALBERT, M.D. (Travelling).

1858 **Williams**, CHARLES, 48, Prince of Wales road, Norwich.

1866 WILLIAMS, CHARLES THEODORE, M.D., 2, Upper Brook street, W. (C. 1875-8.)

1881 WILLIAMS, DAWSON, M.D., B.S., 101, Harley street, W. (C.1893-6.)

1872 WILLIAMS, Sir JOHN, Bart., M.D., 63, Brook street, W. (C. 1878-80.)

1881 WILLIAMS, W. ROGER, Beaufort House, Clifton Down, Clifton.

1876 WILLIAMSON, JAMES MANN, M.D., Ventnor, Isle of Wight.

1863 WILLIS, FRANCIS, M.D., Asheville, N. Carolina, U.S.A.

1889 WILSON, ALBERT, M.D., Leytonstone, Essex.

1888 WILSON, CLAUDE, M.D., C.M., Church road, Tunbridge Wells.

1859 WILSON, EDWARD THOMAS, M.B., Montpelier terrace, Cheltenham.

1891 WILSON, THEODORE STACEY, M.D., C.M., 29, Temple row, Birmingham.

1861 **Windsor**, THOMAS, Medical Library, Boston, Mass., U.S. [care of B. F. Stevens, 4, Trafalgar square, W.].

1889 WINGRAVE, V. HAROLD WYATT, 11, Devonshire street, Portland place, W.

1874 WISEMAN, JOHN GREAVES, Dearden street, Ossett, Yorkshire.

Digitized by Google

Elected

1865 WITHERBY, WILLIAM H., M.D., Pitt place, Coombe, Croydon.

1883 WOODCOCK, JOHN ROSTRON, Abberley, near Stourport, Worcestershire.

1883 WOODHEAD, GERMAN SIMS, M.D., 6, Scrope terrace, Cambridge. (C. 1891-3. V.-P. 1898—. M.G.C. 1899—.)

1879 WOODWARD, G. P. M., M.D., Deputy Surgeon General; Sydney, New South Wales.

1884 WORTS, EDWIN, 6, Trinity street, Colchester.

1869 WYMAN, WILLIAM S., M.D., Red Brae, 18, Putney hill, S.W.

1890 WYNNE, EDWARD T., M.B., Gladstone, Queensland.

1884 WYNTER, WALTER ESSEX, M.D., 30, Upper Berkeley street, W.

1872 YOUNG, HENRY, M.B., Monte Video, South America.

Digitized by Google

Digitized by Google

ANNUAL REPORT OF COUNCIL,

1898-99.

PRESENTED AT THE ANNUAL MEETING, MAY 16TH, 1899.

YOUR Council have to report the election of thirteen new members during the past session. There have only been five resignations, but the Society has lost by death ten members, including some of its most illustrious names. The actual number of members to-day is 679. The death roll this year includes Dr. Arkle, Mr. Blagden, Dr. Child, Prof. Coats, Mr. Thomas Cooke, Dr. C. J. Hare, Sir William Jenner, Prof. Kanthack, Dr. Port, and Prof. Rutherford.

Sir William Jenner was President in 1873, and was an Honorary Member at the time of his death. Prof. Kanthack served on the Council of the Society from 1894 to 1897, and at the time of his death was a member of the Morbid Growths Committee. Prof. Coats was elected a member of the Society in 1885, but his official duties, and the distance of Glasgow from London, had prevented him from accepting any office. Prof. Rutherford, the eminent Professor of the Institutes of Medicine at Edinburgh, was elected a member in 1869, when he was Professor of Physiology at King's College, London. The death of Sir William Jenner caused a vacancy in the list of honorary Fellows, which the Council filled by nominating the Right Hon. the Lord Lister, P.R.S.

The Morbid Growths Committee co-opted Professor German Sims Woodhead, M.D., to the place of Professor Kanthack, a choice which was afterwards approved by the Council.

In accordance with a previous decision of the Society, arrangements have been made to compile and issue an index to Vols.

Digitized by Google

XXXVIII—L of the 'Transactions.' A small committee was formed to consider the question of making an Index. After due deliberation the following report was drawn up, and was presented to the Council, who adopted it after considerable discussion.

Your Committee beg to report that they have held two meetings, and that they have decided unanimously to lay the following suggestions before the Council of the Pathological Society of London :

(1) Although in 1887 the Council expressed a hope that it would be possible, in due course, to issue a General Index to the first fifty volumes of the 'Transactions' of the Society, your Committee find that the compilation of a new General Index would be a work of enormous labour, and that it would be too expensive for the funds of the Society. It seems probable that the printing and production of such a volume would cost no less than £400, independently of any remuneration to the compiler or compilers.

(2) The Committee recommend, therefore, that Indices be made (*a*) to all the plates and figures in the first fifty volumes of the Society's 'Transactions;' (*b*) to the last thirteen volumes of the Society's 'Transactions,' viz. Vols. XXXVIII—L. That these Indices be printed in a single volume, to be afterwards circulated amongst the members of the Society.

(3) That Mr. Shattock be invited to undertake the work forthwith, that he receive an honorarium of Fifty Guineas, and that he be assisted by an Index Committee consisting of Dr. Payne, the President, Dr. Sidney Coupland, the Treasurer, Mr. D'Arcy Power and Dr. Rolleston, the two Secretaries, and Dr. Garrod, with power to add to their number.

Signed on behalf of the Index Committee,

November 14*th*, 1898. J. F. Payne, *President.*

Mr. Shattock has undertaken to compile the Index, and he has already made considerable progress in his task. The Council recommend that the expense of its production should be defrayed, if necessary, out of the capital funds of the Society.

Digitized by Google

The interest of the Society's meetings during the session has been fully maintained, the average attendance of members on each evening being the same as last year, namely, thirty-three. The discussion on pseudo-tuberculosis resulted in the formation of a Committee of Members, who were "requested to consider the nomenclature of the condition." The report of the Committee is appended, and will be published in the forthcoming volume of the 'Transactions.'

The financial year began with a balance in hand of £119 3*s*. 1*d*., and closes with one of £110 16*s*. 8*d*. Of this sum £50 10*s*., representing the amount received from composition fees during the last four years, must be regarded as capital, and will be utilised to defray, in part, the cost of producing the General Index. It will be seen from the balance-sheet that on both sides of the account there has been a diminution in the amounts received and expended as compared with last year, the total income (£450 3*s*. 10*d*.) being about £30 and the total expenditure (£458 15*s*. 3*d*.) about £23 less than for 1897–8. Compared with the average for the three preceding years—1896–8—the income derived from annual subscriptions and entrance fees—amounting to £370 13*s*.—shows a falling off of £10. In respect to the main items of expenditure, that for the meetings—£144 15*s*.—is almost identical with the average of the three preceding years, whilst the cost of producing Vol. XLIX of the 'Transactions'—£234 11*s*. 6*d*.—is about £30 below the average amount expended on Vols. XLVI—XLVIII.

It is to be hoped that the funds of the Society will be increased by a greater influx of new members than has been the case hitherto, in order that the ordinary expenditure may be met without encroaching upon the capital fund, which now stands at £1114 3*s*. 2*d*. invested in Consols, and without starving the 'Transactions,' which form by far the most valuable memorial of the Society's work.

J. F. Payne,

May 16th, 1899. *President.*

Digitized by Google

THE PATHOLOGICAL SOCIETY OF LONDON.

Statement of Receipts and Payments from 14th May, 1898, to 10th May, 1899.

RECEIPTS.	£	s.	d.	£	s.	d.
Balance at Bank—14th May, 1898	108	18	2			
,, in hand—Petty Cash, &c.	10	4	11			
				119	3	1
334 Subscriptions at £1 1s.	350	14	0			
10 Entrance Fees	10	10	0			
3 ,, Non-Resident	9	9	0			
1 Composition Fee	5	5	0			
				375	18	0
Sale of Transactions:						
Publisher	43	19	0			
Assistant Secretary		19	6			
				44	18	6
Dividends on Consols				29	12	4
				£569	11	11

PAYMENTS.	£	s.	d.	£	s.	d.
Meetings:						
Expenses of Rooms to Christmas, 1898	105	0	0			
Refreshments, Attendance, &c.	26	15	0			
Microscopes (Session 1897–8)	13	0	0			
				144	15	0
Transactions:						
Printing, Binding, &c., of Vol. XLIX	188	16	6			
Illustrations	42	12	0			
Indexes for Vols. XLVIII and XLIX	6	6	0			
				237	14	6
Secretariat and Treasury:						
Assistant Secretary	21	0	0			
Collection of Subscriptions	15	15	0			
General Printing and Stationery	27	18	2			
Transfer of Consols	1	5	6			
Cheque book		4	2			
				66	2	10
Petty Cash Expenditure				10	2	11
Balance at Bank	106	12	9			
Petty Cash in hand	4	3	11			
				110	16	8
				£569	11	11

SIDNEY COUPLAND, *Treasurer.*

Audited and found correct, May 10th, 1899.

(Signed) FREDERICK W. ANDREWES, CHARLES D. GREEN, } *Auditors.*

J. F. PAYNE, *President.*

H. D. ROLLESTON, *Hon. Secretary.*

NOTE.—The sum of £1114 3*s.* 2*d.* is invested in Consols.

Digitized by Google

LIST OF SPECIMENS AND REPORTS

BROUGHT BEFORE THE SOCIETY DURING THE SESSION 1898-9.

I. DISEASES, ETC., OF THE NERVOUS SYSTEM.

PAGE

1. A case of embolism of both middle cerebral arteries, rheumatic endocarditis, and carcinoma of the pancreas and liver By L. FREYBERGER, M.D. 1
2. (1) Sarcoma of pineal body, with diffused melanotic sarcoma of the surface of cerebrum. (2) Tumour of pineal body in a boy [With Plate I] By CYRIL OGLE, M.B. 4
3. Tumour of the pineal body By T. W. P. LAWRENCE 12
4. Pineal cyst By A. E. GARROD, M.D. 14
5. Cysts of the pineal body By A. E. RUSSELL, M.D. 15
6. Notes of two cases of dilatation of the central cavity or ventricle of the pineal gland By A. W. CAMPBELL, M.D. 15
7. The pineal gland; its normal structure; some general remarks on its pathology; a case of syphilitic enlargement By JOHN R. LORD, M.B., introduced by Mr. BEADLES 18
8. Sarcomata involving the spinal cord of a child aged three years (Card specimen) By F. E. BATTEN, M.D. 21
9. Further evidence on the pathology of diphtheritic paralysis [With Plate II] By FREDERICK E. BATTEN, M.D. 22
10. Neuroma of brachial plexus, with molluscum fibrosum of skin By T. CARWARDINE, M.S. 27

Digitized by Google

II. DISEASES, ETC., OF THE ORGANS OF RESPIRATION.

PAGE

1. Case of ulcer of the trachea, involving the left recurrent laryngeal nerve, and perforating into the aorta (Card specimen) By NORMAN DALTON, M.D. 30
2. A case of pressure on the recurrent laryngeal nerves by calcareous glands, with anthracosis of the lungs (Card specimen) By NORMAN DALTON, M.D. 31
3. Transverse fracture of the cartilaginous portion of the trachea (Card specimen) By W. S. LAZARUS-BARLOW, M.D. 32
4. Case of hypertrophy of the right lung with obliteration of the left By NORMAN DALTON, M.D. 33
5. Lung, showing uniformly distributed fibrosis (Card specimen) By A. E. GARROD, M.D. 36
6. A case of sarcoma of left lung and mediastinum By CHARLES D. GREEN, M.D., F.R.C.S. 37

III. DISEASES, ETC., OF THE ORGANS OF CIRCULATION.

1. Dextrocardia; left superior vena cava; endocarditis (Card specimen) By NORMAN DALTON, M.D. 41
2. On dilatation of the right ventricle upwards and to the left By T. STACY WILSON, M.D.Edin., M.R.C.P. 41
3. Extreme dilatation of the left auricle without mitral stenosis (Card specimen) By H. MORLEY FLETCHER 48
4. Spontaneous rupture of the heart (Card specimen) By CECIL F. BEADLES 49
5. Heart thrombus in a case of enteric fever; embolism of the right common iliac artery; incipient gangrene of the leg; multiple infarcts in the spleen and kidneys By WILLIAM HUNTER, M.D., F.R.C.P. 52
6. Aneurysm of the splenic artery (Card specimen) By H. D. ROLLESTON, M.D. 55

Digitized by Google

PAGE

7. Aneurysm of splenic artery (Card specimen)
By W. S. Lazarus-Barlow, M.D. 57
8. An apparent thickening of subcutaneous veins
By F. Parkes Weber, M.D., F.R.C.P. 57
9. Tuberculosis of the inferior vena cava (Card specimen)
By J. H. Drysdale, M.D. 60

IV. DISEASES, ETC., OF THE ORGANS OF DIGESTION.

1. Actinomycosis of the tongue
Exhibited by R. G. Hebb, M.D., for Mr. Ludford Cooper 61
2. Congenital cyst of the base of the tongue
By Raymond Johnson 62
3. Epithelial pearls in the tonsil [With Plate III]
By Hugh Walsham, M.A., M.D. 65
4. A tumour arising in the region of the socia parotidis (Card specimen) By H. D. Rolleston, M.D. 66
5. Adeno-lipoma of the submaxillary salivary gland
By H. J. Waring, M.S. 67
6. Idiopathic hypertrophy of the œsophagus
By H. D. Rolleston, M.D. 69
7. Fusiform dilatation of the œsophagus
By W. S. Lazarus-Barlow, M.D. 71
8. Myoma of the œsophagus (Card specimen)
By H. D. Rolleston, M.A., M.D. 73
9. Minute erosion (exulceratio simplex) of the gastric mucous membrane (Card specimen)
By H. D. Rolleston, M.A., M.D. 73
10. Gastric ulcer from a patient with granular kidneys (Card specimen) By H. D. Rolleston, M.D. 75
11. Tubercular ulcer of the stomach in children
By George F. Still, M.D. 76
12. A specimen of tubercular ulceration of the stomach from a child (Card specimen) By T. D. Lister, M.D. 83
13. Myoma of the stomach (Card specimen)
By Alexander G. R. Foulerton 85

Digitized by Google

PAGE

14. Congenital hypertrophy of the pylorus
By George F. Still, M.D. 86
15. Congenital hypertrophy of the pylorus (Card specimen)
By H. Morley Fletcher, M.D. 98
16. Carcinoma of the cardiac orifice of the stomach (Card specimen) By H. D. Rolleston, M.D. 99
17. Carcinoma of the cardiac end of the stomach (Card specimen) By Arthur Voelcker, M.D. 100
18. Spheroidal-cell carcinoma of stomach involving the œsophagus (Card specimen)
By W. S. Lazarus-Barlow, M.D. 101
19. Case of colloid carcinoma of the stomach
By R. G. Hebb, M.D. 102
20. A case of gastrectomy for carcinoma of the stomach
By Thomas F. Chavasse 105
21. Carcinoma developing in the cicatrix of a gastric ulcer (Card specimen)
By H. R. Belcher Hickman, M.B. (introduced by Dr. Lazarus-Barlow) 109
22. A specimen of duodenal ulcer from a case of melæna neonatorum (Card specimen)
By T. D. Lister, M.D. 111
23. Healed perforation of duodenum after passage of gall-stones (Card specimen) By Cecil F. Beadles 113
24. Three cases of sprue By J. H. Drysdale, M.D. 114
25. Fatal summer diarrhœa with acute enteritis
By F. W. Andrewes, M.D. 118
26. Two unusual cases of intussusception
By D'Arcy Power 121
27. Appendix vermiformis in which a pin was lodged (Card specimen) By H. A. Lediard, M.D. 126
28. Peculiar condition of the colon in pernicious anæmia
By H. Morley Fletcher, M.D. 127
29. A specimen of diffuse ulcerative colitis with secondary acute interstitial hepatitis (Card specimen)
By T. D. Lister, M.D. 130
30. Villous papilloma of rectum (Card specimen)
By T. Carwardine, M.S. 133

Digitized by Google

PAGE

31. Enterolith from the rectum (Card specimen)
By Samuel G. Shattock 134
32. Achroo-amyloid liver, spleen, and kidneys
By W. J. Hadley, M.D. 134
33. Acute degeneration of liver cells supervening in the course of chronic cirrhosis (Card specimen)
By F. Parkes Weber, M.D. 136
34. Diffuse infiltration of the liver in congenital syphilis
By H. Morley Fletcher, M.D. 138
35. Diffuse syphilitic change in the liver
By F. Parkes Weber, M D. 142
36. A case of cirrhosis of liver, apparently due to congenital syphilis, with thrombosis of the hepatic veins
By T. Churton, M.D. 145
37. Thrombosis of hepatic vein associated with cirrhosis of the liver, probably syphilitic
By W. S. Lazarus-Barlow, M.D. 146
38. Liver in hepatic and portal thrombosis (Card specimen)
By H. D. Rolleston, M.D. 148
39. Cysts in the liver containing living *Paramœcia coli*
By A. E. Russell, M.D., and E. F. Buzzard, M.B. 149
40. Biliary calculi in children By George F. Still, M.D. 151
41. Syphilitic stricture of bile-ducts (Card specimen)
By W. S. Lazarus-Barlow, M.D. 158
42. Tuberculous cavities in the liver [With Plate IV]
By Herbert Morley Fletcher, M.D., M.R.C.P. 160
43. A case of carcinoma of the liver believed to have been primary in that organ
By Charles D. Green, M.D , F.R.C.S. 166
44. Atrophied pancreas from case of diabetes mellitus (Card specimen) By T. W. P. Lawrence 171
45. Primary columnar-celled carcinoma of the tail of the pancreas (Card specimen)
By H. D. Rolleston, M.D. 171
46. Lesion of the pancreas with fat necrosis (Card specimen)
By Cecil F. Beadles 174
47. Sarcoma of pancreas; glycosuria (Card specimen)
By T. Churton, M.D. 178

Digitized by Google

V. DISEASES, ETC., OF THE GENITO-URINARY ORGANS.

PAGE

1. Contracted kidney with multiple adenomata (Card specimen) By F. Parkes Weber, M.D. 179
2. Small true lipoma of kidney (Card specimen) By F. Parkes Weber, M.D. 181
3. An undescended left testicle By Arthur Voelcker, M.D. 183
4. Prostatic myomata and vesical calculus removed from the same patient (Card specimen) By T. Carwardine, M.S. 183

VI. DISEASES, ETC., OF BONE AND OF THE ORGANS OF LOCOMOTION.

1. An acromegalic skull and that of a normal giant [With Plates V and VI] By Samuel G. Shattock 185
2. Symmetrical senile atrophy of parietal bones (Card specimen) By H. Morley Fletcher, M.D. 195
3. Crushed fracture of cervical spine By H. P. Potter, M.D. 196
4. Central sarcoma of os calcis (Card specimen) By P. de Santi 198
5. A case of apparently aseptic suppuration of the knee-joint following injury, and associated with phagocytosis of extravasated red blood-corpuscles by leucocytes By F. W. Andrewes, M.D. 199

VII. DISEASES, ETC., OF THE DUCTLESS GLANDS.

1. Hypertrophy of the pituitary body By J. and T. W. P. Lawrence 202
2. Two cases of splenic anæmia with internal hæmorrhages in infants By G. Bertram Hunt, M.D. 209

Digitized by Google

PAGE

3. Cystic disease of the supra-renal gland
By Raymond Crawfurd, M.D. 212
4. Cyst of the supra-renal body
By H. D. Rolleston, M.D. 214
5. Some lesions of the supra-renal in the insane
By Cecil F. Beadles 214

VIII. DISEASES, ETC., OF THE SKIN.

Epithelial tumours, probably of congenital origin [With Plate VII] By H. Radcliffe Crocker, M.D. 220

IX. MORBID GROWTHS.

1. Fibroma (congenital) from the neck of a child aged one year and eight months. (Card specimen)
By H. A. Lediard, M.D. 223
2. Adenoma of breast associated with cyst and calcareous degeneration (Card specimen)
By Cecil F. Beadles 223
3. Cystic disease of the breast in a boy aged three years.
By D'Arcy Power 225
4. "Butter" cyst of the breast
By H. Betham Robinson, M.S. 227
5. A peculiar lipoma of the groin (Card specimen)
By Cecil F. Beadles 229
6. Large myxoma from the thigh (Card specimen)
By H. D. Rolleston, M.D. 229
7. Cysts in relation with an inguinal hernial sac in a woman
By H. Betham Robinson, M.S. 230
8. Multiple abdominal dermoids By A. C. Latham, M.B. 232
9. Myeloid tumour of neck By H. J. Waring, M.S. 232
10. A case of multiple fibro-sarcomata of the scalp of nineteen years' duration; removal of growths; subsequent recurrence in lungs
By Philip R. W. de Santi, F.R.C.S.Eng. 234

Digitized by Google

PAGE

11. A case of melanotic sarcoma with secondary growths of unusual size in the small intestine (Card specimen) By H. Campbell Thomson, M.D. 237
12. Round-celled sarcoma involving the region of the pancreas, the supra-renals, liver, and left lung (Card specimen) By Cecil F. Beadles 239
13. A case of umbilical papilloma which showed some activity of growth in a patient fifty years of age, and which was due apparently to the inclusion of a portion of Meckel's diverticulum By Charles D. Green 243
14. A case of substernal carcinoma By W. S. Lazarus-Barlow, M.D. 248
15. Vacuolated carcinoma of the antrum By H. D. Rolleston, M.A., M.D. 249
16. The final sequel to a case already reported of recurrent cystic disease of a supposed accessory thyroid By Arthur E. Barker 251

X. BACTERIOLOGY AND PATHOLOGICAL CHEMISTRY.

1. The relations of chemical composition to germicidal action By James Ritchie, M.D. 256
2. On infections by unsound meat, more especially with regard to the *Bacillus enteritidis* (Gärtner) By Herbert E. Durham 262
3. Congenital tuberculosis in calves By J. McFadyean, M.B., B.Sc. 268
4. Section showing a mycosis (? aspergillar) of lung of horse (Card specimen) [With Plate VIII] By Alexander G. R. Foulerton 272
5. Blackwater, or hæmoglobinuric fever By W. H. Crosse and W. C. C. Pakes 273
6. Chromocyte clumping in acute pneumonia and certain other diseases, and the significance of the buffy coat in the shed blood [With Plate IX] By Samuel G. Shattock 279
7. An account of some experiments upon the toxicity of normal urine By W. P. Herringham, M.D., F.R.C.P. 293

Digitized by Google

XI. MISCELLANEOUS COMMUNICATIONS.

PAGE

1. A case of congenital limb deficiency and redundancy [With Plate X] By R. Barwell 319
2. The histology of the rheumatic nodule By F. J. Poynton, M.D., and G. F. Still, M.D. 324
3. The technique of blood films By W. C. C. Pakes and R. Howard 328

XII. DISCUSSION ON PSEUDO-TUBERCULOSIS.

Introductory address By Prof. G. Sims Woodhead 331
S. H. C. Martin, M.D., F.R.S. . . . 342
J. W. Washbourn, M.D. 344
J. Galloway, M.D. 345
Professor J. McFadyean, M.B. . . . 347
A. G. R. Foulerton, F.R.C.S. [With Plates XI and XII] 348
W. C. C. Pakes 352
W. S. Lazarus-Barlow, M.D. . . . 353
F. J. Wethered, M D. 357
Professor Woods Hutchinson . . . 357
Report of the Committee of the Pathological Society of London, appointed to consider the nomenclature of the conditions sometimes described as Pseudo-tuberculosis 361
[J. F. Payne, M D. (*Chairman*), J. McFadyean, M.B., S. G. Shattock, J. W. Washbourn, M.D., G. Sims Woodhead, M.D. A. G. R. Foulerton (*Secretary*).]

Digitized by Google

REPORTS OF THE COMMITTEE ON MORBID GROWTHS.

PAGE

1. On Dr. C. D. Green's case of umbilical papilloma in a patient aged fifty years
[H. D. Rolleston, D'Arcy Power] 247
2. On Mr. Arthur Barker's specimen of cystic disease of a supposed accessory thyroid
[J. Berry, A. A. Bowlby, S. G. Shattock] 254

Digitized by Google

LIST OF PLATES.

	TO FACE PAGE
I. Sarcoma of pineal body with diffused melanotic sarcoma of the cerebrum. (Dr. C. OGLE.) (Page 4)	4
II. Diphtheritic paralysis.	
Fig. 1. Cells of anterior cornu at level of fifth cervical root in diphtheritic paralysis	22
Fig. 2. Longitudinal section of left phrenic nerve of same case. (Dr. F. E. BATTEN.) (Page 22)	
III. Epithelial pearls in the tonsil.	
Fig. 1. Three pearls in tonsil; the middle one is partially calcified	65
Fig. 2. Epithelial pearl. (Dr. H. WALSHAM.) (Page 65)	
IV. Tuberculous cavities in the liver.	
Fig. 1. A tuberculous cavity	160
Fig. 2. An earlier stage in the formation of a cavity. (Dr. H. MORLEY FLETCHER.) (Page 160)	
V. Skull of a normal giant.	
Fig. 1. Front view	185
Fig. 2. Lateral view. (Mr. S. G. SHATTOCK.) (Page 185)	
VI. Acromegalic skull.	
Fig. 1. Front view	185
Fig. 2. Lateral view. (Mr. S. G. SHATTOCK.) (Page 185)	
VII. Figs. 1—5. Epithelial tumours probably of congenital origin. (Dr. RADCLIFFE CROCKER.) (Page 220)	220

Digitized by Google

TO FACE PAGE

VIII. Figs. 1, 2. Mycosis [? aspergillar] of lung of a horse. (Mr. A. G. R. Foulerton.) (Page 272) 272

IX. Chromocyte clumping.
Fig. 1. Action of pneumonic blood-serum on normal human blood
Fig. 2. Action of the blood-serum of acute rheumatism upon the blood of a leukæmic patient (Mr. S. G. Shattock.) (Page 279) 279

X. Congenital limb deficiency and redundancy.
Fig. 1. Skiagram showing osseous deformities of left hand
Fig. 2. Photograph showing deformities of both upper extremities
Fig. 3. Skiagram showing bony deformities of right upper extremity. (Mr. R. Barwell.) (Page 319) 319

XI. Results of infection with *Saccharomyces tumefaciens albus*. Illustrating Mr. Foulerton's remarks in the discussion on Pseudo-tuberculosis. (Page 351)
Fig. 1. Tumour at site of inoculation fourteen days after infection (natural size)
Fig. 2. Section through tumour at site of inoculation eight days after infection (× 600)
Fig. 3. Section through another part of the same tumour (× 600) 350

XII. Results of infection with *Saccharomyces tumefaciens*. Illustrating Mr. Foulerton's remarks in the discussion on Pseudo-tuberculosis. (Page 351.)
Fig. 1. Section through a secondary nodule in the diaphragm from same case as the last (× 20)
Fig. 2. Ditto (× 600)
Fig. 3. Pure culture of yeast obtained from tumour at the site of inoculation in second rabbit (× 600). 351

Digitized by Google

LIST OF FIGURES IN THE TEXT.

		PAGE
1, 2.	Sarcoma of the pineal body	4—6
3, 4, 5.	Illustrating central cavity in pineal body	17
6.	Neuroma of brachial plexus with molluscum fibrosum	28
7, 8.	Hypertrophied lung	33
9, 10.	Illustrating dilatation of the right ventricle of the heart	42, 43
11.	Apparent thickening of the subcutaneous veins	58
12, 13.	Congenital cyst of the base of the tongue	62, 63
14.	Adeno-lipoma of the submaxillary gland	68
15.	Carcinomatous stomach removed during life	107
16.	Intussusception	123
17.	Crushed fracture of cervical spine	197
18, 19, 20.	Hypertrophied pituitary body	204, 205
21.	Effect of cold on subsidence of red blood-corpuscles	281
22.	Total absence of right femur	321
23.	Rheumatic nodule	326
	Charts illustrating the toxicity of urine	316, 317, 318

Digitized by Google

Digitized by Google

REPORT.

SESSION 1898-1899.

I. DISEASES, ETC., OF THE NERVOUS SYSTEM.

1. *A case of embolism of both middle cerebral arteries, rheumatic endocarditis, and carcinoma of the pancreas and liver.*

By L. FREYBERGER, M.D.

J. K—, housewife, aged 39, was admitted to the Great Northern Central Hospital on September 24th, 1898, under the care of Dr. Syers, complaining of wasting, occasional vomiting, and pain in the abdomen. She had suffered a great deal from rheumatic pains, but was never laid up with rheumatic fever. She had had several children at term and two miscarriages.

On admission the patient was very pale and thin. There was a faint blowing murmur during the diastole over the base of the left ventricle and at the apex; the area of heart dulness was not increased; the apex-beat was somewhat heaving; pulse 87, regular; respirations 18, regular; there were no other abnormal physical signs in the chest. In the abdomen, across the middle line, about three inches above the navel, a transverse oblong tumour could be felt, which was not moveable or tender on pressure. The liver was considerably enlarged, its surface smooth; the spleen reached the anterior axillary line, and was hard and tender on pressure. The urine contained no abnormal constituents. There was considerable constipation, and the patient complained of feeling sick.

Two days after admission, while in bed, the patient was suddenly taken ill with vomiting and griping pain in her abdomen. A few

Digitized by Google

moments later it was noticed that she was aphasic and paralysed on her right side; the paralysis and aphasia were complete, but the patient was not unconscious. There was also a slight rise of temperature up to 100° F., which subsided after a couple of days. The patient gradually regained her power of speaking, but the extremities of the right side remained completely paralysed.

On October 9th the patient suddenly became quite stuporous, and remained so until her death, lying motionless on her back. Death occurred nine hours after the onset of the stupor.

At the *post-mortem* examination, ten hours after death, the following conditions were found:

Rigor mortis present; body much emaciated, ashy pale; extensive, pale, livid *post-mortem* stains on the back of the trunk and extremities.

The left parietal bone externally bears a roundish, button-like bony excrescence; the bones of the skull are twice as thick as normal and as hard as ivory; the dura mater very adherent to the vitreous table; the grooves for the meningeal arteries very deep and tortuous.

The pia-arachnoid over the whole convexity and at the base thickened and slightly turbid, especially over the two central sulci. The *left* middle cerebral artery, at the spur formed by its division into three branches, is blocked by a small reddish-grey embolus, the size of a millet seed. In front of the embolus is a red thrombus, which is continued in a centripetal direction into the insertion of the frontal branch of the middle cerebral artery. The clot is firmly adherent to the vessel wall, dry and friable. The right middle cerebral artery contains a reddish-grey embolus, the size of a rice corn, situated at the ramification of the middle cerebral artery into the four branches, which are continued on to the frontal and occipital lobes and the island of Reil and the operculum. The embolus is continued centripetally by a dark red thrombus about half an inch long, with a paler whitish-grey tapering proximal end, which reaches as far as the anterior communicans artery. This clot is firm, not adherent to the wall of the artery, and consequently preserves its cylindrical shape. Beyond the emboli the arteries were completely empty.

The substance of the left parietal lobe was considerably softened and the convolutions flattened; the changes on the right side were less obvious. The brain was not dissected.

Digitized by Google

The *lungs* were natural.

The *heart* was small, with a considerable amount of subepicardial fat. The mitral valves showed old fibrous thickening and two patches of recent endocarditic vegetations. The aortic, pulmonary, and tricuspid valves were natural. There was no atheroma of the aorta or large vessels.

The *liver* was large; it contained many metastatic deposits of carcinoma, of various sizes, both in its substance and under the peritoneum. The consistence was increased, the surface smooth.

The *gall-bladder* was natural.

The *spleen* is enlarged to twice its normal size, and contains two small anæmic and one large hæmorrhagic infarct.

The *pancreas*, in its middle third, contains a large primary carcinoma, which is very hard and fibrous. The glandular structure of the tail and head of the pancreas is perfectly normal, but the duct contains several cystic dilatations. The growth of the pancreas was adherent externally to the stomach without encroaching upon its muscular coat or mucosa.

The *stomach* was perfectly natural.

The *kidneys* were large and firm, their capsule somewhat adherent.

The *intestinal canal*, bladder, and genital organs were natural.

No signs of syphilis could be found.

Points of interest:—1. The occurrence of an embolus in each arteria fossæ Sylvii.

2. The combination of carcinoma and endocarditis, which is by no means of frequent occurrence.

3. The different appearance of emboli 1 and 2.

Embolus No. 1 is fourteen days old. The thrombus attached to it is dry, brittle, and firmly adherent to the endothelium of the artery. It is also somewhat reduced in size, owing to the absorption of its liquid constituents. Its colour is dark brick-red.

Embolus No. 2, nine hours old, is succulent, of dark purple colour, not adherent to the inner coat of the artery. It consequently retains its shape when the artery is cut open, whereas No. 1 is broken up into a number of parts which adhere firmly to the wall of the artery. (Cf. paper "A Brain with Three Consecutive Hæmorrhages," 'Path. Soc. Trans.,' vol. xlix.)

November 15*th*, 1898.

Digitized by Google

2. (1) *Sarcoma of pineal body, with diffused melanotic sarcoma of the surface of cerebrum.* (2) *Tumour of pineal body in a boy.*

By Cyril Ogle, M.B.

[With Plate I.]

Case 1.—The first specimen shown is a woman's brain of a very unusual appearance, looking as if the surface had been painted over with sepia and black-lead, or Indian ink. The whole of the cerebrum is covered in this way, but the cerebellum and pons were not; the discoloration is far more marked over the upper and lateral surfaces than at the base.

Beneath the microscope it is seen that the meshes of the pia mater are occupied by melanotic sarcoma, the cells of which are chiefly of a spindle shape, and granules of brownish-black pigment are abundant within them. This growth is spread in a fairly uniform layer over the convolutions, dipping down into the sulci and invading the grey matter, apparently along the sheaths of the fine vessels entering the cortex, so that within the cerebral substance are fine tracts and little islands of melanotic growth, the cells of which, in transverse section, usually have a laminated or concentric arrangement.

Deep in the substance of the hemispheres are to be seen also a few nodules of growth, of the size of small peas.

Fig. 1.

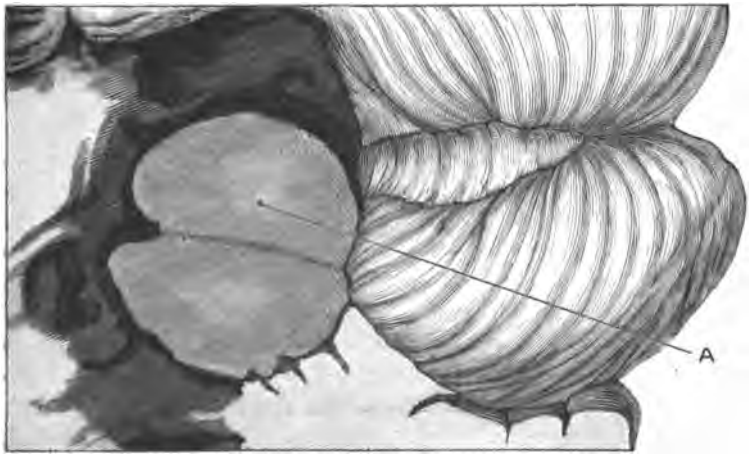

A = sarcoma of the pineal body split in two, and two halves turned aside.

Digitized by Google

Digitized by Google

DESCRIPTION OF PLATE I,

Illustrating Dr. Cyril Ogle's case of Sarcoma of the Pineal Body, with Diffused Melanotic Sarcoma of the Cerebrum, in a woman. (Page 4.)

Showing the melanotic sarcoma spreading over the cortex and invading it.

Digitized by Google

Digitized by Google

DESCRIPTION OF PLATE I.

Illustrating Dr. Cyril Ogle's case of Sarcoma of the Pineal Body, with Diffused Melanotic Sarcoma of the Cerebrum, in a woman. (Page 4.)

Showing the melanotic sarcoma spreading over the cortex and invading it.

Digitized by Google

Digitized by Google

E. A. Wilson del.

Lith. Anst. F. Reichhold, Munch

Digitized by Google

In the position of the pineal body is a globular tumour, measuring about 1½ inches in diameter, pressing aside the optic thalami, which, as well as the corpora quadrigemina, are distorted and slightly invaded by the growth, as shown by their black colour. The tumour is in the middle line, and was attached in the region of the pineal body, but not elsewhere.

Microscopically this growth is also a sarcoma composed of cells of all shapes, some giant-cells, but chiefly of spindle-cells of medium size: granules of pigment are visible in some of the cells, but there is much less pigmentation than in the diffuse growth over the cortex.

There were no other growths in the body, which was in all respects otherwise healthy.

It would thus seem that the diffuse condition of melanotic sarcoma invaded the surface of the brain along the pia mater from the primary growth of the pineal body.

Ziegler describes an alveolar sarcoma or endothelioma of the pia mater, occurring sometimes as a diffused growth over the brain, which, he says, is rarely pigmented, and the cells of which are highly developed, and resemble polymorphous epithelioid cells of carcinoma; but the present example would appear not to be primary in the membranes, although thus diffused, and the cells are those of a mixed-celled sarcoma with pigment in remarkably large amount. Dr. Byron Bramwell, in his book on 'Intra-cranial Tumours,' gives several plates of a brain of exactly similar aspect, from a diffused layer of melanotic sarcoma; but in his case it does not appear whether there was any primary growth in the pineal region, and the details of the case are not given; nor are they, I believe, to be found elsewhere at present.

The patient was a woman aged 32 years, and was under observation for about ten weeks. Her illness began definitely with a sudden state of unconsciousness, accompanied by right-sided paralysis. For a few weeks previously, however, she had been excitable and irritable, with occasional pain in the head; she had complained also, sometimes, of shaking and numbness of the right hand.

Her symptoms after the first fit, apart from *headache, emaciation, choked disc,* and *dulness* of intellect ending in *coma,* were intermittent *aphasia* and right *hemiplegia,* which would last a few days, then clear up, to return again in a few days; eventually the right-sided hemiplegia became permanent.

Digitized by Google

Throughout her illness there appears to have been only one convulsive attack, which is described as affecting all the parts of the body. That there were not more convulsions seems remarkable when one considers the wide extent of the infiltration of the cortex by the new growth.

Case 2.—In the other example shown this evening, a globular lump of about 1 inch in diameter is seen occupying the position of the pineal body, and projecting forwards into the third ventricle; the optic thalami are somewhat pushed aside, and their posterior parts hollowed out, but not invaded. The tumour is adherent to the velum interpositum, which is stretched over it, and the corpora quadrigemina are obviously flattened, and the nates a little hollowed out by the growth above them; but the latter does not seem to have infiltrated any of the parts around, and is attached only in the position of the pineal body.

There were no other growths in the body, all the organs of which were healthy. Excepting for some excess of fluid in the ventricles and at the base, the brain was otherwise healthy.

The pituitary body was natural in appearance.

Fig. 2.

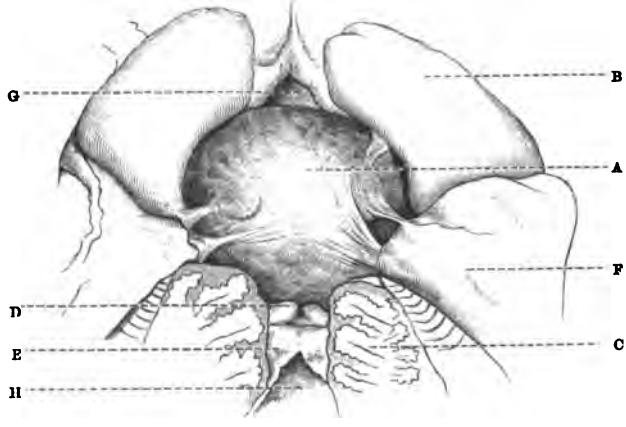

Illustrating Dr. Cyril Ogle's case of pineal tumour in a boy. (Drawn by G. H. Goldsmith, M.B.) A. The tumour of pineal body, covered by velum interpositum, and projecting into the third ventricle (G); it has pushed aside the corpus striatum (B), and the optic thalamus (F), and pressed upon the corpora quadrigemina (D). C. The cerebellum, divided and turned aside. E. Superior medullary velum covering the fourth ventricle (H).

Digitized by Google

On section the tumour is seen to be largely composed of blood, which is coagulated and mixed up with tracts of soft grey material, like new growth.

Beneath the microscope the constitution of the growth is a little difficult to make out; apart from blood there are strands of connective tissue, and collections of small cells with interlacing processes—an appearance very similar to that found in the normal pineal body. There are, however, in addition, alveoli full of exceedingly large and vacuolated nuclei, the bodies of the cells of which appear to have coalesced; under a low power these have somewhat of the appearance of giant-cells lying close together, but under a higher power might suggest small islets of cartilage; perhaps on the whole they are more likely to be large and rapidly proliferating cells; they are most evident close to blood canals; the latter are large and very numerous. There are also rounded spaces of considerable size, bounded more or less regularly by connective tissue, and containing an inner lining of cells of a columnar shape with bold nuclei; the cells being arranged endways like a palisade, the rest of the space being, in part at any rate, occupied by an indefinite material staining a faint purple by Van Gieson's method. Perhaps the tumour may best be described as an alveolar sarcoma with hæmorrhage and cysts.

But the spaces mentioned above, which are lined by columnar epithelium, are, I think, difficult to interpret; it is just possible that these cells may represent a rudimentary retina, to the cells of which, as depicted in some forms of pineal eye by Baldwin Spencer, they are somewhat alike; or, more probably, these spaces lined by epithelium may represent the state of the body found in birds—that of saccules, with albuminous contents, lined by epithelium.

The symptoms in this case were exceedingly interesting. The boy (F. W—) was six years old, and was in hospital for five weeks, until his death. He had been well until a few months before admission, but during these months his father noticed that he was strange in manner, was given to masturbation, and inclined to sleep a great deal.

On admission he was well nourished; his gait was staggering, but there was no paralysis anywhere; the reflexes were normal; there was no tremor; the back, especially the back of the neck, was held stiffly. His eyesight was good. The boy's penis was of large size, fully equal to that of a lad of sixteen or seventeen years; pubic hair was fairly plentiful, but the testicles did not seem enlarged.

Digitized by Google

Until his death, a few weeks later, he had frequent attacks of vomiting, and frequent fits, marked especially by opisthotonos; but the most striking symptom was sleepiness. He would sleep night and day, almost continuously, but could be easily roused by a question and slight shaking, and then would answer with perfect readiness and intelligence, but would fall asleep again if left alone.

About ten days afterwards the pupils were only slightly active to light, and were large, but variable in size; the boy saw perfectly. There was some loss of power in external rectus of the left eye.

About a week subsequently both external recti were inactive, the pupils widely dilated and inactive to light, and the boy quite blind. Although no choking of the disc was to be seen, there was slight pallor and blurring, as from optic neuritis of slight degree.

There was throughout his illness no ptosis, nor evidence that any other muscle of the eyes except the external recti was paralysed. There was never any paralysis of face or muscles of the limbs or body. There was no deafness nor loss of sense of touch. There were no pelvic symptoms, excepting some priapism.

Until death he remained in a state of continuous sleep, from which he could be easily roused. He never complained of headache when asked, but of pain in neck and back if disturbed from his rigid position. He remained quite blind, and neither eye would move outwards beyond mid-line. Vomiting was frequent, so also were fits, in one of which he died. No other fresh symptom arose. The knee-jerks, at first present, were soon absent, and remained so. There was no rise of temperature and no wasting.

Remarks.—Tumours of the pineal body appear to be very rare; hyperplasia, psammoma, and cystic degeneration, according to Ziegler, being the least uncommon.

Wilks and Moxon, in their 'Pathological Anatomy,' state that cystic disease, in their experience, is not uncommon, and apparently often unaccompanied by any symptoms.

Of tumour, two cases have been recorded in the 'Transactions' of this Society: the first by Dr. Turner, in vol. xxxvi; the second by Dr. Coats, in vol. xxxviii. The latter, besides referring to Dr. Turner's case, mentions three others, by Weigert,[1] Falkson,[2] and Ziegler.[3]

In all of these the constitution of the tumour was complex. Thus in Weigert's specimen, which he describes as a teratoma,

[1] 'Virchow's Arch.,' vol. lxv, p. 212. [2] Ibid., vol. lxxv, p. 550.

[3] Ziegler, 'Lehrbuch der path. Anat.,' 4th edit., vol. ii, p. 613.

Digitized by Google

were muscle, hair, fat, cysts, and cylindrical epithelium. In Falkson's, besides spindle-celled sarcoma, were cartilage and cysts lined by cylindrical epithelium; and Dr. Coats's example was very similar, excepting that the arrangement of cylindrical epithelium was such as to suggest glandular structures. In Ziegler's, apparently sarcoma, and again cysts lined by cylindrical epithelium. In Dr. Turner's, collections of large cells termed carcinomatous, together with sarcoma, and other cells which were regarded as polar nerve-cells.

In addition to these five I have found reference to three other cases. Dr. Duffin[1] reports a case of apparently a solitary glioma, and with symptoms somewhat similar to those of the boy narrated to-day, namely, a staggering gait, stiffness of muscles at back of the neck, drowsiness for a month, with intellect unimpaired; in addition, however, with some paralysis of third, seventh, and eighth nerves, perhaps due to pressure downwards upon the floor of the aqueduct.

Dr. Blanquinque,[2] of Laon, describes an hypertrophy of the pineal body to the size of a pigeon's egg, with hæmorrhagic extravasations and calcareous points. Fits, paraplegia, and amaurosis were present; but the clinical history is scanty.

Gutzeit[3] relates the case of a boy with a tumour of the pineal body, in part cystic, but containing also fat and muscle, both striped and unstriped. No clinical details are given.

Thus of these eight cases two may be perhaps described as hypertrophy or glioma; the remaining six are all more or less complex in composition, but most of them contain sarcoma tissue. One may remark in this connection also, in one of the specimens now being shown, the large amount of pigment in the sarcoma cells; for, although I have been unable to find pigment in the normal pineal body in man, it is very abundant in the pineal eyes of lizards—in the retinal elements, the lens, and in parts around the optic vesicle; as, of course, it is in the choroid and retina of man.

The pineal body, it is well known, appears in development as a hollow outgrowth of the posterior portion of the fore-brain, or thalamencephalon; and in some of the lower forms of animals this hollow outgrowth becomes elaborated into a structure evidently

[1] 'Clinical Society's Transactions,' vol. ix.

[2] 'Gazette hebdomadaire,' 1871; 'Lancet,' 1871.

[3] 'Inaugural Dissertation,' Königsberg, 1896.

Digitized by Google

a median eye, with a very perfect lens, retina, optic nerve, and pigment, as shown more especially by Baldwin Spencer in the case of lizards. Although no doubt functional as an eye in extinct forms, it is probably not so in any living animal; and in mammalia it exists in a very degenerate condition.

As far as one can learn from descriptions and from sections, the pineal body in man is solid, divided into loculi by fibrous partitions, holding blood-vessels; the divisions are filled with a fine reticulum holding nucleated cells of a uniform and small size, the branches of which cells appear to form the reticulum. There does not seem to be any pigment in the body.

It is not obvious that it contains any nerve-fibrils, but other modes of staining might demonstrate them if present. Nerve-fibres are, however, described in the stalk of the pineal body.

The entire structure of this body is, in appearance, exceedingly like compartments of neuroglia; but it is also very like some layers found in the grey matter of the cerebellum, the cells of which are, I believe, regarded as nerve-cells.

As far as I am aware no special nervous functions are attributed to the pineal body, although I see that extracts of it are sold, to be administered "in functional diseases of the brain due to failure of nutrition; in cerebral softening; chronic mania, and dementia."

Ferrier, however, in his book on the 'Functions of the Brain' passes it over in silence.

Neither, if one looks to its development as representing a median eye, would one expect that any nutritional changes in the body at large would be produced by disease in the pineal gland, such as apparently follow disease of the anterior lobe of the pituitary body, or of the thyroid gland; since the pineal body does not represent structures with a glandular, secretory, or excretory function, as is probably the case with the thyroid and pituitary bodies. Even in its most perfect form, as presented in lizards, no epithelial structures, properly so called, would seem to be present; although, of course, as an outgrowth from the brain it is ultimately epiblastic in origin.

The cases now related do not, I am afraid, throw much light upon the question (if it be a question) whether the pineal body possesses in man any special function.

As regards the woman, there was such wide-spread growth that any symptoms referable to the tumour of the pineal body would

Digitized by Google

be obscured by the general or diffuse symptoms present; and the earlier part of the history is very defective.

As regards the boy, where growth was limited to the pineal region the symptoms were, no doubt, for the most part due to pressure on adjacent structures, and more especially on the corpora quadrigemina.

Ferrier's experiment of destroying just the surface of the superior tubercles of the corpora quadrigemina in monkeys resulted in total blindness, dilated and inactive pupils, without ptosis; there was perfect sensation, no paralysis of the body, but an entire inability to maintain a normal equilibrium, or to move steadily. All these were prominent symptoms in the boy. His blindness was of exceedingly rapid onset, and accompanied by very slight change in the fundus of the eye, thus suggesting interference with sight tracts or centres; moreover, there was no pupil reaction to light.

There was apparently no paralysis of the third nerve, as far as could be ascertained, and certainly no ptosis, but the movement outwards of either eyeball was not possible.

Perhaps one may account for this as a loss of the "conjugate movement" of the two eyes, the path for which, from the cortex to the nucleus of the sixth nerve, according to Gowers, traverses the corpora quadrigemina. It could, I think, hardly be due to direct pressure on the sixth nerve, or its nucleus, on each side, seeing that the third and the seventh were normally active, and that there was no interference with the pyramidal tracts.

Two, however, of the symptoms in the boy's case appear, to some degree, unaccounted for—the continuous sleep, and the precocious development and enlargement of the penis. The latter presented a very striking and even embarrassing appearance in one so young. And the enlargement of what may be described as an extremity, in conjunction with the general symptoms of an intra-cranial tumour, with also the blindness and interference with eye muscles, led me to suggest, during life, a diagnosis of tumour of the pituitary body.

The sleepiness could in no sense be called coma; the boy could be easily roused from it, and was then perfectly intelligent.

As regards the former of these two symptoms, I have not seen any notice in the records of those cases of pineal tumour where details of clinical history have been given, of any special nutritional

Digitized by Google

changes in the general body ;[1] but, as regards the other symptom, I find that in Dr. Coats's case sleepiness was present, and lasted for several months; and drowsiness for a month is mentioned in Dr. Duffin's case. Perhaps this symptom might prove to be of value in the localisation of pineal tumour, although it may not be directly due to disease of the pineal body, but rather to the position of the growth and interference with surrounding structures. *December 6th*, 1898.

---

3. *Tumour of the pineal body.*

By T. W. P. Lawrence.

The specimen consists of the medulla oblongata, pons, and part of the mid-brain, with the pineal body, from a boy who died of tuberculous meningitis. The pineal body is enlarged to several times its normal size, and is somewhat altered in shape. Its outline, viewed from above, is almost circular, and its diameters measure 14 mm.; the organ is compressed from above downwards, and measures in this direction 7 mm. The central part of the upper aspect is slightly depressed over an area measuring 6 mm. across, presenting an umbilicated appearance. The under aspect is nearly flat. The circular margin is broad and rounded. Both surfaces and margin are smooth, and present evidences of slight lobulation. The organ is free from adhesion to surrounding parts, and presents nothing abnormal as regards its colour. On cutting into it, it was found to be soft, solid, and free from brain-sand. A portion was removed for microscopic purposes from the upper part of the organ, along the median plane, but not quite including the whole thickness of the organ.

Under the microscope two main zones are distinguishable, a narrow one lying at the periphery of the organ, and a central one including the larger portion of the section. The peripheral zone is broadest at the anterior part of the organ, and is composed of

[1] Bearing on this question, the following case has subsequently been recorded by Heubner ('Allg. med. Central. Zeitung,' An. 28, S. 89). In a boy aged four and a half, the penis, scrotum, and testes were abnormally large, and the pubic hair fully grown. Growth had proceeded normally until he was seven and a half months old. The excessive growth took place in one year. There were, at the same time, slightly choked discs, and symptoms of paralysis. *Post mortem* a tumour of the pineal gland was found.

Digitized by Google

cells of considerable size closely aggregated together in parts, and having large oval and deeply staining nuclei, but the outlines of the cells are indistinct owing to degeneration of their protoplasm. The cells of this layer are evidently *pineal cells*. The central zone of the section is composed of finely granular material, staining slightly. The masses of granules, evidently products of degeneration, are disposed in a somewhat reticulate fashion, and an open network of delicate connective-tissue fibres is seen traversing them in many parts of the section. No cells or cell nuclei are present in this zone, which doubtless consists of the remains of a tissue which by its degeneration and shrinking has produced the umbilication of the upper surface of the pineal body. Between these two zones there is towards the anterior end of the organ a third zone, consisting of a well-staining tissue, composed of a close network of very delicate interlacing fibrils and scattered cells of small size, round or triangular in shape, with scanty protoplasm and round and deeply staining nuclei. This layer appears to be closely connected with the central degenerated portion on the one hand, and on the other hand it is not sharply marked off from the pineal tissue of the periphery, but is prolonged into the latter, and divides it up into distinct areas. From the histological characters of this third zone it is concluded that the enlargement of the organ is due to a gliomatous growth, and that the central part of the tumour has undergone degeneration.

The patient, a boy aged 16, was under the care of Dr. Bradford in University College Hospital. His illness commenced with a cough, which, however, improved, but was succeeded by pains in the head, which commenced ten days before death. Pain in the chest and abdomen set in soon after, and vomiting was present during the last four days of the illness. Delirium commenced three days before death. On admission to the hospital on the day previous to his death the patient was semi-conscious, with face flushed; very irritable and crying out on being moved. Breathing was heavy; respirations 28 in the minute. The pulse was slow and full. The pupils were widely dilated, and did not react to light. Strabismus was present at intervals. There was total blurring of the right optic disc, with large and tortuous veins; the left disc was affected on the inner side only. The limbs were in constant movement of an athetotic character, but there were no convulsions. The abdomen was moderately distended. A few

Digitized by Google

hours before death the patient became completely comatose, and the breathing stertorous. Resp. 48; pulse 136 and regular. Great rigidity of the back muscles was present. The temperature ranged from 102·2° to 105°. There was nothing noteworthy in the family history and general history of the patient. Up to the time of the present trouble he had had good health, and was free from illnesses.

Post-mortem examination.—The veins on the surface of the brain were distended, and the cerebral ventricles were very full of clear fluid. A small patch of purulent matter was present over the margin of one parietal lobe, and there was pus in small amount on the upper surface of the cerebellum. The velum interpositum and the adjacent part of the membranes covering the cerebellum were much thickened by a deposit of inflammatory exudation, but the pineal body was not involved. Purulent matter was present over the base of the brain from the optic nerves backwards, and extended into the Sylvian fissures, where discrete tubercles could be distinguished.

The left lung was universally adherent; two or three small infarcts were present in the right lung. No tubercles were present in either lung. Some of the bronchial glands were caseous. The mesenteric glands were healthy. The heart was healthy. The right kidney was completely atrophied; the left healthy, and weighing 7½ oz. The liver was universally adherent. The spleen was healthy except for the presence of two or three tubercles on its surface. *December 6th*, 1898.

---

4. *Pineal cyst.*

By A. E. Garrod, M.D.

The specimen shown is a portion of the brain of a boy aged 16, who died of diabetes.

At the *post-mortem* examination, which was made thirty-five hours after death, a small cyst, as large as a pea, was found in the pineal body. The walls of the cavity were smooth, and had a yellowish tint. No hæmatoidin crystals were found in the cavity. The fourth ventricle and the rest of the brain appeared natural.

The pancreas was unduly small, and was found, on microscopical examination, to be markedly fibrotic.

Digitized by Google

The liver and kidneys were fatty.

It seemed possible that the pineal cyst was of a similar nature to those which are described as occurring in other parts of the brain in cases of diabetes; but its close resemblance to pineal cysts found in other than diabetic patients throws doubt upon this view. *December 6th*, 1898.

---

5. *Cysts of the pineal body.*

By A. E. Russell, M.D.

1. The patient in whom this cyst was discovered was admitted in a comatose condition, from a fractured base of skull, into St. Thomas's Hospital in September, 1898, under Mr. Anderson's care. He was twenty-three years old. *Post mortem* the pineal body was found to be distended into a thin-walled cyst five eighths of an inch in diameter. The cyst contained clear albuminous fluid. At its attached portion the wall was opaque, but at the free extremity the wall was so thin as to be translucent. No other lesion was present. Careful inquiry among his relatives failed to elicit any symptoms referable to the condition.

2. Specimen from the museum, St. Thomas's Hospital.[1] In this specimen the pineal body was converted into a cyst of about a third of an inch in diameter, the wall of which contained much earthy substance. The cavity was filled with clear and amorphous granular material. No clinical record. *December 6th*, 1898.

---

6. *Notes of two cases of dilatation of the central cavity or ventricle of the pineal gland.*[2]

By A. W. Campbell, M.D.

Case 1.—The patient was a female epileptic aged 33, who died of phthisis. There was no noteworthy lesion in the brain, and it was one of average development, but the pineal gland was

[1] No. 2030.

[2] Both these cases occurred in Rainhill Asylum.

Digitized by Google

strikingly enlarged, measuring 10 mm. in the transverse direction, 13 mm. in the sagittal direction, and 8 mm. in depth; its general shape was round, but it was pointed posteriorly.

The whole body was hardened in formalin 5 per cent. and then in alcohol, and after embedding in celloidin serial sections were made in the vertico-sagittal direction. Every section was mounted and stained by the method of Van Gieson or with toluidin blue.

The sections showed that the enlargement of the gland was due to a remarkable cyst-like dilatation of its central cavity or ventricle. The cavity was situated more or less centrally; it contained glairy brownish fluid, had a brown lining, was of ovoid form, and its diameter was 8 mm. in the horizontal direction and 6 mm. in the vertical direction. The wall of this cavity varied in thickness between 1·5 and 2·5 mm., being thickest posteriorly; to the naked eye it seemed to possess the brown-pink colour of the normal gland, but microscopically it could be resolved into two layers. The outer of these layers was on the whole thinner than the inner, and was composed of the cellular substance of the normal pineal body, the groups of cells being separated into islets by septa of pia mater. It stained deeply with hæmatoxylin, and in it corpora arenacea—sometimes simple, sometimes compound—were scattered.

The composition of the inner layer was very different from that of the outer, but as it stained indistinctly it was difficult to determine its precise nature. However, close examination under a well-illumined oil-immersion lens revealed the presence of numbers of large, very pale, or faintly granular cells of round or oval form, few of which contained a nucleus, and then only a comparatively small faintly stained one. Similar cells, but of flattened form, could be seen in places along the inner lining of the cavity. What the exact nature of these cells is I am not prepared to say.

Then scattered all over the field in this inner layer were large cells or bodies of varying shape, some irregular, some round, some oval, which were filled with coarsely granular dark brown pigment, and in some of these one or more nuclei could be clearly seen.

Lastly, the most remarkable feature of the sections was the existence of a dense collection of these pigmented bodies, situated on the inner lining of the cavity and projecting slightly into it at its posterior extremity, the pigmented bodies being arranged in strata.

In regard to the nature of these bodies, it is possible that they

Digitized by Google

FIG. 3.

FIG. 5.

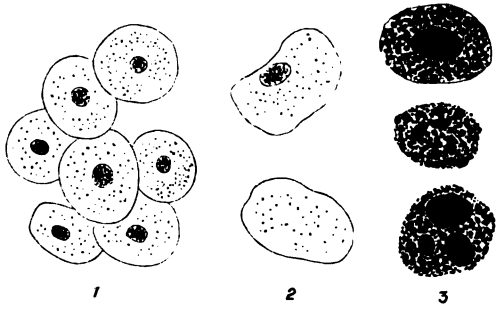

FIG. 4.

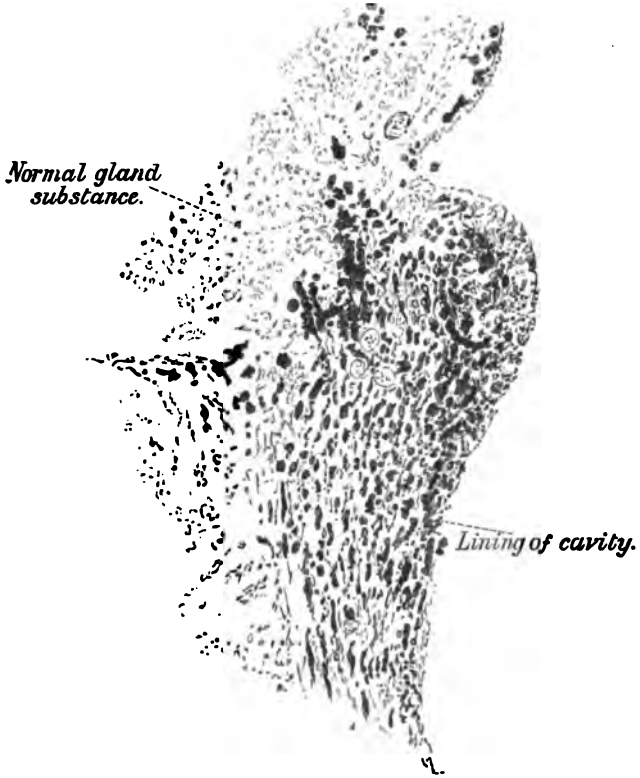

FIG. 3.—Dilatation of central cavity of pineal gland. Natural size. The upper two drawings show the cavity laid open. The lower two show the outer surface of the pineal body.

FIG. 4.—Collection of pigment on inner wall of cavity of pineal gland.

FIG. 5.—1. Collection of cells seen on the inner surface of wall of the cavity 2. Cells seen in the substance of the inner layer of the wall. 3. Pigmented bodies or cells seen in inner layer of wall.

Digitized by Google

are merely collections of hæmatoidin crystals which have become darkened by age, or, on the contrary, they may be pigmented cells analogous to those usually present in the choroid and retina of the eye. I believe that the latter assumption is the correct one, and if it be so, it is a proof that the pineal gland is really a rudimentary organ of sight, and it will also explain the origin of a primary melanotic sarcoma in that body.

Case 2.—The second specimen was also taken from the brain of an epileptic female. To the naked eye it was similar in all respects to the above, but the enlargement of the cavity was somewhat greater. Unfortunately it was not submitted to microscopic examination.

I have recently obtained a third similar specimen, but have not had time to examine it.

I would add that these notes have been hurriedly put together for this meeting, and that my observations on this pineal change are far from complete. *December 6th*, 1898.

---

7. *The pineal gland; its normal structure; some general remarks on its pathology; a case of syphilitic enlargement.*

By John R. Lord, M.B., introduced by Mr. Beadles.

The pineal gland is a portion of the brain of exceptional interest, and it is the intention of this paper to describe the normal naked-eye and microscopical features and one pathological departure. Without entering into details, the following points appear to me to sum up the present position of our knowledge in general, as regards the pineal gland in health and disease.

1. The pineal gland or *epiphysis cerebri* is a rudimentary structure, and is developmentally the representative of the median eye present in some animals (Anguis, Hatteria, &c.).

2. It is functionless in man.

3. Being in man a useless, decaying structure, its normal condition is always more or less a pathological one.

4. It has, *per se*, pathological potentialities, mainly of two kinds:

Digitized by Google

(*a*) New growth, from the presence of cells of an embryonic nature.

(*b*) The degenerative processes constantly present may become unduly active and exaggerated, and may result in cystic disease, &c.

5. It may be affected *pari passu* by morbid conditions affecting the brain generally.

6. When actively diseased its symptoms are those which result from pressure on the surrounding parts.

Normal structure: A. The pineal gland is divided into a number of loculi by an irregular network of septa. These septa are composed of small fibres (like white fibrous tissue), in the midst of which are scattered spindle and oval cells. This tissue is in part derived from the two pineal peduncles and partly from the pial investment, the latter supplying small blood-vessels and lymphatics. The loculi have no endothelial lining. They contain a stroma of fine fibres which appear to be the processes of small branching cells similar to those found in adenoid tissue. In this meshwork are crowded cells of various shapes, some of which are pale, others being filled with granules. There is also a ground substance of some gelatinous material which stains faintly, and in which can be seen the *débris* of cells which have broken down.

B. The following changes occur normally:

1. *Calcification of septa.*—This usually occurs centrally and towards the apex, and gives origin to the so-called "brain sand." Lime crystals can be seen in the septa in other parts of the gland.

2. *Formation of amyloid bodies.*—In some of the loculi, usually near the apex, the granular cells undergo a process of amyloid degeneration, the granules swelling up and forming a pale yellow material. The cells so affected unite together and form a nodular body of a pale yellow colour which fills the loculus. These amyloid bodies take on the aniline stains readily.

C. "A normal cavity." A normal cavity in the pineal gland has been described. Its existence, however, is much to be doubted. The only cavity I have found is that produced by the calcification of the septa, and the subsequent union of the loculi. There may be one large cavity or several small ones. Such, however, cannot be considered normal in the ordinary sense of the word; it is a condition produced by a process of degeneration.

Digitized by Google

Variation in shape and size.

The normal pineal gland is commonly conical in shape. When it enlarges it expands in the direction of the least resistance, which is posteriorly and laterally. When only moderately enlarged it becomes heart-shaped, but when greatly enlarged it is the shape of a broad spade.

The actual size varies very much, and does not depend upon the size of the whole brain. The following dimensions are based upon the measurement of a number of glands which could be considered normal:

Length	5—9 mm.
Breadth	3—8 „
Thickness	2—4 „

A case of syphilitic enlargement.

In this case the dimensions of the gland were—

Length	21 mm.
Breadth	16 „
Thickness	9 „

Its pial investment was congested and œdematous, and in its substance were two large calcareous nodules. Microscopically considerable alteration had occurred in its structure. There was a vast increase in the number of cellular elements in the septa, and also a formation of new septa, the latter dividing the gland up into extremely small loculi. In some places the loculi seemed actually obliterated. These cells stained deeply, and each had a large nucleus. The condition appeared to be a hypertrophic cirrhosis.

Clinically the case presented no symptoms which could definitely be put down to the morbid condition of the pineal gland. She was a woman who had been insane for some seven years, having during that time recurring epileptiform convulsions and fits of violence. She eventually became paralysed on the left side, the paralysis afterwards affecting the right leg. For some time before her death she was very demented and in a state of partial stupor. The stupor, however, cannot definitely be put down to the pineal condition, because it is so common a symptom of advanced cerebral disease. *Post mortem* a growth was found in the right central

Digitized by Google

region of cerebrum, a second one being situated at the tip of the occipital lobe on the left side.

A microscopical examination of the growths confirmed the previous diagnosis of gummata. There was degeneration of the pyramidal tracts in the cord. *December 6th*, 1898.

---

8. *Sarcomata involving the spinal cord of a child aged three years.* (*Card specimen.*)

By F. E. Batten, M.D.

The child first came under observation in November, 1897, with a sore on the lower part of the back, and a history of weakness in the legs of three months' duration. Six months later the child was completely paralysed in the lower limbs, which were rigid in the flexed position; the knee-jerks were present, no ankle-clonus could be elicited, and the plantar reflexes were absent; there was loss of sensation to the level of the fifth rib, and the intercostals were paralysed below this level. There was a small growth lying to the left of the spine at the level of the fifth dorsal vertebra. The child died three months later, the knee-jerks not being obtained during the last fourteen days of life.

At the autopsy a large mass of growth was found to the left of the bodies of the vertebræ in the dorsal region; it had extended into the spinal canal and involved the dura mater and the cord to the most marked degree at the level of the fifth and sixth dorsal vertebræ; the growth, however, extended up to the third cervical segment, and below to the level of the eighth dorsal. There were masses of growth in the dura mater, and these had caused erosion of the skull; another growth was found in the right femur, the primary growth being that in the thorax.

On microscopical examination the growth proved to be a small round-celled sarcoma. There was almost complete destruction of the cord in the mid-dorsal region, but under the microscope a few myelinated fibres could be seen; there was considerable destruction of the cord up to the level of the fifth cervical root, above which there were the usual ascending degenerations; below the level of the lesion there was considerable myelitis, giving rise to destruction of the peripheral portion of the cord. *May 2nd*, 1899.

Digitized by Google

9. *Further evidence on the pathology of diphtheritic paralysis.*

By Frederick E. Batten, M.D.

[With Plate II.]

While examining pathologically certain cases of diphtheritic paralysis, the results of which were read before the British Medical Association in July, 1898, and were published in the 'British Medical Journal' under the title of "The Pathology of Diphtherial Paralysis,"[1] I was struck by the fact that although the pathological change found in the nerves was definite and marked in nearly all cases of long standing, yet in one case, a child aged four years, in whom the disease had existed fifty days, no change could be demonstrated in the nerves. I determined, therefore, to continue to examine pathologically all cases of diphtheritic paralysis that I could obtain, and since that date I have, thanks to the kindness of Dr. Bastian, Sir Dyce Duckworth, Dr. Hensley, and Dr. Penrose, been able to examine five cases.

Method of examination.—The same methods have been used as in the previous series of cases, viz. Nissl's method, Marchi's method, and Pal's method, but in addition to these the nerves have been examined by Stroebe's method for staining axis-cylinders.

Nature of changes found:

Nissl's method.—Three of the cases were examined by this method; in one case (No. 3) all the cells of the anterior horn appeared perfectly normal; in the second case (No. 1) only one abnormal cell could be found in the cervical region, the cell having become swollen, the nucleus eccentric, the chromophilic substance displaced to the periphery, and the protoplasm of the cell finely granular (fig. 1); all the other cells stained normally and well. In case No. 2 there were some very definite alterations in the cells of the anterior horn, the cells being shrunken, pigmented, the chromophilic substances staining badly, and the processes of the cell indistinct; the nucleus, however, in most of the cells had not become eccentric; the changes, therefore, are for the most part not in the Nissl bodies, but rather in the shape and pigmentation of the cell. Pigmentation of the cell has little pathological signifi-

[1] 'Brit. Med. Journ.,' November 19th, 1898.

Digitized by Google

Digitized by Google

DESCRIPTION OF PLATE II,

Illustrating Dr. Frederick E. Batten's paper "On the Pathology of Diphtheritic Paralysis." (Page 22.)

FIG. 1.—Cells of the anterior horn at the level of the fifth cervical root from a case of diphtheritic paralysis, in which death occurred on the fifty-eighth day of the disease. Four cells are shown: three are of normal appearance; the fourth is seen to be swollen, globular in shape, the chromophilic material lying to the periphery, while the cell body is finely granular, with an indistinct nucleus becoming eccentric in position, and tending to become extruded from the cell. No change can be seen in the nucleolus.

Stained by Nissl's method.

FIG. 2.—Longitudinal section through the left phrenic nerve of the same case to show the characteristic changes which take place in the myelin sheath. It will be seen that only certain of the fibres are affected; the sheath of the nerve is somewhat swollen, and occupied by fine black granules in parts. Where the degeneration is more advanced these fine granules have passed into larger fat globules.

Stained by Marchi's method.

Digitized by Google

Digitized by Google

...ATE II.

... 's paper "On the Pathology ...

... level of the fifth cervical ... lay ... of normal appearance ; the ... the ... granular, with an indistinct ... extruded from the ...

Stained by Nissl's method.

... through the left ... nerve of the same case ... changes which take place in the myelin sheath. It ... certain of the fibres are ... the sheath of the nerve ... by ... granules in parts. Where ... have passed into larger fat ...

... 's method.

Digitized by Google



Fig. 2

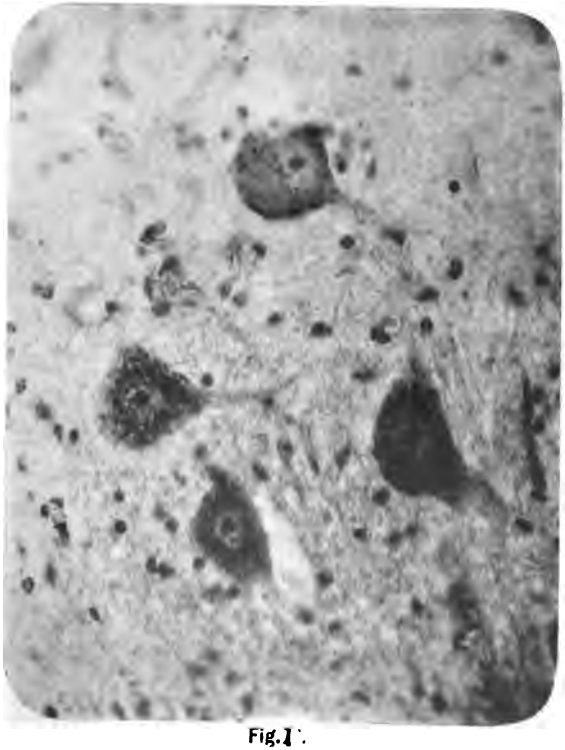

Fig. 1.

Digitized by Google

Digitized by Google

cance, inasmuch as it is always present in the cells of old persons; and with regard to the other changes it must be borne in mind that the cord was removed from the body of a patient, who died of septic pneumonia, some thirty hours after death.

With regard to the condition of the cell my attention has been called to a very interesting paper published by Dr. Sharkey[1] in 'Brain,' 1890, on a case of diphtheritic paralysis, in which he figures the nerve-cells of the anterior horn stained by logwood. The cells as figured resemble a perfectly healthy cell as stained by Nissl's method. No lesion was found in any other portion of the body, and it is suggested that the changes observed in the motor cells were the result of the diphtheria poison.

Marchi's method.—The characteristic changes (Fig. 2), viz. the swelling of the myelin sheath with deposit of fat globules, and later the breaking up into oval masses, which I have recently described, were found in the nerves, anterior and posterior nerve-roots of all the cases except No. 3, in which no change could be found, and in which the changes in the cells of the anterior horn above described were found. The changes were not limited to the nerves of the trunk, but affected also certain of the cranial nerves, being most marked in the third, fourth, and sixth, and in that portion of the fifth that contains the large fibres; the optic and the auditory nerve I have never found affected. The amount of change in the parts examined varies to a very considerable degree, in one case the peripheral nerves, in another the anterior roots, in another the posterior being most affected.

Pal's method.—By this method the nerves appear to be perfectly normal.

Stroebe's method.—By this method the axis-cylinders have been stained; so far as can be seen no change has taken place in them, but as an osmic acid preparation of the nerve will not stain satisfactorily by Stroebe's method, it is difficult to say whether there may not be some affection of the axis-cylinder at a point where alteration of the myelin sheath has taken place.

Conclusions.—Five cases have been examined; four of these exhibit the characteristic changes in the nerves or roots, while in only one were these absent. Changes in the anterior horn cells have been noted in two cases; in one of these, however, only a single altered cell was found, and in the other the cause of death and the interval

[1] 'Brain,' vol. xiii, p. 237, 1890.

Digitized by Google

between death and *post-mortem* is too great to allow one to accept this case without hesitation, and I can only repeat the conclusion of my former paper, viz. that the dominant lesion in diphtheritic paralysis is a parenchymatous degeneration of the myelin sheath or the nerves, although one must always be prepared to find a certain proportion of cases which give a negative result. It seems almost certain that a general poison like that of diphtheria must act on the whole neuron, and what I have endeavoured to show is that the effect of the poison manifests itself (at least in fatal cases) in the myelin sheath and not in the cell body.

Appendix.

Cases.—1. Girl aged 11 months, duration of disease fifty-eight days. 2. Woman aged 28 years, eighty days. 3. Boy aged 4 years, forty days. 4. Boy aged 2¾ years, uncertain. 5. Girl aged 5 years, forty-five days.

Parts examined.—Cranial nerves, spinal cord, anterior and posterior nerve-roots, vagus and phrenic, nerves to the upper extremity, nerves to the lower extremity.

Methods of examination.—1. Nissl's method; 2. Marchi's method; 3. Pal's method; 4. Stroebe's method.

Case 1.—D. G—, aged 11 months, was admitted to St. Bartholomew's Hospital, under the care of Dr. Hensley, to whom I am indebted for the notes of the case. She was taken ill six weeks previously with croup and bronchitis, she had difficulty in breathing for fourteen days, and had not been quite well since. Three weeks later the child began to have regurgitation of fluid through the nose. On admission the child had a feeble cry, the diaphragm acted very badly, and on attempting to drink milk regurgitated through the nose, the soft palate was paralysed, and the limbs were flaccid and wanting in tone. The knee-jerks were absent. Urine contained a trace of albumen. The child lived for sixteen days after admission to the hospital, and then died suddenly. At the autopsy some collapse and broncho-pneumonia of the lungs were found, the other organs appearing normal.

Pathological examination.—(1) Nissl's method. Only one abnormal cell could be found by this method in the cervical region, all the other cells appearing normal (fig. 1).

(2) Marchi's method. Cranial nerves: degeneration in the

Digitized by Google

third, fourth, fifth, and sixth nerves was found to a variable extent. Spinal cord: no change could be found. Spinal roots: changes were present in the anterior and posterior roots, but were more marked in the anterior than in the posterior, and in the cervical than in other regions of the cord. Peripheral nerves: changes were present in the vagi, phrenics, the anterior crural nerves, and in the brachial plexus, the changes being most marked in the phrenics (fig. 2).

(3) Pal's method. By this method all the parts above examined appeared normal, or the changes were so slight that no pathological significance could be attached to them.

(4) Stroebe's method. No alteration in the axis-cylinders could be demonstrated by this method.

Case 2.—M. J—, aged 28 years, was admitted to St. George's Hospital, under the care of Dr. Penrose, to whom I am indebted for the notes of the case. The history of the case was as follows :—Six weeks previous to admission she had diphtheria, and was in bed for fourteen days. About ten days later she noticed weakness in the feet and legs; this disappeared, but soon after the patient became hoarse and unable to swallow, fluid regurgitating through the nose. Weakness of her legs again occurred, and the right arm also became affected. Her eyesight was also affected for a short time.

On admission, September 19th, 1898, no marked paralysis was present, there was some loss of sensation in the extremities, and the knee-jerks were absent.

September 25th.—The diaphragm and intercostals were partially paralysed, regurgitation of food had taken place through the nose, and there was more dyspnœa. During the next month, although the condition of the diaphragm improved, the patient developed signs of bronchitis and pneumonia, and died on October 27th of septic pneumonia, an abscess cavity being found in the right lung.

Pathological examination.—(1) Nissl's method. By this method considerable change could be seen in the cells of the anterior horn; the cells were for the most part shrunken, the chromophilic substance was altered, and there was a very considerable amount of pigment in the cell, but the nucleus was, as a rule, centrally placed in the cell, though it was by no means always well stained. The changes are rather more marked in the cervical than in the lumbar region.

Digitized by Google

(2) Marchi's method. By this method no change could be demonstrated either in the cord, anterior or posterior roots, or in the peripheral nerves.

(3) Pal's method. No change could be demonstrated in the parts examined by this method.

(4) Stroebe's method. The root-fibres and the peripheral nerves examined by this method appeared perfectly normal.

CASE 3.—R. G—, aged 4, was admitted to St. George's Hospital under the care of Dr. Penrose, to whom I am indebted for the notes of the case.

The child was admitted on September 17th, 1898, with the history of having had a sore throat for two days; tracheotomy was performed, and the child progressed favourably and was apparently well on October 11th. A few days later regurgitation of fluid through the nose was noticed, bronchitis developed, and the child becoming gradually weaker, died on October 24th.

Pathological examination.—(1) Nissl's method. The cells of the anterior horn appeared to be perfectly normal.

(2) Marchi's method. Spinal cord: no change could be found in the spinal cord by this method. Spinal roots: the characteristic changes were fairly marked in the cervical and lumbar regions of both the anterior and posterior roots; in the dorsal region the changes were less marked. The peripheral nerves of this case were not preserved.

CASE 4.—M. S—, aged $2\frac{3}{4}$ years, was admitted to St. Bartholomew's Hospital, under the care of Sir Dyce Duckworth, to whom I am indebted for the notes of the case. The onset of his illness was indefinite, as he had not been well since measles, six months previously. On June 27th, however, he suddenly lost power in his legs; on July 4th, fluid regurgitated through the nose.

On admission his legs were flaccid, his diaphragm was acting very feebly, and his knee-jerks were absent. He had several attacks of dyspnœa. He died on July 9th. The autopsy showed some broncho-pneumonia and deposit of tubercle in the right lung.

Pathological examination.—The nerves only were examined in this case; the anterior tibial and the vagus showed change to

Digitized by Google

a moderate degree, while the changes in the phrenic were very marked.

Case 5.—M. P—, aged 5 years, was admitted to the National Hospital under the care of Dr. Bastian, to whom I am indebted for the notes of the case, with the history that she had been well till seven weeks previously, when she had a bad throat lasting about three weeks, and had been very weak ever since. During the last two weeks she had had difficulty in swallowing and had had some regurgitation of fluid, and her articulation had been thick and indistinct. On admission the voice was nasal, pupils were dilated and reacted badly to light, together with slight double ptosis. The legs were flaccid and the knee-jerks absent; the diaphragm acted feebly. The child died three days after admission.

Pathological examination.—(1) Nissl's method. Omitted.

(2) Marchi's method. Spinal cord: no alteration could be found. Spinal roots: changes are present to a very slight degree in both the anterior and posterior. Peripheral nerves: changes were present in the anterior crural, vagus, and phrenic nerves, but were much more marked in the phrenic than in the other two.

(3) Pal's method. By this method the cord, roots, and peripheral nerves appeared to be perfectly normal.

(4) Stroebe's method. By this method the axis-cylinders appeared normal. *May 2nd*, 1899.

---

10. *Neuroma of brachial plexus, with molluscum fibrosum of skin.*

By T. Carwardine, M.S.

O. C—, aged 25, was seen in consultation for a tumour at the root of the neck on the left side, about the size of a duck's egg, nodular, moveable, tender, and non-adherent to the skin. It extended deeply under the sterno-mastoid and clavicle. It was first noticed three or four months before, and had gradually grown so as to become painful and inconvenient. About seven weeks previously the patient had what he called a strain at the heart, temporarily followed by sharp pains in the chest.

All over the body, but chiefly about the trunk, he had numerous

Digitized by Google

nodules, many with comedones and minute venules upon them, some discoid and subcutaneous and some pedunculated. They

FIG. 6.

Neuroma of brachial plexus with molluscum fibrosum.

varied in size from that of a hemp seed to a hazel nut. Upon the right buttock was a large pendulous fibroma. Several large, brownish, pigmented patches of irregular oval form and sharp outline were present about the trunk,[1] and there was a general dusky appearance of the whole skin resembling that of early Addison's disease, besides a multitude of small brown freckles.

There were nodules on the skin as long as the patient could remember. In the usual glandular regions, and simulating enlarged glands very closely, were deeply-seated nodules, which were probably neuromata, particularly in the apices of both axillæ, in the groins, and about two inches above the right internal condyle.

The cervical tumour was exposed by operation, and when isolated proved to have deep attachments to the spine above and beneath the clavicle below. A longitudinal incision was therefore made,

[1] See Wickham, 'Brit. Journ. of Dermatology,' 1890, p. 151.

Digitized by Google

and the tumour enucleated from what proved to be the outer cord of the brachial plexus, the fibres of which were expanded over the tumour, in parts very thinly so. The wound healed well; there was no anæsthesia, but slight transient paresis of the deltoid resulted.

On microscopical examination the neuroma presented the usual appearance of a soft cellular fibroma.

The family history is thus represented:

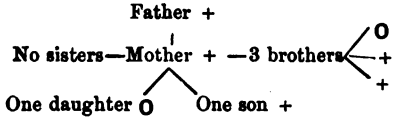

(The mark + signifies those affected with molluscum fibrosum.)

REFERENCES.

1. *Atkinson.*—'New York Med. Journ.,' December, 1875.
2. *Von Recklinghausen.*—'Ueber die Multiplen Fibrome der Haut,' Berlin, 1882.
3. *Payne.*—'Path. Soc. Trans.,' vol. xxxviii, p. 69 (two plates); also 'Clin. Trans.,' vol. xxii, 1889, p. 189.
4. *Smith* (quoted by Payne).—'Treatise on Pathology, &c., of Neuroma,' Dublin, 1849.

The references to uncomplicated molluscum fibrosum in the 'Pathological Society's Transactions' and elsewhere are numerous, and many are quoted in Crocker's 'Diseases of the Skin,' London, 1893, p. 587.

January 17*th*, 1899.

Digitized by Google

II. DISEASES, ETC., OF THE ORGANS OF RESPIRATION.

1. *Case of ulcer of the trachea, involving the left recurrent laryngeal nerve, and perforating into the aorta.* (*Card specimen.*)

By Norman Dalton, M.D.

A man, aged 35, brought into King's College Hospital dead from hæmoptysis. In the wall of the trachea, on the left side, about one inch above the bifurcation, there was an oval hole about the size of an almond. The edges were smooth and a little thick, especially at the upper end. The cartilages had completely disappeared at this opening, and it led into a small cavity with irregular walls.

The aorta was atheromatous. At a point just below the orifice of the innominate artery and on the right side of the tube there was a portion of the aortic wall, about the area of a sixpenny piece, which was very thin, and had a slight aneurysmal bulge outwards. This was not, however, a true aneurysm, but a bulge formed by weakening of the outer wall of the aorta at that spot, because part of the floor of the ulcer in the trachea was situated just outside the bulge, and was thus undermining it. A small perforation was found between the ulcer and the aorta, and this was the cause of the fatal hæmorrhage.

Although no scar was found on the penis, the tracheal ulcer was probably syphilitic. The tongue looked syphilitic, and in other parts of the mucous membrane of the trachea there were small, slightly raised patches like syphilitic plaques. Microscopically one of these plaques was found to consist of three mucous glands, not distended by mucus, but with the walls of their acini infiltrated by leucocytes to such an extent that the acini were compressed. There was, in fact, a subacute interstitial inflammation of the

Digitized by Google

gland. The central part of the plaque (both gland-tissue and leucocytes) was necrotic. The tissues around the plaque were also infiltrated with leucocytes. Over the plaque the epithelium was practically absent, but to the naked eye it did not look like an ulcer.

One of the patient's friends said that the dead man had been undergoing treatment for paralysis of the larynx, and the left recurrent laryngeal nerve could be traced as far as the outer wall of the tracheal ulcer, where it became lost. *March 21st*, 1899.

---

2. *A case of pressure on the recurrent laryngeal nerves by calcareous glands, with anthracosis of the lungs.* (*Card specimen.*)

By Norman Dalton, M.D.

The patient, a man aged 73, a clay pipe maker, was under treatment for paralysis of the left recurrent laryngeal nerve. The right recurrent became affected also, and tracheotomy was performed, but death followed soon after.

Between the arch of the aorta and the trachea there was a dense fibro-calcareous mass. It was partly composed of lymphatic glands, which were calcareous and black. Into this mass the left recurrent laryngeal nerve entered, but it could not be traced through the gland. On the right side of the trachea numerous smaller calcareous glands were found, and in one of these the right recurrent laryngeal was involved.

In both lungs there were large solid areas, which were very hard and quite black. In some of these areas there were cavities with rough walls, like tuberculous cavities. Inside the cavities there was an opaque, muddy-looking black fluid, which had no gangrenous odour. It looked like a mixture of finely-divided carbon and thin mucus. Microscopically no tubercles were found in the lung.

The man had never been a miner, and the question arose as to whether the anthracosis of the lungs and the calcification of the glands could have been due to his occupation, that of making clay pipes. I inquired of his widow, who told me that he only worked in wet clay, from which he could inhale no particles, but that he

Digitized by Google

complained much of the dust in the work-room, especially when the room was swept. She also said that his clothes were always covered by dust. He also seems to have complained of a smell of sulphur when the pipes were baked.

Mr. Herbert Jackson, the senior demonstrator of chemistry in King's College, London, was so good as to analyse the glands for me. He says that the black matter is undoubtedly carbon. The question of sulphur led him to examine particularly for iron, and he says that iron will only account for one-tenth of the blackness. He found that the calcareous matter consisted of 50 per cent. of calcium carbonate, and that the remainder was made up of alumina and silicate of alumina. He thinks that this large amount of alumina and silica indicates that the particles in the glands were derived from the clay with which the man worked. As he was seventy-three years old, he had plenty of time in which to absorb such large quantities. *March 21st*, 1899.

---

3. *Transverse fracture of the cartilaginous portion of the trachea.* (*Card specimen.*)

By W. S. Lazarus-Barlow, M.D.

The specimen was taken from the body of a man aged 73, who was the subject of the following accident:—While looking down the well of a lift the car descended from above, forced his head downwards against his thorax, and over the rail over which he was looking. The patient was very collapsed when admitted into hospital, but nevertheless lived thirteen days, ultimately dying with hypostatic pneumonia. At the autopsy it was found that there was a fracture of the sternum at the junction of the manubrium with gladiolus, a fracture of the third right rib, separation of the second and third ribs from their respective cartilages, and the fracture of the trachea now shown. The cartilaginous portion of the trachea 2¼ inches below the rima glottidis is the seat of a clean fracture which passes between two contiguous rings, and extends backwards to the muscular portion, which was unaffected. The soft tissues in the neighbourhood gave little or no evidence of

Digitized by Google

the injury. There was a remarkable absence of atheroma or calcareous change throughout the body.

The only case in the Society's 'Transactions' in any way comparable with this was communicated by Mr. Godlee (vol. xxvi, p. 13, 1875). It was in a child aged seven years, was longitudinal, involved both anterior and posterior surfaces of the trachea, caused separation of the right bronchus from the rest of the trachea, and was also the result of an accident, the child having been run over. In Holmes's 'System of Surgery' three cases of fracture of the trachea are recorded, one of which ended in recovery.

March 7th, 1899.

---

4. *Case of hypertrophy of the right lung with obliteration of the left.*

By Norman Dalton, M.D.

The patient was a man aged 45. No past history of the case was obtained as the man was dying of pneumonia when admitted into King's College Hospital under Dr. Curnow.

At the *post-mortem* no external deformity of the chest was noticed. On removing the sternum the right lung was seen covering the whole of the front of the chest. After filling the anterior

Fig. 7.

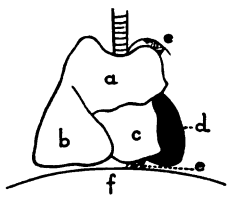

Fig. 8.

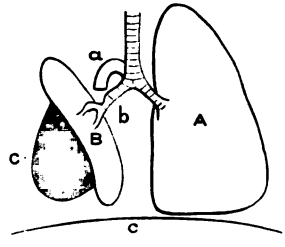

Fig. 7.—Diagrammatic representation of hypertrophied right lung, anterior aspect. *a*. Upper lobe. *b*. Lower lobe. *c*. Middle lobe. *d*. Heart. *e*. Adhesions. *f*. Diaphragm.

Fig. 8.—Diagrammatic representation of hypertrophied right lung, posterior aspect. A. Right lung. B. Left lung collapsed. C. Heart. *a*. Aorta. *b*. Left bronchus. *c*. Diaphragm.

Digitized by Google

mediastinum it ascended into and quite filled the left subclavicular area, when it was covered by its own pleura. So complete was this substitution of right lung for the apex of the left lung, that it is probable that in health the physical signs at the left apex were normal.

Below the subclavicular area the right lung occupied the left mammary and the precordial areas.

The heart occupied the left axillary region, only a small part of the left ventricle being uncovered by the right lung. The left lung was shrivelled and occupied the lower two thirds of the left vertebral groove behind.

On further examination it was found that the lower lobe of the right lung was pneumonic, and that the pleura over it was obliterated by old adhesions. The hypertrophy was due to enlargement of the front part of the upper and middle lobes. The extreme left border of the hypertrophied parts was emphysematous, and there were one or two old adhesions, notably one to the first left rib, which anchored what I may call the left apex of the right lung, and a large one which bound the lowest part of the hypertrophied middle lobe to that part of the diaphragm where the pericardium is usually situated.

The left lung was rather longer than the lung of a fœtus at full time, but quite flat and airless. The bifurcation of the trachea was normal, but the left bronchus was the smaller, and became further narrowed at about one inch from its origin. This narrowing appeared to be due to pressure on the bronchus from above, because, while the lower side of the tube was fairly straight, the upper side was concave on the outside and projected into the lumen, making the stricture. This concavity was just at the spot where the aorta crosses the bronchus, but the vessel was quite clear of the tube and could not have compressed it. I expected to find some enlarged glands here, but those I found were only slightly large from recent inflammation, and, while in search of something more definite, I removed them as you see in the specimen.

Above the stricture the bifurcation of the bronchus was found, and here the tube was larger again. After the bifurcation the branch to the lower lobe of the lung quickly became too small to follow, but that to the upper tube remained perceptible for another inch, but was curiously twisted, and its wall was thick and calcareous.

Digitized by Google

As regards the heart, there was slight acute pericarditis, with moderate effusion, but this could not have compressed the left lung, because the inflammation was quite recent, the pericardium showing no old thickening. The heart, as a whole, was large, possibly because it helped to fill up space, but the greater enlargement of the right ventricle, which formed the apex of the whole viscus, indicates that the hypertrophy of the right lung did not produce complete functional compensation.

Remarks.—The cause of the collapse could not have been direct pressure on the lung, because there was no tumour or effusion or trace of old effusion in the thorax capable of causing such pressure. It must therefore have been due to obstruction of the left bronchus, and we find evidence of this in the distortion of the main bronchus and its upper branch.

As regards the nature of the obstruction, if the distortion of the tube were congenital, I do not think that the lung would have grown to its present length while it contained no air and did no work. There is no sign of a foreign body in the tube, and I cannot think of any lesion, beginning in the mucous membrane, which would be likely to cause such distortion. It is therefore probable that the obstruction was due to pressure on the tube from without, and this view is supported by the depression of the upper wall of the left bronchus. In addition the aorta is separated from the bronchus by a considerable space, which before dissection was occupied by glands, and if the finger is put into the aorta, an angle can be felt instead of a gradual curve. I think, therefore, that at an early period of life there must have been a mass of enlarged glands between the bronchus and the aorta, and that these, after compressing the bronchus until complete collapse with obliteration of the air vesicles occurred, became smaller again. The pressure must have been gradual to allow hypertrophy of the right lung to occur instead of mere emphysema. In favour of the view that the pressure was partly removed after the mischief was done is the fact that the bronchus looks as if it must have at one time been smaller than it is now, for with its present lumen complete collapse of the lung could scarcely occur.

The specimen shows the difficulty that the lung has in becoming hypertrophied. One kidney or one testicle can hypertrophy as much as is necessary when its fellow is destroyed, for they have only increase of function to perform. But the lung has to enlarge not

Digitized by Google

only to perform increased function, but to fill up space. To accomplish the last object both the old and the new air vesicles become stretched and finally emphysematous, so that much of the new tissue is useless for the purpose of respiration. The large size of the right ventricle in this case shows that the one lung was, although so large, not performing fully the function of the two. *October* 18*th*, 1898.

---

5. *Lung showing uniformly distributed fibrosis.* (*Card specimen.*)

By A. E. Garrod, M.D.

Part of the right lung of a man, aged 39 a carman, who was not known to have followed any "dusty occupation." He died of cardiac failure with anasarca and dyspnœa. The heart was hypertrophied and generally dilated. In the ventricles were *ante-mortem* clots.

Both lungs were bulky, tough to the knife, and of nearly double the normal weight. The upper lobe of the lung shown exhibits emphysematous bullæ. There were some pleuritic adhesions, but the pleura is not thickened. The lung tissue is everywhere intersected by bands of bluish-grey fibrous tissue, forming a fine meshwork which contrasts strongly with the reddish tint of the congested lung. The nodes of the meshwork stand out as grey granulations, but there is no tubercle anywhere. The bronchi are neither dilated nor thickened. The bronchial glands were not caseous.

Under the microscope the lung shows diffuse infiltration with fully-formed connective tissue. Small inflammatory foci, composed of round cells, are found here and there, but nothing suggests tubercle. There is not more pigment than is usually present in the lungs of town dwellers. *May* 16*th*, 1899.

Digitized by Google

6. *A case of sarcoma of left lung and mediastinum.*

By CHARLES D. GREEN, M.D., F.R.C.S.

THE patient was a girl, aged 14 years, who was under observation for some three months before her death, complaining of general weakness and dyspnœa on active exertion. She was said to have been always rather delicate, and to have had attacks of pain in back and limbs attributed to influenza, but she had not been laid up for any length of time, and no date could be assigned for the commencement of the symptoms. There was no history of malignant disease in the family. When first seen on May 20th, 1898, there was dulness on percussion over the whole left side of the chest both anteriorly and posteriorly, with total absence of breath-sounds, except over a small area in the first intercostal space near the sternum, where a faint tubular breath-sound could be heard. The resonance over the right lung was normal, and at that time certainly extended well to the left border of the sternum. There was normal vesicular breath-sound over the whole of the right lung. The stomach resonance reached as high as the fifth rib. The cardiac dulness could not be distinguished as a separate area, but was not extended to the right side beyond its normal limit. The apex-beat could just be felt in the fifth space within the nipple line, but was very feeble. There was a soft systolic murmur audible with every beat. The left side of the chest scarcely moved with respiration, and was obviously contracted as compared with the right. There were no enlarged superficial veins over the front of the chest, and no enlarged cervical glands. I could detect nothing abnormal in the abdomen.

She was a bright and intelligent girl, and had attained the physical development normal to her age; she was not anæmic, and, though not fat, showed no signs of recent loss of flesh. There was no pain nor stiffness in any of the joints. I thought the case was one of consolidation and contraction of the left lung, probably consequent upon antecedent pleural effusion, complicated with mitral regurgitation, and that the attacks of pain which had been described had probably been that form of acute rheumatism with little joint affection so frequently seen in children. I did not

Digitized by Google

think that there was at that time any fluid in the pleura, and refrained from inserting a needle. For some weeks no very obvious change took place, but she merely seemed to become gradually more feeble. On July 16th, on her return from a short visit, I noticed a small, hard gland just above the right clavicle, and there was then for the first time distinct stridor on deep inspiration, and a dilated superficial vein could be seen running obliquely across the manubrium sterni. Her general nutrition was obviously failing, and from this time she got worse with great rapidity, a gland appeared above the left clavicle, and in the course of a few days a large glandular mass had formed above both clavicles. The heart's action was much more feeble, and the expansion of the right lung less perfect; the dyspnœa increased in severity, and emaciation attained an extreme degree with quite remarkable rapidity. The diagnosis of malignant disease in the lung and mediastinum was now easy enough. On July 22nd slight jaundice was for the first time noticed, and the gall-bladder could be felt. She was then, however, much too ill for detailed clinical examination. Death took place on July 23rd from the combined effects of dyspnœa and general nutritional failure.

At the autopsy, made sixteen hours after death, the body was extremely emaciated and slightly but distinctly jaundiced.

There was a mass of enlarged glands above each clavicle. On opening the thorax a large malignant mass was seen, which was found to extend from the sternum to the vertebræ and from the xiphoid to the upper opening of the thorax; it was adherent to, but had not eroded, the sternum; it had commenced to erode the body of the second dorsal vertebra on its left side; it had compressed the heart from above downwards, and had displaced the œsophagus somewhat to the right; it did not appear, however, to have infiltrated its walls nor to have obstructed its lumen to any material extent. The arch of the aorta and the great vessels were completely embedded in the growth, as well as the upper part of the pericardium.

There was general adhesion of the pericardium, the right ventricle was somewhat hypertrophied, no valvular disease was made out. The left pleura was universally adherent, and the lung was with difficulty removed with the mass; on section the left lung was seen to have been converted into a malignant mass, which appeared to have grown from the hilum outwards, and which was surrounded,

Digitized by Google

except at the apex, by a narrow fringe of indurated and airless lung tissue. The right pleura was normal; the right lung showed on section two small nodules of malignant new growth.

The pancreas was, with the exception of a small portion near its tail, replaced by a mass of new growth, over which the first two portions of the duodenum were stretched, and which had obstructed the common bile-duct. The lymphatic glands around the pancreas were enlarged, but not those in the portal fissure. The gall-bladder was much distended. The liver showed two small nodules of new growth, and its capillaries were distended with dark green bile.

There was a small spot of recent inflammation on the mesentery near the pancreatic growth, but the peritoneum was otherwise normal.

Spleen, kidneys, and intestines normal. Uterus and appendages normal. Brain not examined.

The growths were white on section, of firm consistence, and in the older portions of the larger masses showed bands of fibrous tissue. In the centre of the pancreatic growth was a small cavity with fluid, milky-white contents. On microscopical examination the growth was found to be a sarcoma with round, fusiform, and oval cells, and a relatively small amount of fibrous tissue. In sections taken from outlying portions of the growth groups of sarcoma cells could be seen extending along the walls of the blood-vessels.

In the mediastinal tumour, both in front and behind, the outlines of individual glands could still be distinguished.

Preparations of the mediastinal tumour with the heart and portions of the lungs attached, and of the pancreas and liver with microscopical sections showing the characters above described, were exhibited.

I think the growth was certainly primary in the thorax, and I am inclined to think that it began in the glands at the hilum of the left lung and invaded the lung first and then the mediastinum, and that the other growths were later secondary deposits. The massive character of the growth in the left lung contrasting with the nodular deposits in the right lung, the firm fibrous bands in its centre, and the general uniformity of the rest of the mass, together with the fact that the clinical evidence of loss of function of the left lung was an early feature in the case, are, I think, in favour of this view.

Digitized by Google

The rapid failure of nutrition was, I think, due to the destruction of the pancreas. In 1891, at this Society, Dr. Rolleston showed specimens from a case in which the distribution of malignant growths was very similar to that in this case, in which no symptoms were attributed to the growth in the pancreas, but the head of the organ was not in that case affected and the function of the organ presumably not destroyed. In that case the growth was scirrhus, and described as primary in the pancreas.

In the 'Archives de Médecine' for 1890 there is an interesting and instructive paper by Letulle on mediastinal tumours originating in the remains of the thymus, with details of eight cases, but the distribution of the lesions was in none of them quite similar to that in this case. The presence of a systolic murmur was a notable feature in some of the cases, and I have myself observed it in some other cases in which I have had reason to believe that there was enlargement of mediastinal glands.

Germain Sée, in his work 'Maladies spécifiques de Poumon,' quotes from Jaccoud a case in which in the space of eight or ten days a malignant growth had filled the whole of the upper part of the anterior mediastinum and had invaded the entire upper lobe of the right lung, but the grounds upon which this limitation of time is based are not stated.

In the museum of the Royal College of Surgeons there is a specimen, No. 2858A, which was shown by Dr. S. West at this Society in 1883, which was taken from a boy aged sixteen years, and in which there is a similar mediastinal tumour which has invaded the adherent left lung, and in which the great vessels are embedded. There does not appear to be in this specimen the same conversion of practically the entire lung into a malignant growth which exists in the specimen shown this evening. In the same collection there is another specimen showing the aorta embedded in a malignant growth. Both of these specimens are described as lympho-sarcoma.

December 20th, 1898.

Digitized by Google

III. DISEASES, ETC., OF THE ORGANS OF CIRCULATION.

1. *Dextrocardia; left superior vena cava; endocarditis.* (*Card specimen.*)

By Norman Dalton, M.D.

Boy aged 15. During life the position of the heart was obviously on the right side of the chest. The liver was in its usual place. The spleen was very large. Death was due to embolism.

Post-mortem.—The right lung had two lobes only.

The apex of the heart was beneath the sixth right rib, 2½ inches from the middle line of the sternum.

The pulmonary artery was more exposed than usual, and its course before bifurcation was longer than usual.

The superior vena cava was normal, though small. On the left side a vessel as large as the superior vena cava ran straight down from the left jugular vein until it reached the left auricle. There it entered the coronary sinus behind the left auricle. The coronary sinus was very large, and entered the right auricle by an opening which just admitted the forefinger. This was practically a persistent left duct of Cuvier.

The left innominate vein was represented by a very small vessel.

There were fungating vegetations on the mitral valve.

November 1st, 1898.

2. *On dilatation of the right ventricle upwards and to the left.*

By T. Stacey Wilson, M.D.Edin., M.R.C.P.

The aim of this paper is twofold:—Firstly, to demonstrate the change in shape which the upper part of the right ventricle undergoes when it dilates; and secondly, to show the changes in the pulmonary artery which result from this upward dilatation of the right ventricle, and point out the bearings which they

Digitized by Google

have upon the causation of the systolic murmur which is heard over the pulmonary artery in cases of cardiac overstrain and anæmic dilatation of the heart.

FIG. 9.

No. 1.

No. 2. No. 3.

Photograph of cardiac ventricles from above after removal of the aorta, pulmonary artery, and the two auricles. No. 1. Normal heart. It will be noticed that little of the anterior wall can be seen, and that the base of the pulmonary artery is in the photograph almost vertically over the aortic valves. No. 2. Heart with slightly dilated right ventricle. It shows that the anterior wall of the right ventricle bulges forward in front of the aorta, and pushes the origin of the pulmonary artery to the left of its normal position. No. 3. Heart from aortic and mitral disease, with dilatation and hypertrophy of both left and right ventricles. It shows very marked forward bulging of the anterior wall of the right ventricle and the considerable displacement of the pulmonary artery to the left. It also shows that the pulmonary valves and upper part of the right ventricle are not in the plane of the auriculo-ventricular septum as in hearts 1 and 2, but lie in a higher plane, *i. e.* are in the photograph projecting forwards towards the observer.

Digitized by Google

FIG. 10.

No. 1.

No. 2.

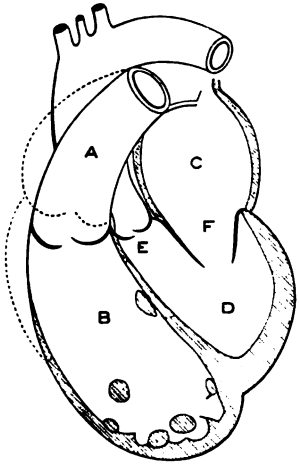

No. 3.

Nos. 1 and 2. Lateral view of distended hearts, drawn from photographs, ⅔ natural size. No. 1. Normal heart. No. 2. Heart with slight dilatation of the right ventricle upwards. It shows the elevation of the pulmonary valves and consequent shortening of the artery, and also the altered direction of the artery relatively to the main axis of the right ventricle. No. 3. Semi-diagrammatic view of a normal heart as seen in section through the pulmonary artery and right ventricle. To illustrate the shortening and dilatation of the pulmonary artery which results from upward dilatation of the right ventricle. The dotted line represents the change that takes place.

Digitized by Google

This paper is illustrated by the study of three hearts:

1. From a man who died as the result of an accident. This heart may be considered normal.

2. From a woman aged 48, who died suddenly from hemiplegia with cardiac failure, and who was found to have a congenital defect in the interauricular septum. In this case the right ventricle and right auricle are rather dilated, and the left are approximately normal.

3. From a girl aged 15, who died from cardiac failure, the result of disease of both aortic and mitral valves. In this case the right ventricle is greatly dilated as well as the left ventricle and auricle.

The hearts were distended with hard paraffin prior to their removal from the body, with the exception of No. 2, which was not distended *in situ*.

As to the pressure under which the injection was made, I employed an ordinary injection syringe and did not use a manometer or other pressure gauge, but was careful not to over-distend the hearts. I cannot, therefore, state the pressure employed, nor do I consider it a point of importance in the present connection, since my object is to illustrate one of the ways in which the ventricle dilates, and not the degree of dilatation that occurs. I nevertheless am confident that the specimens which I am showing are truthful in this respect also.

In addition to the casts of the entire heart I also show the ventricles isolated by the removal of the auricles and aorta and pulmonary artery.

Comparison of the two dilated right ventricles thus isolated with that of the normal heart shows very clearly the change in shape which takes place when the right ventricle dilates upwards in the manner so well described by Dr. Foxwell in his 'Essays on Heart and Lung Disease.'

In a view of the isolated ventricles from above, as in the photographs in Fig. 9, the dilated upper portion of the right ventricle is seen as a distinct prominence bulging forwards beyond the normal limits. Not only does it project anteriorly, as is well shown in the photographs of hearts 2 and 3, but it also projects upwards beyond the plane of the auriculo-ventricular septa, and so comes to overhang the commencement of the aorta. This is well shown in the case of heart No. 3, Fig. 10, where the isolated

Digitized by Google

ventricle is viewed from the side. It can also be seen in the photograph of heart No. 3 in Fig. 9.

I do not show these specimens of upward dilatation of the right ventricle as an unusual condition, but as a good demonstration of a very common condition; for although this type of dilatation seems to be but seldom referred to in current literature, I believe that if it be carefully looked for clinically and in the *post-mortem* room it will be found to be extremely frequent in cases of cardiac failure from a great variety of causes.

It is, I believe, the ordinary type of dilatation in youth and early adult life, for at this period dilatation of the right ventricle upwards and to the left usually precedes and exceeds in amount any dilatation of the ventricle to the right.

In adults this upward dilatation seems to be, as a rule, *less* marked than dilatation to the right of the sternum, and after the age of forty-five or so it seems to be decidedly rare, for in the later years of life the dilatation is towards the right side, and the conus arteriosus yields but little.

This upward dilatation is often very extreme in youth and adolescence. For example, in Case 3 the relative dulness of the heart commenced above the second rib on the left side and extended to the nipple line in the third interspace, and after death some months subsequently the pulmonary valves were found to lie at the level of the first rib. Such a degree of dilatation is not very uncommon.

I now come to the consideration of the effect which this upward dilatation of the ventricle has upon the pulmonary artery. The effect of the upward extension of the conus arteriosus is twofold: firstly, the artery is shortened; secondly, the direction of its course is altered.

Firstly, as to the shortening of the pulmonary artery. It is evident that the increase of the upper part of the right ventricle upwards and to the left must carry the origin of the pulmonary upwards with it, and since the course of the artery is normally upwards from the pulmonary valves, any elevation of the point of origin must shorten the course of the artery. This is shown in Fig. 10 by comparing No. 1 with No. 2, and also in the diagram.

When, as is often the case, the pulmonary valves lie under the second rib instead of under the third, this shortening must amount

Digitized by Google

to ¾ inch or more. Taking the normal length of the artery at 2½ inches, this would mean a shortening of 30 per cent. The effect of this shortening must be to relax the walls of the artery.

This relaxation may be seen *post-mortem* as a distinct wrinkling of the arterial wall in extreme cases. More often, however, the elastic contractility of the vessel prevents any distinct wrinkling. Although the relaxation of the vessel-wall may not show after death when the artery is empty, it cannot fail to cause some distortion during life. The relaxed wall is sure to yield abnormally to the blood pressure, and dilatation of the artery will result. There will, therefore, be both shortening and dilatation of the pulmonary artery, and the two combined will tend to make the artery become more spherical than normal. In other words, when the shortening is considerable there will be an aneurysmal bulging of the pulmonary artery under the influence of the blood pressure.

And now *as to the altered direction of the pulmonary artery.* Taking the normal course of the first part of the artery as being obliquely upwards and backwards, it is evident that if its point of origin is raised its course will become more horizontal than normal. When, as often happens, the pulmonary valves lie under the second rib instead of under the third, the alteration in the course of the artery is considerable.

This altered course means an alteration in the axis of the pulmonary artery as compared with the axis of the ventricle, and instead of the artery being fairly in line with the axis of the ventricle, as it ought to be, it will be at an angle to it. I have frequently noted this change in the direction of the pulmonary artery *post mortem*, more especially if the ventricle happened to be distended. Under such circumstances the sudden dipping backwards of the artery is most noticeable. Thus, in the case of heart No. 3, I noted at the *post-mortem* that the first part of the pulmonary artery was at right angles to the longitudinal axis of the right ventricle, instead of being nearly in the same line as in a normal heart.

In No. 3, Fig. 10, a semi-diagrammatic view is given of a section through the centre of the pulmonary artery and right ventricle to illustrate the distortion of the former. It is not easy to represent the change in the direction of the artery of which we are now speaking in this diagram, because it is accompanied by a move-

Digitized by Google

ment of the pulmonary artery and valves to the left of the normal position, *i. e.* out of the plane of the diagram.[1]

This lateral movement of the artery is well shown in the photographs of Fig. 9. In the normal heart, No. 1, the pulmonary valves are seen to be almost vertically over the aortic valves. In both of the other hearts the pulmonary valves and base of the pulmonary artery are seen to lie considerably to the left of their normal position.

The practical result of this alteration in the direction of the pulmonary artery as compared with the axis of the ventricle, is as follows :—When the ventricle contracts the blood is thrown against the anterior wall of the pulmonary artery, instead of being thrown in the direction of its lumen. This will be seen on comparing No. 2 with No. 1 on Fig. 10.

Here, then, we have two conditions eminently favourable to the production of an aneurysmal murmur. We have a pulmonary artery that becomes more globular than normal under the influence of the blood pressure, and we have the blood thrown into it so as to strike one of its walls—conditions likely to bring about a murmur-producing eddy in the dilated artery.

These two factors, the increased distensibility of the pulmonary artery and the alteration of its axis, as compared with that of the right ventricle, are, I believe, of prime importance in the causation of the common systolic murmur which is audible over the second left interspace in cases of cardiac overstrain and cardiac debility in anæmia and other diseases.

In other words, I feel satisfied, from clinical and pathological evidence, to which I cannot refer within the limits of this paper, that the type of dilatation of the right ventricle with which this paper deals is the pathological condition which produces the common pulmonic systolic murmur of anæmia and overstrain, and that the mechanism is such as I have suggested.

I do not say, however, that upward dilatation is sufficient by itself to produce this murmur in all states of the circulation, for I know that such is not the case. Extreme degrees of upward dilatation of the right ventricle can exist without producing any basal murmur.

[1] The attachment of the posterior part of the pulmonary artery and of the adjacent part of the right ventricle to the anterior part of the aorta and left ventricle is not sufficiently firm to prevent such a shifting of the pulmonary artery from taking place.

Digitized by Google

Upward dilatation of the ventricle gives rise to the possibility of an aneurysmal murmur being produced in the pulmonary artery.

When the conditions of the circulation are favourable, an aneurysmal murmur is produced in the artery, and even an aneurysmal thrill. When they are not favourable no murmur is produced. When, for instance, the blood pressure in the pulmonary artery is high and the intra-thoracic pressure low, there will be a tendency for the artery to dilate easily, and remain more or less dilated, becoming practically an aneurysm. When, on the other hand, the intra-thoracic pressure is high, as in pneumonia, the external pressure on the artery will tend to hinder its dilatation, and it is not, therefore, surprising that in pneumonia extreme upward dilatation of the right ventricle can exist without any cardiac murmur being caused thereby.

This, then, is the bearing which I believe upward dilatation of the right ventricle has upon the production of the pulmonic systolic murmur of anæmia and cardiac debility.

April 18*th*, 1899.

---

3. *Extreme dilatation of the left auricle without mitral stenosis.* (*Card specimen.*)

By H. Morley Fletcher.

The heart, presented by T. H. Woodfield, Esq., to the Museum of St. Bartholomew's Hospital, was taken from a woman aged 47, who was under treatment at the Greenwich Infirmary for nearly five years previous to her death. During her life presystolic and systolic murmurs were heard at the apex. Cyanosis and much œdema were present.

At the *post-mortem* examination the left auricle was found distended with recent clot. It was larger than the rest of the heart taken together. It measured seven inches in its transverse diameter, and five inches vertically. Its outer surface was injected and showed signs of fairly recent pericarditis. The wall was much thinned, and microscopically showed an almost complete absence of muscular fibres, the normal structure having been replaced by fibrous tissue, and containing calcareous plaques.

The mitral orifice admitted three fingers. The mitral valve

Digitized by Google

segments were thickened. The left ventricle was dilated and hypertrophied. The right ventricle was also hypertrophied. The lungs were highly emphysematous.

Remarks.—This extreme degree of dilatation of the left auricle is very unusual, and it was probably due, not to obstruction at the mitral orifice, but to the degeneration of the muscular tissue of its walls. It appears probable that this may have been secondary to pericarditis, the signs of which are visible over the auricle.

November 1st, 1898.

---

4. *Spontaneous rupture of the heart.* (*Card specimen.*)

By Cecil F. Beadles.

In vols. xliv and xlvi of these 'Transactions,' cases of spontaneous rupture of the heart from insane persons have been recorded. To these are added two more. The heart shown weighs 15 ounces, and is in an exceedingly fatty state. In addition to much fat externally, the muscular wall has a pale, soft appearance from fatty infiltration and actual degeneration of the muscle-fibres. Small islands of fat can be seen embedded amongst the muscle. There are patches of thickening in the flaps of both the mitral and aortic valves. The aorta is very atheromatous; the coronary arteries are obscured by the external fat, but the disease is seen to affect the orifices of these vessels. Two small rents exist on the anterior surface of the left ventricle about its centre. They are less than a quarter of an inch apart, and the longest is just a quarter of an inch in length. These open directly into the cavity of the left ventricle, but their inner extremity is concealed by the overhanging columnæ carneæ.

On opening the pericardium a layer of dark clot was found completely surrounding the heart, in front spread over as a thin film, but behind forming a great mass. The rupture occupied the centre of the exposed surface of the heart, and there was some blood-staining in the immediate vicinity. All the cardiac cavities were entirely free from fluid or clotted blood. Other organs were not examined.

From male patient, 6363, aged 81, the subject of melancholia

Digitized by Google

for twenty-four years. He was an intellectual old man, who previously had been a parish clerk, and who, during almost the whole period of his residence in Colney Hatch Asylum, made himself useful by assisting the medical staff with writing of a copying nature, at which he was most reliable and industrious, and wrote a neat and steady hand up to the last. He was subject to occasional periods of depression. For some years his heart was known to be in a weak and diseased state. Towards the close of last year he was several weeks in bed with general weakness, following an attack of acute gastritis, and from this he never regained his former strength, He, however, continued at his old employment up to the day preceding his death, although for some days he had more pain than usual over the cardiac region. Having done some writing in the morning of March 6th, he took a quiet walk in the grounds during the afternoon, and retired to rest at the usual time, having made no further mention of pain or uneasiness. At 4.30 in the morning he was found dead in his bed, having been last seen alive at 2.30 a.m. It was obvious that he had passed away quietly within half an hour of being seen; and another patient near, who had been awake during the interval, believed he had simply fallen asleep.

The other case is one that occurred since my last communication, and differs from all the other hearts in the fact that the wall of the right ventricle gave way, and not the left.

This heart was very fatty, and its wall could be readily torn near the junction of the ventricle and auricle of the right side; a little lower was a rupture passing through the wall of the right ventricle. Aorta and other arteries atheromatous. Pericardium filled with clotted blood. Kidneys very granular, Liver fatty.

From female, 5932, who died July 9th, 1895, at the age of 97, having been insane thirty-two years. For many years she had been in a demented state, and for over ten years she had been subject to chronic bronchitis and emphysema, with frequently swollen feet and legs. During the last five years she suffered from very feeble health and was almost blind. On June 8th she fell and sustained an intra-capsular fracture of the head of right femur. At the autopsy the fracture was found ununited and the capsule filled with fluid. Soon after a severe attack of diarrhœa set in, which lasted several days. The day before she died, not having been out of bed since the accident, she began crying out incessantly, but was

Digitized by Google

unconscious to all her surroundings. It is highly improbable that the heart received injury at the time of the accident, though it is just possible that a small branch of the coronary artery burst, and a clot forming in the wall of the ventricle finally caused the muscle tissue to give way.

The last-mentioned case makes the tenth ruptured heart recorded in Colney Hatch Asylum in forty-eight years, during which period there have been 9290 deaths. It is worth noting that out of 10 cases of spontaneous rupture of the heart, in nine the rent occurred in the wall of the *left* ventricle.

I will briefly add two cases of injury to the heart which come under a different category to the preceding. The first was probably rupture of a cardiac aneurysm, the second a case of bruising without actual rupture of the organ after external violence.

Male, 769, died suddenly in the year 1855, aged 33, after eighteen months' residence in the asylum, but the subject of epilepsy from childhood. A quantity of fluid blood and coagula existed in the pericardium, which had escaped from a rupture of a "morbid cyst on the apex of the right auricle." This case is said to have been published in the 'Pathological Journal,' September, 1855.

Male, 6611, a discharged soldier, addicted to intemperance and tobacco chewing, of violent and homicidal tendency, met his death in 1882, aged 28, after being six years in the asylum. He was struck several times on the chest with a shovel by a fellow patient. He fell at once and died immediately. The sternum was transversely fractured between the second and third ribs, and there was blood effusion into the soft structures. The pericardium contained about 2 oz. of straw-coloured fluid. The heart presented slight effusion of blood on the anterior surface of the left ventricle beneath the serous covering. All the cardiac cavities were quite empty, the muscle tissue slightly pale, valves normal, weight of organ 13½ oz. There was no rupture. Other organs in a normal state, with the exception of slight chronic changes in the brain and its membranes. *March 21st*, 1899.

Digitized by Google

5. *Heart thrombus in a case of enteric fever; embolism of the right common iliac artery; incipient gangrene of the leg; multiple infarcts in the spleen and kidneys.*

By WILLIAM HUNTER, M.D., F.R.C.P.

THE specimens exhibited are: (1) thrombus in left ventricle; (2) large embolus impacted at origin of right common iliac artery, with distal portion of artery and its branches completely thrombosed; (3) corresponding veins, secondarily thrombosed; (4) recent infarcts in both kidneys, and in spleen. They are from a youth, aged 19, who was admitted into Charing Cross Hospital, under Dr. Green, on twelfth day of illness from typhoid fever, and who died on the twenty-third day.

History.—Four days after admission (seventeenth of illness) he had a rigor, the temperature rising to 104·6°, with sudden agonising pain about middle of right thigh on inner side; and the right leg below knee became paler than left as far up as middle of thigh. Five hours later the limb was of a dead white colour, and cold up as far as knee, while above knee it was bluish and warm. Pulsation could be felt in popliteal artery, but not in arteries of foot.

By the following day (eighteenth) the condition of matters in the limb was such that the foot as far as a hand's breadth above ankle was of a dead white colour, and very cold; the leg up to the knee was bluish, dusky, and very cold, with numerous ecchymoses; the thigh bluish, cold to touch, and much swollen. No pulse could now be felt either in popliteal or femoral artery, and the groin was very tender.

The limb was, under Mr. Boyd's directions, thoroughly shaved, washed, mercurialised, and wrapped in cyanide gauze and salicylic wool. The urine was smoky, although no blood could be detected, contained casts and granular *débris*, and large trace of albumen.

During the following night (the nineteenth day) there was another rigor (temp. 104°, falling in four hours to 100·4°, and then rising in three hours to 105·8°), and his general condition was much worse. Pulse 130, heart-sounds very feeble. Resp. 44. Tongue dry and very fissured.

The right *foot* was quite cold, yellow-white, beginning to shrivel.

Digitized by Google

Leg now almost uniformly bright red, this colour being unaffected by pressure.

Thigh bluish and swollen; ecchymosed on inner side, blue on outer side. Sensibility to touch lost below knee, only slight above knee.

Next day (twentieth) sleeplessness and occasional delirium. Foot more shrivelled, leg somewhat swollen, thigh further swollen and more bluish.

Twenty-first day and following day an irregular line of demarcation appeared about middle of thigh; limb below this bluish red and cold; above this dusky, swollen, circulation in it very feeble.

Death occurred on twenty-third day. During last three days temperature subnormal, varying between 96° and 98°.

Post-mortem (thirty hours after death).—Right leg swollen and discoloured, a deep red livid colour from about the middle of thigh to lower third of leg. Foot and lower third of leg not discoloured; toes shrivelled and dry. The upper limit of discoloration in thigh is sharply marked off from paler surface above by an irregular wavy border. Swelling most marked in upper thigh, and diminishes from above downwards.

Intestines showed limited typhoid lesions, ulceration, and pigmentation in the lower three feet of ileum, chiefly in the lower foot. In cæcum ulceration very deep down to the peritoneum; numerous ulcers in ascending and transverse colon.

Heart weighed 9½ oz. Valves normal. Left ventricle moderately dilated;. at extreme apex a polypoid thrombus adherent to its wall, of a pale yellow colour, showing partial lamination; centre partly softened. Thrombus measures one inch in length, three quarters of an inch in breadth. Microscopically is found to be made up of fibrin and leucocytes, with relatively little red clot. No clots or thrombi in left auricle.

Common iliac artery.—At point of origin an irregular, somewhat flattened embolus, of a pale colour similar to that of thrombus in heart, firmly impacted, not adherent to wall of artery. The embolus measures five sixteenths of an inch in its transverse diameter, and is three sixteenths of an inch deep. The artery beyond and all its branches filled with soft red thrombus, slightly adherent to, but easily separable from, the wall. The red colour of this contrasts markedly with the pale colour of the embolus, to which it is attached above. This is well seen in the specimen

Digitized by Google

(twelve months old) now shown, the natural colours having been preserved by formalin. The corresponding veins, viz. right common iliac and its branches, are all completely thrombosed. Left common iliac artery and its branches with the corresponding veins are normal.

Kidneys.—Both show recent infarcts. The *left* (6½ oz.) shows two: (1) a larger one, triangular in shape, base half an inch wide, depth half an inch, with an outer deeply congested zone one eighth of an inch wide, and a central yellowish and pale zone a quarter of an inch wide, extremely well marked, as still well seen in specimens shown; and (2) a smaller one, three sixteenths of an inch wide at base and three sixteenths of an inch deep, showing similar zones. The *right* kidney (6 oz.) shows a much larger infarct extending along surface from hilus of kidney to extreme periphery. In length this is 2½ inches, width half a inch, and depth, as seen on cut surface, half an inch. This shows the same central pale and the marginal congested zones.

Spleen 8¼ oz., enlarged, soft; shows two recent infarcts of small size, and seven sixteenths of an inch by four sixteenths of an inch in anterior border, and a larger one in its posterior border (three quarters of an inch by half an inch).

Remarks.—The condition of embolism described is sufficiently rare to deserve special notice. The occurrence of infarcts in the spleen in typhoid fever has long been described. It is stated by Fagge to be not uncommon. Suppuration and rupture of such infarcts is mentioned in text-books as one of the possible causes of acute peritonitis in typhoid fever. But that it is a rare complication is clear. For it was only observed in two out of sixty-one cases by Murchison, in nine out of 250 cases by Hoffmann, and one out of ninety-five cases collected by Norman Moore.

Infarcts in the kidney are apparently even less frequent. Murchison only met with them in two cases; Hoffmann in ten out of 250.

One of Murchison's cases is described in our 'Transactions' (vol. xvi, 1865); the patient suffered from diarrhœa all the time; died about the ninth week suddenly. In spleen were found two infarcts the size of chestnuts. Heart is described as "healthy."

Still more rarely infarcts have been found in the liver. Such a case is recorded by Murchison in these 'Transactions' (vol. xv, 1863), reported on and confirmed by Wilks, where an opaque,

Digitized by Google

yellow mass of the size of a pigeon's egg was found in the liver resembling an infarct.

As regards embolism of large arterial trunks, single cases of embolism of pulmonary artery have been described by Fagge (vol. xxvii) occurring in fourth week; by Murchison and by Norman Moore. Embolism of arteries of limb has been met with clinically in a considerable number of cases, usually followed by gangrene of limb.

A typical case of this kind, observed clinically, resembling that I have now described, is the one described by Dr. Sidney Phillips ('Clin. Soc. Trans.,' vol. xxiv, 1891), where the left femoral artery was suddenly occluded about the thirty-fourth day. He ascribed the occlusion to embolism rather than to thrombosis. The action of heart was weak and irregular throughout.

Another case of embolism after typhoid fever necessitating amputation has been described by Dr. Drewitt ('Lancet,' 1890).

In most of these cases the source of the embolus has only been surmised. In only one of them, that described by Dr. Norman Moore, do I find mention of *ante-mortem* clots in heart (Case 28) accompanying infarcts in lung and spleen.

The case which pathologically most closely parallels the one I have just described is that described by Murchison (vol. xvi, 1865), occurring, however, in typhus fever, not in typhoid—viz. embolism of iliac, femoral, and other arteries in a case of typhus complicated with œdema and gangrene of lower limbs; death on forty-first day of disease, and twenty-four days after the embolism. In that case infarcts in spleen and right kidney were found. "In left ventricle several masses of firm decolourised fibrin slightly adherent."

November 15th, 1898.

---

6. *Aneurysm of the splenic artery.* (*Card specimen.*)

By H. D. Rolleston, M.D.

An aneurysm the size of a cherry was found on one of the branches of the splenic just after the main trunk had divided up close to the hilum of the organ. The artery was, as usual, very

Digitized by Google

tortuous, but was comparatively very free from atheroma, and the walls of the aneurysm to the naked eye were much like those of a healthy artery. There was no evidence of embolism. It is remarkable that there was a small aneurysm on one of the branches of the right middle cerebral artery, the walls of which were also apparently healthy.

The specimen was removed from a woman, aged 37 years, who died from the effects of granular kidney. Her heart weighed 18 oz.

In the absence of atheroma and embolism, it seems possible that this patient had a condition of vessels approaching that of hypoplasia, and that the high vascular tension, due to her kidney disease, had led to a dilatation of the vessel walls. This seems probable as the vessels which gave way were both badly supported. Dr. Lee Dickinson, in the forty-fifth volume of this Society's 'Transactions,' recorded two cases of aneurysm due to congenital delicacy, and not to acquired disease of the aorta.

Aneurysms of the splenic artery are seldom recorded. In a recent search I could only find about twenty published cases. It is highly probable that small ones are by no means rare, for two were found in the *post-mortem* room of St. George's Hospital within a few months of each other. The splenic artery is one of the arteries in the body most prone to undergo atheromatous changes, and, being badly supported, is therefore disposed to further aneurysmal change.

Again, emboli frequently pass through it, as shown by the occurrence of splenic infarcts, and probably they not infrequently lodge where the artery divides up before plunging into the substance of the spleen. The reason why aneurysms of the splenic artery, and especially those on its branches near the spleen, are seldom seen is probably that the spleen is usually removed before the splenic artery is examined, and that the condition of the artery is comparatively seldom minutely investigated.

March 7th, 1899.

Digitized by Google

7. *Aneurysm of splenic artery.* (*Card specimen.*)

By W. S. Lazarus-Barlow, M.D.

The specimen shows an aneurysm with calcareous walls, and globular in shape, on the splenic artery where it passes from the tail of the pancreas. The aneurysm is about the size of a filbert, and at the autopsy had an appearance which suggested that it was a large calculus. On further examination it was found to be full of blood-clot. The artery in the neighbourhood and on the proximal side of the aneurysm is highly calcareous and filled with thrombus. An aneurysm the size of a pea, also with calcareous walls and filled with thrombus, is situated on the proximal side of the main aneurysm, and distant from it about one inch. The specimen was obtained from the body of a man, aged 61, who died from chronic renal fibrosis. The aorta was excessively thick and slightly atheromatous, the cerebral arteries were dilated, and their walls were thick but not atheromatous. The morbid condition of the splenic artery gave rise to no symptoms. Though atheroma of the splenic artery has been recorded in the Society's 'Transactions' twice by Dr. Ogle (vol. iii, p. 337, 1852, and vol. xi, p. 269, case 3, 1860), and is itself no very uncommon condition, no example of aneurysm of the artery is recorded. According to Lebert (cited by Quincke in von Ziemssen's 'Cyclopædia'), out of thirty-nine cases of aneurysm of abdominal arteries, excluding the abdominal aorta, the superior mesenteric and the splenic arteries were affected ten times, the hepatic artery and its branches eight times, the cœliac and the inferior mesenteric arteries three times, the renal artery twice; in three instances the aneurysms were multiple, in thirty-six they were solitary. *March 7th*, 1899.

---

8. *An apparent thickening of subcutaneous veins.*

By F. Parkes Weber, M.D., F.R.C.P.

If the superficial veins, especially the internal saphenous veins, be examined in a number of rather thin, cachectic men, it is found that in at least some of these cases the vessel walls feel as if they were thickened. Occasionally the veins can be rolled about

Digitized by Google

under the finger like solid cords, though thinner than they would be if they were thrombosed vessels. I have noticed the condition chiefly in men slightly under middle age, and it is certainly not necessarily accompanied by any obvious corresponding thickening of arteries. When, however, it occurs in arterio-sclerotic subjects, it is likely to be set down as a "phlebo-sclerosis," and in syphilitic subjects it has probably been at times regarded as a chronic specific thickening of the vessel walls. I have endeavoured to find out what the cause is of this apparent thickening of veins.

As far as I have been able to investigate the matter, the apparent thickening of the vessel walls noted during life seems to be due to a contracted condition of the veins (perhaps sometimes merely a result of little blood having at the time to pass through them) in cases where the longitudinal bundles of unstriped muscle-fibres, which constitute the inner portion of the tunica media,[1] happen to be particularly well developed.

In transverse sections of the veins these longitudinal bundles of

FIG. 11.

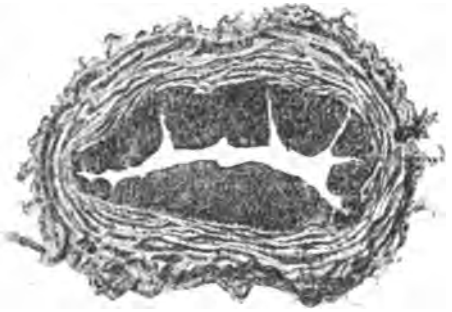

Transverse section (× 22) of internal saphenous vein from the right thigh of a man aged 25.

[1] Some would prefer saying that this longitudinal muscle lies in the outer part of the intima. The distribution of the longitudinal muscle in the internal saphenous veins appears to me to vary much in different individuals, and even in the two limbs of the same individual. Generally, most of it lies within the zone of circularly arranged muscle-fibres, whilst a few bundles, if any, lie without. Occasionally, however, the greater part of the longitudinal muscle is arranged in bundles outside the zone of circular muscle, only very little being placed between this zone and the endothelium.

Digitized by Google

muscle-fibres are seen projecting into and narrowing the lumen as if they were squeezed together by the circular muscle-fibres which form the main portion of the tunica media. This is, I believe, not merely a *post-mortem* appearance due to the action of hardening reagents, for it is difficult in any other way to explain the condition felt during life.

I am unable to decide that there is any actual hyperplasia of the inner portion of the middle coat, like that described by Cornil[1] in early stages of varicose veins. The upper part of the internal saphenous vein may certainly feel like a thin, hard cord, as I have had occasion to note recently, though the lower portion is varicose, but without microscopical examination the exact condition of the upper part of the vein in such cases cannot be ascertained.

In order to find out whether a contracted or empty condition of veins can give rise to an apparent hyperplasia of the inner portion of the middle coat, part of a vein has been hardened in the ordinary way, and a similar part has been hardened (as suggested by Dr. Payne) with the lumen artificially distended. Mr. Shattock kindly obtained the internal saphenous vein from the thigh of a man, about 30 years old, who died under an anæsthetic administered for some operation on the neck. A part of this vein he artificially distended, and sections were cut of the distended part, and likewise of a similar portion hardened without previous distension. The undistended portion shows the typical apparent hypertrophy of the longitudinal bundles of the inner part of the middle coat, whereas the distended portion of the vein shows nothing remarkable. It may, therefore, be concluded that emptiness and contraction are, in themselves, sufficient to explain the cord-like condition of veins felt during life, a condition which doubtless corresponds to the ridges of the longitudinally arranged bundles of muscle-fibres seen projecting into and filling up the lumen of the vessels in transverse sections after death.

I am forced, therefore, to come to the conclusion that the reasons why this condition is clinically especially noticeable in men about 30 years of age, in hospital for wasting diseases, are—(1) That

[1] V. Cornil, in his article on the "Pathological Anatomy of Varicose Veins," 'Arch. de physiol. norm. et path.,' Paris, 1871, tome iv, p. 602, says that when the varicose condition is not very great, on cutting open the vein longitudinal folds may be noticed, caused by hypertrophy of the most internal portion of the middle tunic, as can be shown by sections.

Digitized by Google

the active muscular employment of a working man gives rise before the age of thirty to full development of the unstriped muscle in the walls of the superficial veins of the limbs; (2) that the compulsory rest in hospital, diminishing the circulation of blood through the limbs, causes some of the superficial veins to be comparatively empty and contracted; (3) that the wasting of subcutaneous fat, consequent on disease, allows the superficial veins to be more easily felt and rolled about under the finger.

In some of my sections it appears that the fibrous tissue of the inner part of the middle tunic is also increased, and, moreover, that there is a proliferation of the endothelial cells of the internal tunic (superficially resembling a kind of "endophlebitis proliferans"). Both conditions may, however, be merely apparent changes, due to the contracted state of the vessel walls. A moderate degree of this apparent endothelial thickening was observed in the left internal saphenous vein of a man aged 25, whose right internal saphenous vein is figured here as an example of the matter under discussion. *January 3rd*, 1899.

---

9. *Tuberculosis of the inferior vena cava.* (*Card specimen*).

By J. H. Drysdale, M.D.

The specimen was taken from a man who died of pulmonary tuberculosis in St. Bartholomew's Hospital. At the *post-mortem* examination the right supra-renal capsule was much enlarged by fibro-caseous tuberculous deposit. On opening the inferior vena cava, where it had been in contact with the enlarged adrenal, a number of small tubercles could be seen projecting on the inner surface. Tubercle bacilli were demonstrated in microscopical preparations. *May 16th*, 1899.

Digitized by Google

IV. DISEASES, ETC., OF THE ORGANS OF DIGESTION.

1. *Actinomycosis of the tongue.*

Exhibited by R. G. Hebb, M.D., for Mr. Ludford Cooper.

The patient, T. D—, aged 60, a naval pensioner, was admitted to St. Bartholomew's Hospital, Rochester, under the care of Mr. Ludford Cooper, having been sent up for opinion by Fleet-Surgeon Sweetman. He stated that he had noticed a "small lump under the tongue for some time, but cannot say how long." Some months ago there was "a little crack in the middle of the tongue." He has often been in the habit of picking "bits of things," flowers, straws, &c., and putting them in his mouth. He has been a great smoker. There is no history of venereal disease. He has not wasted, and has had no pain in his tongue. His mother died of "cancer of the breast," and his father, at seventy-seven, of "old age." The patient is a healthy looking man, and, bar the tongue, nothing abnormal was discovered after careful examination.

On the dorsum of the tongue, exactly in the middle line, and about one inch from the tip, is a swelling about the size and shape of an almond, with slightly indurated edges. There is apparently no fluctuation in the tumour. There are no enlarged lymphatic glands. As it was a doubtful looking tumour, and although possibly a gumma, it was thought proper, taking into consideration the patient's age, to excise the tongue. Accordingly Mr. Cooper removed the tongue by Whitehead's method on August 25th, 1898. The patient was discharged quite well on the eleventh day after the operation. Micro-sections show the tumour to be a spheroidal mass with a diameter of about half an inch. It is composed of small round cells, in which lie embedded a few irregular-shaped masses of the ray fungus, with characteristic club-shaped elements. In the sections, which are stained with logwood and rubin, the

Digitized by Google

tumour is represented by its peripheral zone, the central portion being absent.

The microtomist informed me (R. G. H.) that when he incised the tumour the central portion was found to contain a yellow purulent fluid, which was thrown away without examination.

October 19*th*, 1898.

2. *Congenital cyst of the base of the tongue.*

By Raymond Johnson.

The specimen exhibited consists of the tongue and adjacent parts removed from a male child aged four months. Since birth some difficulty of breathing had been noticed; this had gradually increased until severe choking fits occurred during sleep, and difficulty in swallowing was also present. When admitted to the Victoria Hospital for Children the child was pale and emaciated; there was stridor and marked recession of the lower ribs during inspiration. With a finger in the mouth a smooth, elastic swelling as large as a cherry could be felt at the back of the tongue immediately in front of the epiglottis. Tracheotomy was performed, but the child died a week later.

The specimen has been divided by a sagittal section. Occupying

Fig. 12.

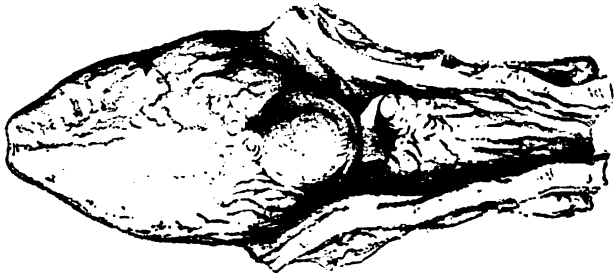

the extreme posterior part of the tongue, and placed exactly in the middle line, is a cyst, which projects on the surface as a smooth

Digitized by Google

hemispherical swelling about 1·5 cm. in diameter. The postero-inferior surface of the cyst lies in contact with the anterior surface of the epiglottis, the latter being so much pushed backwards as nearly to occlude the upper aperture of the larynx. The anterior border of the cyst lies immediately behind the circumvallate papillæ, and no indication of the position of the foramen cæcum exists.

FIG. 13.

The outline of the cyst in section is almost semicircular, the antero-inferior or deep aspect of the cyst being flattened. The lowest part of the cyst is 3 mm. distant from the hyoid bone. The inner surface is smooth, but in the centre of the antero-inferior flattened aspect of the cyst wall there is a small depression, which is the orifice of a short canal in the substance of the tongue. In the left half of the cyst some of the coagulated contents, probably mucoid in character, still remain.

Examined microscopically, the cyst is found to be lined with a thin layer of stratified epithelium, between which and the muscular tissue of the tongue, in which the cyst is embedded, is a layer of fibrous tissue forming a definite cyst wall. In the muscular substance around the cyst are the large and deeply placed mucous glands which are naturally present in the part.

Cysts in the base of the tongue may arise in the large mucous glands which open on its surface, or in connection with the upper part of the lingual duct or its glandular appendages. Cysts belonging to the latter group have been carefully investigated by Dr. Martin B. Schmidt, of Strasburg ('Ueber die Flimmercysten der Zungenwurzel und die drüsigen Anchänge des Ductus Thyreoglossus,' 1896). He describes the glandular appendages of the lingual duct as occurring in two forms: (1) Deeply placed mucous glands which open into the duct, and (2) branching tubular spaces

Digitized by Google

communicating with the duct. These tubes and the ducts of the mucous glands contain ciliated epithelium.

From these structures cysts may arise. They are usually multiple, contain mucus, and are lined with an epithelium which in part at least is ciliated. In the majority of the specimens of such cysts examined by Schmidt there was no external evidence of their presence, and the cysts were only discovered on making sections of the organ.

The occurrence of tumours—sometimes cystic—at the base of the tongue having the structure of the thyroid gland is now thoroughly established. They must be regarded as accessory thyroids developing in connection with the upper end of the thyreoglossal duct, just as such accessory thyroids are known to develop around its infra-hyoid segment.

An extraordinary case, showing that such a lingual thyroid may be functionally active, has been recorded by Seldowitsch ('Centralblatt für Chirurgie,' 1897, p. 499). The patient was a girl of 14, and the removal of the tumour was followed by the characteristic symptoms of myxœdema, which disappeared under the administration of thyroid extract. No thyroid gland could be felt in the neck, and it was assumed that the "tumour" of the tongue represented the only thyroid tissue which the patient possessed.

My own specimen is undoubtedly a mucous cyst, but from the microscopic examination it does not seem possible to decide upon its exact origin, and it is conceivable that it arose from some of the superficial or deep sets of mucous glands. Three points may, however, be noted: (1) That the cyst is seated exactly in the middle line of the tongue, immediately behind the circumvallate papillæ; (2) that no foramen cæcum is recognisable; and (3) that the cyst is single, and presents no evidence of having arisen by the confluence of smaller cysts. For these reasons I would suggest that the cyst has arisen by distension of the extreme upper part of the lingual duct. *April 4th*, 1899.

Digitized by Google

Digitized by Google

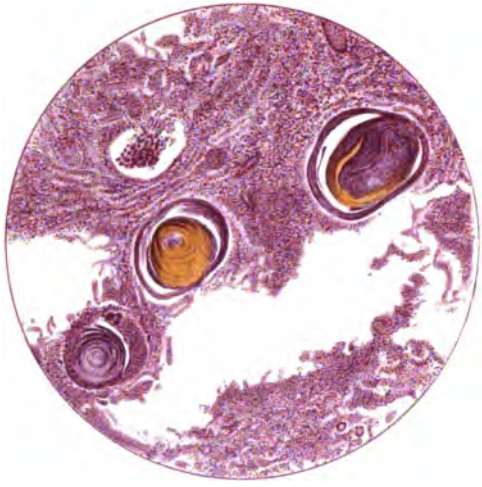

1.

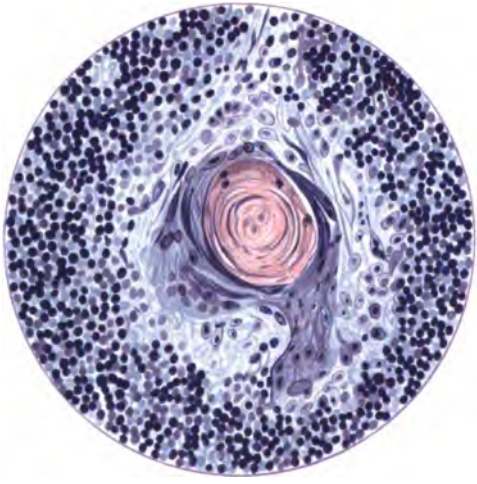

2.

Digitized by Google

DESCRIPTION OF PLATE III.

Illustrating Dr. Hugh Walsham's paper on E[illegible] of the Tonsil. (Page 65.)

Fig. 1.—Section through [illegible] of a male aged 2[illegible]. Three pearls are embedded in the adenoid substance of the tonsil. The [illegible] pearl is [illegible] [illegible].

Fig. 2.—Section through tonsil of a [illegible] 31. It shows an [illegible] pearl in the adenoid tissue of the tonsil. There is no evidence of [illegible].

Digitized by Google

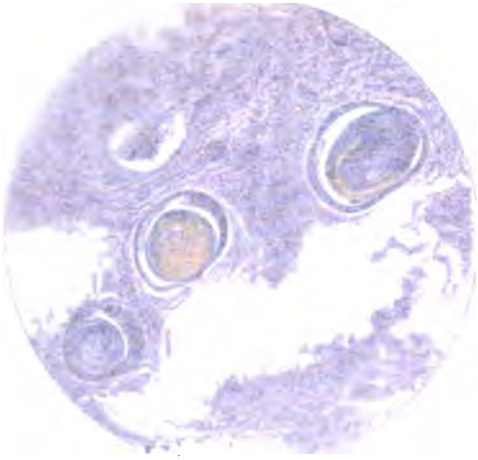

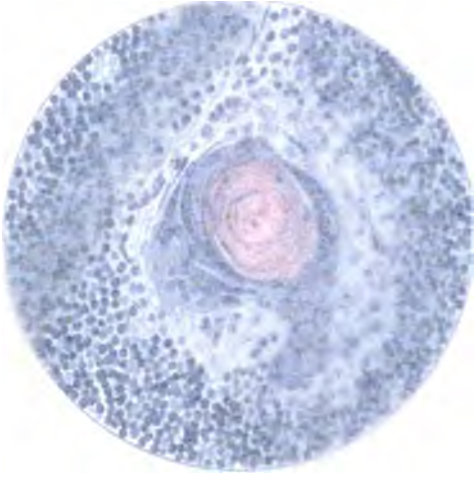

Digitized by Google

DESCRIPTION OF PLATE III,

Illustrating Dr. Hugh Walsham's paper on Epithelial Pearls in the Tonsil. (Page 65.)

FIG. 1.—Section through tonsil of a male aged 27. Three pearls are seen embedded in the adenoid substance of the tonsil. The middle pearl is partially calcified.

FIG. 2.—Section through tonsil of a male aged 31. It shows an epithelial pearl in the adenoid tissue of the tonsil. There is no evidence of calcification.

Digitized by Google

Digitized by Google

3. *Epithelial pearls in the tonsil.*

By Hugh Walsham, M.A., M.D.

[With Plate III.]

The late Professor Kanthack,[1] in a very interesting paper in the 'Illustrated Medical News' of November 9th, 1889, and also in a paper in the 'Journal of Anatomy and Physiology,' calls attention to the occurrence of epithelial pearls in the tonsils of human fœtuses and new-born infants, and points out that they occur as retentions and not as embryonic inclusions, thus differing altogether from the epithelial pearls described by Mr. Bland Sutton (in his lectures on "Evolution in Pathology"), which are found in the middle line of the palate and in other parts.

Professor Kanthack says that he has found these retention pearls also in the tonsils of young persons, the oldest being 17 years of age. Their occurrence in adults is not altogether rare, and while making some observations on the occurrence of tubercle in the tonsil I met with three very good specimens in the tonsils of men aged 27, 31, and 35 years respectively. The occurrence of these pearls in the organ is of interest, because I think there can be no doubt that they are the origin of at least some of the so-called tonsil calculi. The accompanying drawings show very clearly these interesting bodies.

Fig. 1 is a microscopical section through the tonsil of a male aged 27. Three of these pearls are seen, the middle one showing evidence of calcification. The centre of the pearls shows no definite structure; it is only on carefully examining the periphery that we see that they are composed of horny, squamous, epithelial cells pressed tightly together. They bear a close resemblance to the epithelial cell nests found in some of the squamous-celled carcinomata.

Fig. 2, from a male aged 31. The section shows another of these curious bodies, which is probably not so old as the former specimens, as the cells can be traced nearly to the middle of the

[1] Kanthack, 'Journ. of Anat. and Physiol.,' vol. xxvi.

Digitized by Google

pearl. The occurrence of these bodies, as before said, is not altogether rare, but the above are the only examples met with in 150 *post-mortem* examinations of the tonsils with reference to their occurrence.

But in addition to these epithelial pearls we find what are apparently true epithelial inclusions, which, as far as I know, have not yet been described in this country. They consist of isolated epithelial accumulations in the adenoid tissue of the tonsil. Great care is required in looking for these bodies, lest we mistake for them some portion of the epithelial lining of one of the crypts which has been cut obliquely. After uterine life we must also remember that the lymphocytes pass right amongst the epithelium, and may thus lead to fallacies. I am quite satisfied, however, that such isolated islets of epithelium do exist, resembling those epithelial accumulations which are found in the middle line of the palate, penis, and in other places.

Professor Retterer [1] has also observed these epithelial accumulations in the adenoid tissue of the tonsil, and believes they are formed by epithelial detachments from the base of the primary invagination during the development of the organ. In September, 1898, I sent a short paper to the 'Lancet,' published in April, 1899, on the occurrence of epithelial pearls in the tonsil. I said there, in reference to these epithelial accumulations, that they could not be regarded either as retention or inclusion products. I have been working at the subject since then, and I think the explanation given above to be the true one—that is, that they are true embryonic inclusions. *November 1st*, 1898.

---

4. *A tumour arising in the region of the socia parotidis.* (*Card specimen.*)

By H. D. Rolleston, M.D.

A woman, aged 56 years, had noticed a tumour in the right cheek for fifteen years. It grew steadily until a year before removal; it then increased rapidly and doubled its size. It reached

[1] Retterer, "Origine et évolution des amygdales chez les mammifères," 'Journ. de l'anat. et de la phys.,' 1888, vol. xxiv, p. 1.

Digitized by Google

the size of a small orange and projected into the mouth. On examination it had an elastic, semi-solid feel.

After removal it was found to be an encapsuled cystic tumour. The fluid from the cysts contained cholesterin, but did not give the chemical tests for mucin.

Histologically the tumour is a cystic myxo-fibro-adenoma. The cystic spaces are of considerable size and are lined by cubical epithelium, and closely resemble the cysts in common cystic fibro-adenoma of the breast. In parts the cysts contain homogeneous material. There is a fair amount of interstitial tissue; some of this is ordinary myxomatous tissue. There are also areas of closely packed cells, probably immature epithelial cells. In places the fibrous tissue is of an adult type and has undergone hyaline change. Occasionally these strands of hyaline degenerated fibrous tissue show a concentric arrangement. The structure of the tumour resembles that often seen in parotid tumours, but is more markedly cystic. *May 2nd*, 1899.

5. *Adeno-lipoma of the submaxillary salivary gland.*

By H. J. Waring, M.S.

Non-malignant tumours of the submaxillary salivary glands are uncommon, and when met with they generally have the structure of mixed tissue tumours such as those which are frequent in the parotid salivary gland. The tumour, a section of which is shown in Fig. 14, has a different structure, and was removed from the submaxillary region of a young man aged 22; it had been present for at least five years, and had grown steadily but slowly. A short time before it was removed the rate of growth had somewhat increased. The tumour, which was removed through an incision in the submaxillary region, was situated underneath the deep fascia in the submaxillary triangle, and was apparently attached to the superficial lobe of the submaxillary salivary gland, where it lies on the surface of the mylo-hyoid muscle. In shape the tumour was elliptical or egg-shaped, and in size its long axis measured two and a half inches, and its short

Digitized by Google

one, one and a quarter inches. The tumour had a distinct capsule of fibrous tissue, and was easily and readily separated from the submaxillary salivary gland and the surrounding tissues.

FIG. 14.

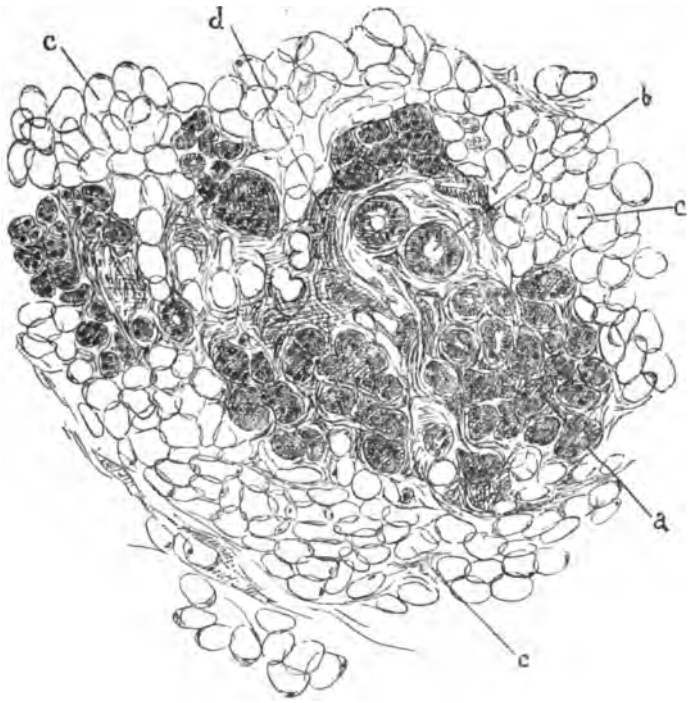

a. Glandular acini. *b*. Section of a duct. *c*. Fat cells. *d*. Connective tissue and blood-vessels.

The structure of the tumour is well shown in the figure. It consists of a basis of fatty and connective tissues, and amongst these are numerous islands of glandular tissue, which resemble to a certain extent histologically the structure of a normal salivary gland. The glandular acini are very distinct, and in places sections of what appear to be ducts are visible. Around some of the ducts there is a considerable accumulation of connective-tissue cells and fibres. *May 2nd*, 1899.

Digitized by Google

6. *Idiopathic hypertrophy of the œsophagus.*

By H. D. Rolleston, M.D.

This condition was found accidentally in the course of an autopsy on a patient of Dr. Ewart's, to whose kindness I am indebted for leave to bring the specimen forward. The patient's daughter, who had had her meals with him, was carefully questioned, and could not remember that he had ever complained of any pain or difficulty in swallowing, or that he had ever suffered from regurgitation of food after eating.

He was a man 59 years of age, who died with erysipelas and bronchitis after fractured ribs. The kidneys were red and granular. The heart, 14 ounces, showed hypertrophy of the left ventricle. There was also some hypertrophy of the prostate. The œsophagus was not increased in length or dilated in any part of its course; its lumen was not narrowed, and there was not the slightest trace of a stricture in any part of the tube. Three inches below the cricoid cartilage the circular muscular coat began to be hypertrophied; this hypertrophy regularly increased along the course of the œsophagus towards the stomach, but there was no excessive increase in this hyperplasia of the muscular coat near the cardiac orifice, such as might have been expected if there had been chronic spasm of the cardiac orifice. The œsophagus was affected right up to its entrance into the stomach. This is a point of importance as bearing on the possibility of the hypertrophy being due to spasm of the diaphragm. If there had been spasm of the diaphragm leading to œsophageal obstruction, the portion of the œsophagus below the diaphragm would not necessarily share in the hypertrophy above.

The hypertrophy was practically limited to the circular muscular coat, and microscopically no evidence of fibrosis or inflammation was found. The mucosa of the œsophagus was opaque, but was not specially affected with chronic œsophagitis. It separated readily from the underlying coats, and no sign of ulceration or growth could be found in it. There were a number of adhesions around outside of the affected part of the œsophagus, but they were

Digitized by Google

not dense or sufficient to embarrass the contraction of the œsophagus, and did not seem in any way to account for the hypertrophy of the middle coat. There was no stricture of the cardiac orifice; the stomach was rather larger than natural, but presented no gross lesion. The pyloric orifice was certainly small, but there was no morbid thickening of its walls. No morbid change in the diaphragm was noticed.

Remarks.—This remarkable condition of idiopathic hypertrophy without accompanying dilatation, to which I have failed to find any reference, appears to have given rise to no symptoms during life; it is, therefore, hardly necessary to raise the question whether it was associated with any clinical condition such as rumination of food or cardiospasm. In both these affections dilatation of the lower end of the œsophagus probably results, but it does not appear that hypertrophy occurs, though it would be natural to expect some hypertrophy as compensatory to and as a result of dilatation. That there must have been a cause, and that the hypertrophy is only apparently idiopathic, is of course true. Cardiospasm naturally at once suggests itself as a cause of this hypertrophy, but there is absolutely no proof that such a condition existed during life in this case, or even, probable as it would appear from *a priori*, that hypertrophy of the lower end of the œsophagus occurs in cardiospasm. In vol. xlvii of the Society's 'Transactions'[1] I described a case of marked dilatation of the œsophagus in a boy aged 8 years, who came of a neurotic stock. There was no organic cause, such as stricture, to account for the dilatation and hypertrophy, and I then suggested that possibly a failure in the co-ordinating mechanism, by which the cardiac sphincter is relaxed during swallowing, might by producing obstruction be the cause of the changes in the œsophagus. The non-relaxation of the cardiac sphincter might be due to paralysis or to inhibition of the longitudinal fibres of the œsophagus; in either case the circular muscular fibres would have more work to do on driving the food into the stomach, and upon this view the hypertrophy could be explained. It appears to me that this explanation of non-relaxation of the cardiac sphincter is one that may also be applied in the present case. At any rate, whatever the resistance to the passage of food was, the hypertrophy of the circular coat of the œsophagus fully compensated for it, and so no difficulty was experienced during life.

[1] Page 37.

Digitized by Google

The man was cut off by intercurrent disease before this compensatory hypertrophy failed and gave way to dilatation. This specimen is, therefore, an early stage of the condition of combined dilatation and hypertrophy of the œsophagus, of which a certain number are to be found in literature and in museums.

The subjects of this disease may live for a long time with symptoms, such as vomiting, pointing definitely to the gastro-intestinal tract, though even this is a rare condition. I am not aware that any specimen of "idiopathic" hypertrophy without dilatation has been described. *November 1st*, 1898.

---

7. *Fusiform dilatation of the œsophagus.*

By W. S. Lazarus-Barlow, M.D.

The specimen under consideration was obtained from the body of a man, aged 28 years, who died in St. George's Hospital. He was admitted nine days before death for extreme emaciation, together with epigastric pain and tenderness. The history was very indefinite, but the patient said that twelve months previously he had had "difficulty of swallowing and tubes were passed" down his œsophagus. He also stated that at that time he suffered from frequent vomiting. On admission it was found that his epigastric pain bore no distinct relation to ingestion of food, that he suffered severely from dysphagia, that ingested food was returned immediately and unchanged. The vomit was acid, and contained mucus besides the unaltered food. Bougies were passed, but no obstruction was encountered, though they entered as far as 17 inches. On the fifth day after admission laparotomy was performed, on the suspicion that there might be disease of the stomach, but nothing abnormal was found in the stomach or elsewhere. Three days later the patient died of asthenia.

At the autopsy it was found that there was a generalised miliary tuberculosis. The total amount of tubercular disease in the body was not great, and the chief seat was in the lungs, and especially in the left upper lobe. Besides implication by tubercle, the left lung

Digitized by Google

was the seat of a patchy pneumonia in the stage of red hepatisation, and the right lung was engorged and œdematous.

Over its middle five sevenths the œsophagus was dilated in fusiform fashion, and contained much slightly modified food. At the widest part the circumference was three and a half inches, corresponding to a circular tube with a diameter of one inch. The mucous membrane was shreddy, and the muscle of the tube was greatly hypertrophied. At the cardiac end the œsophagus was narrower than elsewhere, but there was nothing approaching to stenosis. Microscopically the muscle of the œsophagus had undergone no change that was not in all probability due to *post-mortem* decomposition, with exception of the hyperplasia of muscular elements. The cell protoplasm, it is true, was highly granular and the actual muscle bundles broken up in many places, but the nuclei everywhere stained well. There was no abnormal predominance of circular fibres or inferiority in numbers of longitudinal bundles. The shreddy condition of the œsophageal mucous membrane and the general absence of epithelium were in favour of the view that the muscular changes were of *post-mortem* origin. Nevertheless it must be mentioned that the autopsy was made only ten hours after death, and that death took place during the month of January.

Remarks.—The dilatation, though sufficiently marked, is by no means so great as has previously been recorded. Dilatations with circumferences of 5½ inches, 6 inches, and 6½ inches have been recorded by Barker,[1] Wardrop Griffith,[2] and Wilks and Roote[3] respectively, but the cause of the dilatation, as in other recorded cases, is quite uncertain. Rolleston[4] has suggested that possibly that stenosis on the distal side of the dilatation and hypertrophy which is apparently demanded by the fundamental laws of pathology governing dilatation and hypertrophy, may be relative rather than actual, and may depend upon a faulty contraction of the longitudinal muscle bundles at the lower end of the œsophagus by which its dilatation is normally brought about. Langley[5] has also recently shown that stimulation of the vagus

[1] Barker, 'Trans. Path. Soc.,' vol. x, 1859, p. 141.

[2] Wardrop Griffith, 'Med. Chron.,' Nov., 1898.

[3] Wilks and Roote, 'Trans. Path. Soc.,' vol. xvii, 1866, p. 138.

[4] Rolleston, 'Allbutt's Syst. of Med.,' art. "Diseases of the Œsophagus."

[5] Langley, 'Journ. of Physiol.,' vol. xxiii, 1899.

Digitized by Google

leads to dilatation of the lower end of the œsophagus in the cat. It therefore seemed advisable in the present case to investigate the condition of the vagus, and Dr. O. F. Grünbaum made sections of the nerve in various parts of its course in order to determine if possible whether there were present signs of recent or of old degeneration. So far as can be seen, there is no definite evidence that the nerve was abnormal; nevertheless it is difficult to describe it as normal, though the greatest care was taken in its preparation, because the fibrous tissue which would fill up the former seats of nerve fibrils if there were degeneration of old standing, would be impossible to distinguish from the connective tissue already present between the individual bundles of nerve fibrils.

The specimen is preserved in the museum of St. George's Hospital, No. 5081. *February 7th*, 1899.

---

8. *Myoma of the œsophagus.* (*Card specimen.*)

By H. D. Rolleston, M.A., M.D.

A small white tumour growing in the submucosa and rather more adherent to the muscular than to the mucous coat. It was about the size of a cherry, and microscopically was a pure leiomyoma. It was probably derived from the circular muscular coat. It was situated at the junction of the upper and middle thirds of the œsophagus in a woman, aged 49, who died of influenzal broncho-pneumonia. It had not given rise to any clinical symptoms. There were no uterine myomata. *March 7th*, 1899.

---

9. *Minute erosion* (*exulceratio simplex*) *of the gastric mucous membrane.* (*Card specimen.*)

By H. D. Rolleston, M.A., M.D.

An anæmic woman, 25 years of age, who had suffered from vomiting after meals for three weeks, was admitted under my care at St. George's Hospital two days after bringing up 3 ounces

Digitized by Google

of blood. On examination the abdominal muscles were flaccid and a pulsating aorta was felt, but there was no tenderness on exerting pressure over the stomach. I was inclined to regard the case as one of gastritis rather than gastric ulcer, and the patient was therefore allowed milk and beef tea by the mouth. Two days after admission she brought up as much as two and a half pints of blood. After this she was fed entirely *per rectum*, and went on well until eight days later, when she quite suddenly died.

At the *post-mortem* death was found to have been caused by pulmonary embolism, the source of the embolus being thrombosis in the left external iliac vein which had not attracted any attention during life. The stomach shows two small elongated abrasions of the mucous membrane measuring not more than a quarter of an inch in length by one eighth of an inch in breadth. Both these erosions are close to the lesser curvature, one on the anterior, the other on the posterior surface of the stomach, about 2 inches from the œsophageal opening. These abrasions are therefore opposite to each other. That on the posterior surface has opened into a vessel, and from it no doubt the hæmorrhage came. The other abrasion on the anterior surface is for the most part cicatrised. There was no varicosity of the gastric veins.

This superficial erosion of the gastric mucous membrane has recently been specially described by Dieulafoy,[1] who gave the name exulceratio simplex to this condition, which he regards as an early stage of the ordinary gastric ulcer, and by Lindsay Steven,[2] who had two fatal cases of profuse hæmatemesis from this lesion which he terms "pore-like" erosion of the gastric arteries. Dieulafoy had seven cases, and Lindsay Steven[2] refers to previous cases belonging to this category recorded by Murchison (in vol. xxi of this Society's 'Transactions'), Chiari, and Ferrand. Deguy[3] has recently described a small superficial abrasion eight tenths of a millimetre in a man who died of hæmatemesis, and who had latent hepatic cirrhosis. From these cases it appears that the hæmorrhage is extremely profuse, and that it has been directly fatal, while other signs of gastric ulceration may be absent.

If, as seems not unlikely, this lesion is the first stage of an ordinary gastric ulcer, it must be common, but it may be so small

[1] Dieulafoy, 'La Presse Médicale,' Jan. 19th, 1898.

[2] Lindsay Steven, 'Glasgow Med. Journ.,' vol. li, p. 5, Jan., 1899.

[3] Deguy, 'Bull. Soc. Anat.,' Paris, Dec., 1898.

Digitized by Google

as to be overlooked, when it proves fatal, and often, of course, goes on to the further stage of a deep ulcer. *March 21st*, 1899.

---

10. *Gastric ulcer from a patient with granular kidneys.* (*Card specimen.*)

By H. D. Rolleston, M.D.

The whole stomach was very greatly engorged. Surrounding the pylorus there was a recent ulcer 2 inches by 1 inch. Microscopically the vessels on the floor of the ulcer were much dilated and full of blood; in places there were small hæmorrhages into the submucous coat. There was no pigmentation, however. There were some hæmorrhages into the mucous membrane of the ileum, but no ulcers there. From a woman aged 37 years, who had granular kidneys, and small aneurysms on the splenic (*vide* p. 55) and right middle cerebral arteries.

Remarks.—The ulcer was recent, and it appears probable that it may have been brought about as the result of hæmorrhage taking place into the mucous and submucous coats of the stomach, the hæmorrhage being analogous to retinal hæmorrhages. This form of ulceration was described by Dr. W. H. Dickinson, who in his paper in the 'Transactions' of the Royal Medical and Chirurgical Society (vol. lxxvii, p. 111, 1894) found, in the course of forty years' experience of *post-mortem* examinations at St. George's Hospital, twenty-two cases of ulceration of the intestines and three examples of gastric ulcer in chronic nephritis. There is no reason why renal disease should protect the patient from ordinary gastric ulcer, but I am rather inclined to regard the recent ulcer in this case, associated as it was with hæmorrhage into the submucous coat, as definitely related to the renal disease, and not as a mere coincidence. *March 7th*, 1899.

Digitized by Google

11. *Tubercular ulcer of the stomach in children.*

By George F. Still, M.D.

Tubercular ulcer of the stomach is an occurrence of considerable rarity, and very few cases have been recorded by English writers. I venture, therefore, to show specimens of this condition taken from five cases which I have met with at the Hospital for Sick Children, Great Ormond Street.

In three of these cases a microscopic examination was made, and the typical appearances of tubercular ulceration with characteristic giant-cells were found, and in two cases tubercle bacilli were demonstrated in the base of the ulcer. In the remaining two cases no microscopic examination was made, as it was desired to preserve the specimens for the museum, but the naked-eye appearances were such as to leave, I think, no doubt whatever that these also were tubercular ulcers.

Case 1.—George P—, aged 3½ years at death. Seven months previously ascites and œdema of the legs appeared, and there was some vomiting. Paracentesis abdominis was done three times, but the abdomen remained very full and resistent, and although fluid did not reaccumulate after the third tapping, the abdomen had the doughy feeling of tubercular peritonitis on palpation. There was occasional vomiting throughout the illness, sometimes on several consecutive days, but sometimes only after an interval of two or three weeks. Pulmonary symptoms developed, the child gradually emaciated, and after seven months' illness died. With the exception of the vomiting, which may have been due to the tubercular peritonitis, there were no symptoms pointing specially to gastric ulcer.

Post-mortem.—There was extensive tubercular peritonitis with adhesions. There was some tubercular ulceration of the lower part of the ileum and just below the ileo-cæcal valve, but no ulceration higher up in the small intestine. The stomach was adherent to the liver and to the surrounding structures; it was not noticeably dilated. On the posterior wall of the stomach just below the lesser curvature, about 4 cm. to the left of the pylorus.

Digitized by Google

was a small ulcer somewhat irregular in shape, and about 2 mm. in width at its widest part. Its edges were hardly definitely thickened, and the ulcer was so small that it was difficult to judge of the character of its base, but it was evident that the ulceration extended deeply, though not actually exposing the muscular layer. Some lymphatic glands along the lesser curvature of the stomach were enlarged and caseous. There was extensive tuberculosis of the lungs and of the mediastinal and mesenteric glands.

Microscopic examination showed an area of small round-cell infiltration, with several giant-cells in the submucosa, forming the base of the ulcer over which the mucous membrane had disappeared. The area of inflammation undermined the mucosa for a short distance at the edge of the ulcer, and here there was some round-cell infiltration of the mucosa itself. The muscular coat was normal. In the subperitoneal tissue outside the muscular layer several small foci of tubercular deposit were seen. Two or three tubercle bacilli were found in the base of the ulcer after carefully searching through several sections.

Case 2.—John L—, aged 10 months at death. After four weeks' illness with cough he showed signs of consolidation in the lungs, and then symptoms of tubercular meningitis supervened, and he died five and a half weeks after the onset of the illness. Vomiting was frequent during the last ten days of life, but there was nothing otherwise which might have suggested gastric ulcer, and the vomiting may have been entirely due to the meningitis.

Post-mortem.—There was general miliary tuberculosis affecting the meninges, lungs, and almost every organ in the body. There was no definite peritonitis, and no peritoneal adhesions. Only four tubercular ulcers were found in the ileum. The stomach showed on the lesser curvature about 1·5 cm. from the pylorus a small ulcer, roughly circular in shape, about 3 mm. in diameter, with the edges thickened and vascular. No tubercle could be seen on the peritoneal surface.

Microscopic examination showed a small area of round-cell infiltration forming the base of the ulcer in the submucosa, and slightly invading the mucosa at the edge of the ulcer. The vessels of the submucous layer in the neighbourhood of the ulcer were dilated. The muscular coat was normal, and no tubercular deposit was seen in the subperitoneal tissue.

Digitized by Google

No giant-cells were found in the base of the ulcer, but very numerous tubercle bacilli were present here, their large number contrasting markedly with the scarcity of bacilli in Case 1 and in the following case.

Case 3.—Elsie W—, aged 3½ years. The abdomen had been enlarged for two years, and there had been occasional vomiting. On admission the abdomen was full and resistent, and there were signs of consolidation in both lungs. The child gradually became emaciated, symptoms of tubercular meningitis supervened, and death occurred nearly four weeks after admission to the hospital. While the child was under our observation there was only occasional vomiting, and nothing otherwise to suggest gastric ulcer.

Post-mortem.—In addition to some tubercular meningitis and a caseous mass in the right optic thalamus, and some not very advanced tuberculosis of the lungs, there was much tubercular peritonitis with adhesions completely obliterating the peritoneal cavity. Examination of the intestine was difficult owing to the matting, but the greater part of the small intestine and almost all the large intestine was examined, and only one slight erosion was found in the ileum, none elsewhere. The stomach was adherent to the liver and to the surrounding structures. It was normal in size. A small ulcer, about 2 to 3 mm. in diameter and circular in shape, was found about 1·5 cm. below the cardiac orifice on the posterior wall of the stomach. Its edges were thickened; it seemed to pass through the submucosa, but not through the muscular wall. On the outer surface, which was here closely adherent to the diaphragm, there was a small caseous plaque. Another much more superficial erosion, with some vascularity of the surrounding mucous membrane, was present about 3·5 cm. nearer to the pylorus on the lesser curvature. Microscopic examination showed an area of round-cell infiltration in the submucosa forming the base of the ulcer, and extending partially through the muscular layer. At the margin of the ulcer there was also some slight infiltration of the deeper part of the mucosa. Giant-cells were present in the base of the ulcer, but careful search revealed only one very doubtful tubercle bacillus.

Case 4.—Daniel P—, aged 2 years and 8 months. There had been vomiting, with gradual emaciation, and enlargement of the

Digitized by Google

abdomen for two months. There had also been some tenderness of the abdomen, which on admission was full and unduly resistent. With the exception of the vomiting, and possibly the tenderness of the abdomen, there were no symptoms specially pointing to ulceration of the stomach. The child died three days after admission to the hospital, and during that time there was no vomiting.

Post-mortem.—There was extensive tuberculosis of the lungs and other organs, not of the acute miliary type, but rather chronic, with a tendency to caseation. Early tubercular peritonitis was present, with some adhesions, and probably also some superadded acute septic peritonitis due to perforation of a tubercular ulcer in the ileum, which had allowed fæces to escape into the peritoneal cavity. The small intestine was extensively ulcerated as high up as the lower part of the duodenum.

The stomach was not noticeably dilated. Close to the lesser curvature and situated halfway between the cardiac orifice and the pylorus on the posterior wall was a tubercular ulcer with its long axis parallel to the upper border of the stomach, and measuring 1·5 cm. transversely and nearly 1 cm. from above downwards. Its edges were thickened, but less than usually happens in a tubercular ulcer of the intestine (a feature of the gastric tubercular ulcer to which the late Professor Coats [1] drew attention), and its base was of a yellowish grey colour, and rough. On the peritoneum outside the ulcer a grey tubercle was seen. No microscopic examination was made as the specimen was preserved for the museum.

Case 5.—James T—, aged 9 years. Two years ago he suffered with vomiting and diarrhœa; subsequently a serous pleural effusion occurred on one side of the chest, and later still the abdomen became full and resistent; there was gradual emaciation, and some vomiting two months before death, but none later, and no other symptoms pointing to gastric ulcer.

Post-mortem.—There was extensive tuberculosis of almost all the organs. The peritoneal cavity was completely obliterated by adhesions, with much caseous material in the adhesions. Both the small and large intestines were much ulcerated. The stomach showed on the lesser curvature, near the cardiac opening, a small cicatrix, the external surface here being closely adherent to the liver. It seemed probable that it was the scar of a tubercular ulcer. Just below

[1] 'Glasgow Med. Journ.,' 1886, p. 54.

Digitized by Google

the lesser curvature, near the pylorus on the posterior wall was a small ulcer about ·5 cm. in diameter, round, with slightly thickened edge, and roughened base, which did not expose the muscular layer. Between this and the cardiac opening was another depression on the anterior wall of the stomach, and at the bottom of this depression was a small perforation through which a probe passed into dense adhesions outside the stomach. The specimen was preserved for the museum, so no microscopic examination was made.

These five cases of tubercular ulcer of the stomach are the only cases I have met with in 206 autopsies on children with abdominal tuberculosis, or in 226 tubercular cases if those be included in which the abdomen was not affected.

The statistics of other writers show a similar rarity; including all varieties of tuberculosis in children, Widerhofer (1) found tubercular gastric ulcer twice in 418 cases, Steiner and Neureutter (2) four times in 302 autopsies, Rilliet and Barthez (3) 21 times in 141, and more recently Holt (4) found gastric ulcer 5 times in 119 cases, but states that the evidence was not conclusive in all of them that the ulcers were tubercular.

Unfortunately in several of the published cases and statistics no satisfactory evidence of the tubercular nature of the ulcer has been given, so that some doubt attaches to them. Occasionally in children with tuberculosis ulceration of the stomach is present, which on microscopic and bacteriological examination shows no evidence of a tubercular nature, any case therefore which has not been verified thus must be received with caution. Two of my cases are open to this objection, but, as I have already stated, the naked-eye appearances were such as to leave little doubt that they were really tubercular.

Only two cases of tubercular ulcer of the stomach have been recorded in the Transactions of this Society (5), both in adults. A case of ulceration of the stomach in a female infant aged twenty-one months, who died with tuberculosis, was described by Dr. Barlow (6), but he considered it by no means certain that the ulcers were really tubercular, and stated that he had seen three other similar cases in children where the nature of the ulcer was thought to be doubtful. A very similar case was recorded by Rehn (7) in an infant aged twenty-one months with tuberculosis,

Digitized by Google

where microscopic examination of the ulcer showed no evidence of tubercle.

In addition to the cases mentioned above I have been able to find only four cases (8) recorded of tubercular gastric ulcer in children; two of these were verified by microscopic examination.

As regards the age at which tubercular gastric ulcer is most often found, it seems probable from the number of cases recorded in children that it is less rare in children than in the adult; and it occurs probably more often in infancy and in the earlier years of childhood than in later childhood. Four out of my five cases were in children under the age of four years, one at the age of ten months, and Holt mentions that four out of his five cases of gastric ulcer in tuberculosis were in infants.

Four out of my five cases were males. One can hardly attach any significance to such small numbers, but so far as they go they agree with the observation of Rilliet and Barthez, who found that fourteen out of twenty-one were males. This predominance of the male sex may perhaps be related to the frequency with which tubercular ulcer of the stomach is associated with tubercular peritonitis, a condition which statistics show to be considerably more frequent in males than in females.

Vomiting was present in all my cases, but as tubercular peritonitis was present in four of them, and tubercular meningitis in the remaining one, no special importance could be attached to the vomiting as a symptom of the ulceration. Tenderness in the abdomen for the same reason had no special significance. It could not, indeed, be said that there was any clinical evidence of the gastric ulcer in these cases, and this absence of symptoms is noticeable in the other recorded cases, with the exception of one recorded by Bignon (8), in which a girl, aged six and a half years, with general tuberculosis, had fatal hæmatemesis from a gastric ulcer thought to be tubercular, and one recorded by Cazin (quoted by Holt, loc. cit.), in which a tubercular ulcer caused perforation of the stomach and acute peritonitis. In Case 4 recorded here, one of the ulcers had perforated the stomach, but without producing peritonitis, as the opening was blocked by dense adhesions between the stomach and the surrounding structures. In such a case it is difficult to be sure whether the perforation was from within or from without. In some cases, as in that recorded by Dr. Newton Pitt, in an adult, and another mentioned by Dr. Wilson Fox (9), a caseous

Digitized by Google

gland or deposit outside the stomach becomes adherent to the outer surface of the stomach and perforates by ulceration from without; and in the specimen shown from Case 4 it will be seen that there are numerous caseous deposits in the adhesions on the outer surface, one of which might in this way have produced the perforation, but the presence in this case of another ulcer which has not yet reached the outer surface is opposed to this view.

The position of the ulcer in all the five cases recorded here was on or near the lesser curvature, and in all it was on the posterior wall, but in one there was also ulceration on the anterior wall. Rilliet and Barthez (loc. cit.), on the contrary, state that these ulcers are usually situated on the greater curvature.

In four out of my five cases there was tubercular peritonitis, and in all the intestine showed more or less ulceration; but it is noteworthy that the ulceration in the intestine was only slight in two of them, while in one it was particularly noted that the ulceration was limited to the neighbourhood of the ileo-cæcal valve. It would appear, therefore, that the occurrence of tubercular ulceration of the stomach bears no relation to the extent of ulceration of the intestine.

In the microscopic specimens shown from Cases 1, 2, and 3, the tubercular process seems to have started in the submucous tissue, and the mucosa can be seen to be undermined by the caseous area at the edge of the ulcer.

It is difficult to be certain whether the tubercular infection of the wall of the stomach occurs from without or from within. In the three cases examined microscopically there is certainly no direct extension from the peritoneal surface, but, as already mentioned, this probably occurs in some cases. In others, no doubt, the infection is from within, *i. e.* from the contents of the stomach, especially tubercular material, coughed up from the lungs and then swallowed; and it may be that peritoneal adhesions by impeding the movements of the stomach predispose to such a mode of infection. In others, again, as in Case 2, where the ulcer occurs in association with acute miliary tuberculosis, it is probable that the deposit of miliary tubercle in the wall of the stomach is simply part of a general blood infection.

In all the five cases recorded here, as in those which I have been able to find recorded elsewhere, there was extensive tuberculosis in many organs of the body. Moreover, while the tubercular

Digitized by Google

lesions elsewhere were advanced, the ulcers in the stomach have usually been quite small, a fact which suggests that the gastric ulceration is quite a secondary and a late phenomenon. It seems at any rate clear in these cases that the gastric ulcer cannot be regarded as the primary channel of infection.

REFERENCES.

1. Gerhardt's 'Handbuch der Kinderkrankheit.,' iv, 2, 443.
2. *Steiner u. Neureutter.*—'Prager Vierteljahresschrift,' 1865, Bd. ii.
3. *Rilliet and Barthez.*—'Maladies des enfants.' Paris, 1843, iii, 437.
4. *Holt.*—'Diseases of Infancy and Childhood.' London, 1897, p. 304.
5. 'Path. Soc. Trans.,' xxxix, p. 107 (Pitt), and xlv, p. 73 (Habershon).
6. *Barlow.*—'Path. Soc. Trans.,' xxxviii, p. 141.
7. *Rehn.*—'Jahrb. für Kinderheilk.,' 1874, p. 19.
8. *Bignon.*—'Bull. de la Soc. Anat.' Paris, 1853, vi, 211.
9. *Wilson Fox.*—'Reynolds's System of Medicine,' vol. ii.

Other references are: *Barbacci*, 'Lo Sperimentale,' lxv, 1890 (a good epitome of literature); *Talamon*, 'Progrès médical,' 1879, iii, 46; *Bednar*, 'Krankheit der Neugebor. u. Säugling.,' t. cxvi; *Blumer*, 'Albany Med. Annual,' March, 1898 (thirty cases collected from literature).

May 2nd, 1899.

---

12. *A specimen of tubercular ulceration of the stomach from a child.* (*Card specimen.*)

By T. D. LISTER, M.D.

ON the posterior wall of the stomach the mucous membrane shows numerous tubercular ulcers of various sizes. The largest is situated at the cardiac end and is about a quarter of an inch long, with deeply undermined edges. Close to it is another, about one eighth of an inch long, and scattered along the course of the vessels are other smaller ulcers, some being mere raised nodules with a tiny central perforation. In this specimen the ulcers are all situated in close relation to the vessels. This was more readily seen in the recent state, when the thick or nodular edges of the ulcers and their central translucent bases were very

Digitized by Google

obvious on holding the well-washed organ up to the light spread out on a piece of glass or stretched in the fingers, all the ulcers being seen close to the larger arborescent arteries.

Microscopically the bases of two of the ulcers showed giant-cells, two of the smaller ulcers having been excised for the purpose, and the holes sutured as is seen in the naked-eye specimen.

Abstract of case.—Timothy D—, aged 1 year 10 months, was admitted to the East London Hospital for Children, on April 21st, 1897, with a history of six months' diarrhœa and fourteen days' cough and dyspnœa. The patient was very wasted, presented the physical signs of broncho-pneumonia, and died soon after admission.

At the autopsy the condition already described was found. The intestines showed very numerous tubercular ulcers, some of very considerable size, scattered through the intestinal tract. The liver exhibited very numerous tubercles, some as large as peas, containing deeply bile-stained, caseous *débris*. The mesenteric glands were caseous, and some were breaking down centrally. The lungs were full of grey tubercles, the mediastinal glands were large and caseous, and there were numerous subcapsular and interstitial grey tubercles in the spleen and kidneys.

Comment.—The occurrence of specific ulceration of the stomach in acute generalised tuberculosis would seem to be less uncommon than is generally thought, though the smaller ulcers are readily overlooked. In thirty cases examined by my predecessor (Dr. Rake) and his *locum tenens* at the East London Hospital for Children one example was found, and the specimen was preserved. During the last two years, my attention having been drawn to this subject by that specimen, I have examined forty-two cases of acute tuberculosis in children, and have found ulceration of the stomach in four. The five cases of which I have a record are as follows:

(1) Dr. Rake's specimen, Maud H—, aged one year 9 months. Large ulcers on posterior wall.

(2) The case here described, Timothy D—, 1 year 10 months. Small ulcers on posterior wall.

(3) (P. M. Bk., I, 615), Mary C—, 2 years. One small ulcer on anterior wall.

(4) (P. M. Bk., I, 809), Edward S—, 9 months. Six ulcers, four close together on anterior wall.

(5) (P. M. Bk., II, 94). Daisy W—, 4 months. One small ulcer on posterior wall near pylorus.

Digitized by Google

No. 5 was the only doubtful case, and was confirmed microscopically as well as (2) the slides being shown.

The history of the present case and the advanced morbid appearances found in the gastro-intestinal tract and liver (as compared with those elsewhere, which seemed to be of a later date) would seem to point fairly definitely to a tubercular infection by way of the digestive organs.

REFERENCES.

Coats.—'Glasgow Med. Journ.,' xxvi, 1886.

Blackader, quoted in 'Starr's Text-book,' i, 452, says, "Tubercular ulcers are often multiple."

Steiner and Neureuther, quoted by Rehn, 'Jahrb. f. Kinderh.,' 1874, S. 1 (4 cases in 302).

Widerhofer, quoted in 'Gerhardt's Handb.,' vol. iv, S. 444 (2 cases in 418).

Rilliet and Barthez.—'Traité des Malad. de l'enfance,' vol. iii, 1262 (21 in 141 cases).

Hamilton.—'J. Hopkins Hosp. Bulletin,' April, 1897 (3 cases).

Kundrat.—'Gerhardt's Handb. d. Kinderk.,' iv.

Serafini.—'Ann. Clin. dell. Ospedal. degl' Incurab.,' Naples, 1888.

Litten.—"Tuberc. Ulcer. of Stomach," Virch. Arch. lxvii, 1876.

Blümer.—'Albany Med. Ann.,' March, 1898 (18 cases: 14 males; 24 cases, multiple in 12).

Henkel.—'Gaz. hebdom. de Méd. et de Chir.,' March 31st, 1898 (bacteria in ulcers, streptococci).

May 16th, 1899.

---

13. *Myoma of the stomach.* (*Card specimen.*)

By ALEXANDER G. R. FOULERTON.

THE specimen was met with in the course of an operation on the gall-bladder, by Mr. Bland Sutton, in a woman aged 50. The tumour was situated in the posterior wall of the stomach, not very far from the pylorus, and was removed by an incision through the mucous membrane after the viscus had been opened. The tumour is round in shape, and measures 2·3 cm. in diameter. It

Digitized by Google

is of a firm consistence and white in colour. Histologically it consists of unstriped muscle, without any admixture of fibrous tissue. *February 21st*, 1899.

---

14. *Congenital hypertrophy of the pylorus.*

By GEORGE F. STILL, M.D.

CONGENITAL hypertrophy of the pylorus is so obscure in its pathology that any addition to the number of cases on record is perhaps worth making, in the hope that some light may be thrown on this condition. It is rather with this object of increasing the available facts than with the intention of propounding any new theory of causation that I venture to record here three cases which I have examined *post mortem* at the Hospital for Sick Children, Great Ormond Street.

CASE 1.—Richard W—, aged 12½ weeks at death. A fine baby at birth, and thought to be healthy until the end of the sixth week of life, when he began to vomit. Before this, however, the child used to regurgitate some of its feeds every day, but mother thought this was natural. Was fed on breast only until nine weeks old. Since six weeks old wasting, vomiting after nearly every feed, apparently some pain in abdomen soon after taking breast.

On admission to hospital child extremely weak and wasted, with depressed fontanelle, and muco-pus on cornea; he improved, however, in spite of several convulsions and daily vomiting, usually of very small amounts and less than the food taken. Several kinds of food were tried in various amounts and at various intervals, but with little or no effect on the vomiting; partial rectal feeding was also tried, but with little advantage as the bowels worked frequently. There was no constipation. The temperature during the last ten days of life was continuously subnormal. Abdomen was flat and supple, and during the last few days before death a tumour suggesting a thickened pylorus was felt in the right hypochondrium. Death occurred two and a half weeks after admission.

Digitized by Google

Post-mortem.—The stomach was normal in position and shape. It measured from cardiac end to pylorus 9·5 cm., from lesser curve to greater 5 cm., and was therefore not obviously larger than normal. The whole of the stomach wall was thicker than normal, and the thickening of the muscular coat became very marked about 4·5 cm. on the cardiac side of the pylorus, and increased gradually up to the pylorus.

The most striking change was the great thickening of the pylorus, which formed an almost tumour-like enlargement of that portion of the stomach; it felt, indeed, very like a pylorus affected with scirrhus. The lumen of the pylorus was more than 3·5 mm.; as it admitted easily a probe with that diameter, it could hardly have been less than 4 mm. The wall of the pylorus on section was 7 mm. thick, the muscular part being 5 mm., and the mucosa and submucosa together 2 mm. The stomach wall about 4 cm. from the pylorus was 3 mm. thick, and at the cardiac end was 2 mm. thick. The thickening of the pylorus terminated abruptly on the duodenal side, the thin wall of the duodenum contrasting markedly with the hypertrophied pylorus. There was no ulceration of the mucous membrane, but some *post-mortem* digestion had commenced in the gastric mucosa. The œsophagus seemed normal.

The only other congenital abnormality found was that the second and third toes were webbed together in both feet nearly up to the proximal interphalangeal joint, but such webbing of these particular toes is so common that no great importance can be attached to it.

Case 2.—Albert L—, æt. 14 weeks at death. Fine child when born, and seemed perfectly healthy till six weeks old; before this there was not the slightest regurgitation of food; then began to vomit, usually large quantities after intervals of several hours. Constipation troublesome since onset of vomiting. Breast feeding, with addition of some condensed milk owing to large appetite, until eight weeks old; then various methods of feeding were tried, sometimes diminishing the vomiting for a time, but not permanently.

The mother herself noticed peristalsis of the stomach when the child was three months old.

On admission to hospital, child much wasted, abdomen slightly full, marked peristalsis, evidently of stomach, from left to right,

Digitized by Google

visible in epigastrium; apparently no pain. Peristalsis increased during the last two weeks of life, and on the day before death the hard pylorus could be very distinctly felt in the right hypochondrium. Temperature was subnormal, there was almost daily vomiting, the bowels were regular; the child became gradually weaker, and died after being in the hospital fifteen days.

Post-mortem.—The stomach was slightly but distinctly dilated, and there was evident hypertrophy of its wall. The position of both stomach and pylorus seemed to be normal. Towards the pylorus the thickening of the wall was more marked, and increased gradually up to the pylorus, which was considerably thickened and hard, almost as if cartilaginous, to the touch. The circumference of pylorus was 4·75 cm., length 2·5 cm. The wall was 5 mm. thick, and the thickening was evidently muscular; the mucous membrane, which was thrown into longitudinal folds by the contraction of the pylorus, was not thicker than normal. The lumen was perfectly patent, and was over 3·5 mm. in diameter.

The œsophagus was probably thicker than normal, the muscular layer being increased. The mucous membrane was normal. The duodenum was normal.

No other congenital abnormalities were found, except that the skull was markedly asymmetrical.

Case 3.—John N—, æt. 14 weeks at death. Was thought to be quite healthy till three weeks old; the mother said there was no vomiting before this, but on further questioning said that there had been some regurgitation of food which was thought to be natural, since the child was seven days old. Began to vomit almost all his food when three weeks old, and this had continued ever since, with slight temporary improvement each time the food was altered. At first the vomit consisted of food only, but after a few weeks it contained "phlegm and slime," and occasionally a streak of blood. The child was suckled one week, and then had milk with barley-water, and then various foods in the hope of controlling the vomiting. The bowels were costive; there had never seemed to be any abdominal pain, but the child cried often just after vomiting. Latterly there had been wasting, and the child seemed very collapsed sometimes. There had been one convulsion at nine weeks old.

On admission to hospital, child emaciated, with eyes sunken and

Digitized by Google

fontanelle depressed. There was visible peristalsis of the stomach from left to right, and the lower edge of the stomach was about three quarters of an inch above the umbilicus. A hard tumour could be distinctly felt in the region of the pylorus. Vomiting persisted after almost every feed; the temperature was subnormal. There was a marked diminution of the vomiting when nasal feeding was begun five days before death, but the child was now extremely feeble, the bowels had become loose, and death occurred on the tenth day after admission.

Post-mortem.—The stomach and pylorus seemed to be in the normal position. The stomach was little if at all dilated; its wall was thickened, the thickening being evidently muscular and increasing towards the pylorus; it contained some partially digested milk with a good deal of mucus. The pylorus could be felt distinctly through the abdominal wall before opening the body, and when exposed felt quite like a pylorus infiltrated with firm malignant growth, but on section it was evident that the thickening was muscular, and that the increase of muscle was mainly in the circular layer. The diameter of the pylorus was 1·4 cm., its length was 2·4 cm.; the muscular portion of the wall was 4·5 mm. thick; its lumen was normal, admitting a probe with diameter 3·5 mm. easily. The condition of the mucous membrane was uncertain, as some *post-mortem* digestion had occurred.

The cardiac orifice was normally patent, but the œsophagus, especially at its lower end, was distinctly hypertrophied. The upper few inches of duodenum, compared with that of an infant eleven months old, seemed to be a little thicker than normal.

The right kidney showed considerable dilatation of the pelvis, and the upper two inches of the ureter were also slightly dilated; no cause whatever for the hydronephrosis could be found. The bladder was normal, and the other kidney was normal.

The microscopic appearances of the pylorus in these three cases were so similar that one description may well serve for them all. The increase in thickness is almost if not entirely limited to the muscular coat, and the part of the muscular coat in which the increase has chiefly occurred is the circular layer. From the actual micrometric measurements given below it will be seen that the longitudinal layer was actually within the limits of normal thickness in Cases 1 and 2, while in Case 3 it was distinctly beyond

Digitized by Google

the normal limit, though here also the main increase is in the circular coat.

There is no definite increase of fibrous tissue, but the bundles of muscle-fibres in the circular layer are perhaps rather more distinctly marked off by the fibrous trabeculæ than is common in the normal pylorus.

The submucosa in Cases 1 and 2 was normal in thickness; in Case 3 it was about twice the normal thickness. I have been unable to satisfy myself that there was any particular "condensation" of the fibrous tissue here.

The mucosa was normal in thickness, so far as could be ascertained, in all three cases. There was no evidence of inflammatory infiltration past or present.

The serous layer was not thickened in any of the cases.

In considering the morbid anatomy and pathology of congenital hypertrophy of the pylorus, it seemed to me of importance that a fuller study of the normal pylorus should be made; for so far as I have been able to ascertain, there is only one published record of accurate measurements of the several layers of the pylorus in the normal infantile stomach,[1] and as the writer records only one observation, there is very little material on which to base any statements of relative hypertrophy of the various layers. I have, therefore, examined carefully and made micrometric measurements of the pylorus in eight infants within the first year, and these I have tabulated below.

The specimens were hardened in Müller's fluid and cut with a freezing microtome in the ordinary way by my friend Dr. Crowley, now of Bradford. The method of preparation, therefore, entailed some shrinkage, and consequently the measurements must not be compared with the fresh specimen; but as all the sections were prepared in the same way, they are of some value both for comparison with each other and with the hypertrophied pylorus prepared in the same way.

From these measurements the following points are evident:— First, that there is considerable variation in the thickness of the wall of the normal pylorus. In making a large number of *post-mortems* on infants one has been struck with this variation. It is by no means uncommon to find a pylorus considerably thicker and

[1] Gran, 'Jahrb. f. Kinderheilk.,' xliii, i, 118.

Digitized by Google

firmer than the average, in cases where there has been nothing to suggest anything wrong with the stomach during life. And such variation is, I think, not merely a question of muscular contraction or relaxation, there is some actual increase of muscle tissue. This conclusion from naked-eye observations is confirmed by the measurements given below; thus in one child, aged 5 months, the wall of the pylorus was 1·7 mm. thick, while in another of the same age it was 2·6 mm. In one child of 10 months the whole thickness was 2·4 mm., in another at the same age it was 1·5 mm. In view of this normal variation (and I regret that I cannot bring forward larger statistics, from which we might deduce the limits of normal thickness), it is evident that slight degrees of hypertrophy are very difficult to determine, and must be received with extreme caution.

Secondly, the variation in the thickness of the normal pylorus is mainly due to a variation in the thickness of the circular muscle. For instance, in one infant aged 4 weeks the thickness of the pylorus was at least 1·8 mm., while in a child aged 10 months it was only 1·5 mm. A comparison of these two cases showed that while the longitudinal layer was almost exactly equal in them, the circular was 1·05 mm. in the thicker pylorus, and only ·66 mm. in the other, so that almost the whole difference in the thickness was due to difference in the circular muscle.

Thirdly, there is very little variation in the thickness of the submucosa, but occasionally even this seems to be considerably thicker than the average.

A further point in the anatomy of the normal pylorus during infancy seems to want investigation before discussing the pathology of congenital hypertrophy of the pylorus. I mean the size of the normal lumen. My own observations on this point are not sufficiently numerous to be of much value, but so far as they go they show that a lumen of 3·5 to 4 mm. in diameter is not below the normal limit for the pylorus during the first year, *as seen post mortem*. This measurement is, of course, that obtained by measuring without any stretching of the pylorus, and was made in my own observations, by finding the largest probe or glass rod of known diameter which would pass through the pylorus quite easily, or with no more pressure than its own weight would afford.

Another less important detail in the anatomy of this part is perhaps worth mentioning, namely, the appearance of the pylorus as seen from the stomach, and as seen from the duodenum.

Digitized by Google

Particular mention has been made by several writers of the funnel-like shape of the pylorus on the stomach side, and of its likeness to the lower end of the cervix uteri on the duodenal side, in cases of congenital hypertrophy of the pylorus. It is to be remembered, however, that such an appearance is not peculiar to congenital hypertrophy of the pylorus; indeed, it is not pathological at all, for exactly similar appearances, though to a less degree, are noticeable in the normal stomach, and are particularly well seen in the cases where, as already mentioned, the pylorus happens to be thicker than usual.

The muscular layer is seen in the normal stomach to thicken gradually towards the pylorus, the thickening beginning 2 to 3 cm. on the stomach side of the pylorus; in the pylorus itself the thickening continues, but less rapidly, up to the duodenal opening, where there is a sudden increase of thickness due to the presence of additional bundles of circular fibres. Here the pyloric thickening ceases abruptly, and the thin duodenal wall begins; consequently, even in a normal stomach, the cervix-like appearance is produced.

In view of this gradual increase of thickness even in the pylorus itself, it is unfortunate that in several of the recorded cases of congenital hypertrophy of the pylorus no mention is made of the position at which the pylorus was measured. It will be seen from the normal measurements given below that there may be as much as 1·1 mm. difference between the thickness of the wall at the duodenal end of the pylorus and the thickness at a point about half a centimetre nearer the stomach—a difference which would be even greater in the fresh specimen. With these preliminary remarks I pass on to the consideration of congenital hypertrophy of the pylorus.

Four views have been held of the pathology of that condition:

(1) That the thickening of the pylorus occurs entirely in extra-uterine life, and is the result of spasm from some irritant in the stomach (Siemon-Dawosky).

(2) That the increase in thickness of the pylorus is the result of a developmental hyperplasia, "a vice of developmental growth" (Adams *re* Peden's case, 'Glasgow Med. Journ.,' 1889).

(3) That a primary narrowness of lumen, a congenital stenosis, is followed by compensatory hypertrophy of the stomach, especially the pylorus (Finkelstein, De Bruyn Kops, Meltzer, Landerer, Maier).

(4) That there is "a functional disorder of the nerves of the

Digitized by Google

stomach and pylorus leading to ill-co-ordinated, and therefore antagonistic action of their muscular arrangements;" and that this functional disorder begins *in utero* (J. Thomson).

The first theory has at any rate one point in its favour, that it is applicable to, and is, I believe, the accepted explanation of, the remarkably similar cases met with in adults. These cases of "idiopathic hypertrophic stenosis" in adults are due, it is thought, to spasm of the pylorus produced in some cases by superabundance of acid in the contents of the stomach, in others by the presence of an ulcer in the pyloric region, or some such irritant. No such cause of irritation has been demonstrated, however, in the infantile cases; and, moreover, it seems extremely unlikely that these cases have their origin during extra-uterine life.

The strongest objection to an extra-uterine origin is the improbability, perhaps impossibility, of so great a hypertrophy occurring within the short period of extra-uterine life in some of these cases. Thus in one case life only lasted twenty-one days, in two others twenty-eight days and thirty days respectively, and yet in each of these cases the hypertrophy was great. Moreover the degree of hypertrophy does not correspond to the duration of life or of symptoms.

A further point on which observations are much wanted is the date at which the pylorus first becomes palpable. There can, I think, be no doubt that with careful palpation the pylorus would be felt in a much larger proportion of cases than is recorded. The diagnosis has been so often made for the first time *post mortem*, that no special attention has been paid to this point during life, so that it is hardly fair to draw any conclusions from such records. I have myself seen four cases in which the pylorus was felt during life, and Dr. Barlow tells me of another that was under his care. If, however, from subsequent observations it can be shown that the pylorus is palpable at birth, then assuming, as I think we may, that a pylorus which can be felt is an enlarged pylorus, we should have positive proof that the condition was intra-uterine in its origin. The recorded facts at present are not conclusive; the earliest date recorded in five cases in which it has been felt was the twenty-seventh day;[1] the others were much later, none being earlier than the fourth month. So far as the facts go, they seem to show that the pylorus does not reach such a thickness as to be palpable

[1] J. Thomson, 'Scottish Med. and Surg. Journ.,' June, 1897 (Bibliography).

Digitized by Google

clinically until several weeks or months after birth; it would seem, therefore, that the hypertrophy is, at any rate in part, an extra-uterine development.

The fact that vomiting begins often within the first few days of life has been adduced as evidence of a congenital affection, and perhaps, considered in connection with the other points in favour of this view, it may be of some value; but in itself it is of little importance, for there is nothing to show that this early vomiting is necessarily the result of hypertrophy of the pylorus, or to distinguish it from vomiting due to any other cause; indeed, it might just as reasonably be adduced as evidence of extra-uterine gastric irritation producing subsequent hypertrophy.

The second view, which assumes a primary congenital stenosis as the cause of the hypertrophy, hardly needs consideration. The observations on the size of the lumen of the pylorus mentioned above, show that the measurements given in several recorded cases of hypertrophy are well within the normal limits, perhaps even above the average. The stenosis is the result of muscular contraction during life; in other words, it is the result, not the cause of the hypertrophy.

It may well be, however, that there is another quite separate group of cases, such as those described by Maier[1] and Landerer,[2] and perhaps the second case described by Dr. Ashby ('Archives of Pædiatrics,' 1897, p. 498), in which a congenital narrowness of lumen of the pylorus, especially at its duodenal end, acting as a stricture, produces some general hypertrophy of the stomach including the pylorus; but it would seem that in such cases the hypertrophy of the pylorus is a much less striking feature than in those under consideration.

Developmental hyperplasia, the third theory, is not altogether without support. The observations which I have recorded above show that there is considerable variation in the thickness of the normal pylorus, and the maximum limit of the normal comes very close to the minimum limit of the hypertrophied pylorus.

Further, the differences in the normal thickness, as I have shown, are mainly in the circular muscle, and this is notably true of the hypertrophic cases also. It might well be suggested, therefore, that the so-called hypertrophic pylorus might be merely one end

[1] 'Virchow's Archiv,' Bd. cii, Hft. 3, p. 413.

[2] 'Ueber angeb. Stenose des Pylorus,' Dissert., Tübingen, 1878.

Digitized by Google

of the scale of developmental variation, and that as a result of this unusual muscular development the wall of the pylorus is unusually rigid, and so unable to dilate fully, and hence hypertrophy and dilatation of the stomach, and all the usual train of symptoms. Such a theory, however, is completely negatived if it can be shown, as seems probable, that the pylorus becomes palpable only some weeks or months after birth.

Moreover there is some evidence that the condition is a recoverable one. Finkelstein[1] and Senator[2] have recorded such cases, and Dr. Barlow tells me of one where recovery seemed to have occurred. If this be confirmed by further observation, it would go a long way towards disproving any theory which assumed the presence of a malformation in these cases. A further objection is, I think, the fact that such a theory necessitates an entirely different pathology for the hypertrophic pylorus of adult life.

The last theory which needs to be considered is that put forward by Dr. John Thomson, of a functional disturbance of the nervous mechanism of the stomach, occurring *in utero* ('Edinb. Hosp. Rep.,' vol. iv, p. 116 and *loc. cit.*). As already pointed out, the balance of evidence is strongly in favour of this condition being intra-uterine in its origin; and this being so, the choice seems to rest between an unexplained vice of developmental growth and hypertrophy from increased work. The objections to the developmental view have already been stated. The suggestion that a defect of nervous co-ordination leads to antagonistic action, and so to hypertrophy of the muscles of the stomach, is at any rate in accordance with the common experience that elsewhere hypertrophy of muscle results from increase of work. To this extent also the explanation would agree with that accepted for the adult cases of hypertrophic pylorus, in which hypertrophy is thought to be due to spasmodic action of the pylorus, the result of some irritation. In the infantile cases, however, there is no evidence of any irritant, and for this reason Dr. Thomson has suggested that the spasmodic action may be due to a functional disturbance.

The question therefore arises, whether there is any evidence to show that functional spasm may occur here, and whether it may occur during intra-uterine life.

Apart from the inherent probability of such an occurrence there

[1] 'Jahrb. für Kinderheilk.,' Bd. xliii, p. 105.

[2] 'Berlin. klin. Wochenschr.,' January, 1897.

Digitized by Google

are cases which seem to point in this direction. Cases have been recorded in which the œsophagus has been found hypertrophied, the thickening ceasing abruptly at the cardiac orifice where there was no evidence whatever of stenosis. Dr. Rolleston has recorded such a case in the 'Transactions' of this Society (vol. xlvii), and has suggested that the cause was spasm of the cardiac orifice. If such be, as seems possible, the correct explanation of these cases, we have in them a close analogy for functional spasm of the pylorus.

It is very difficult, however, to prove that such a spasm may occur *in utero*. Dr. Thomson records the case of a male infant aged seventeen days, who had enormous dilatation of both ureters, very great hypertrophy with dilatation of the bladder, and no discoverable obstruction in the course of the urethra, and suggests that in such cases the whole condition may be the result of disordered co-ordination.

It has been suggested also that some irregularity of nervous mechanism producing irregular contraction of the intestine, or even spasmodic contraction of the sphincter ani, may possibly underlie some of the cases of congenital dilatation of the colon.

It will be seen, therefore, that although no actual proof can be produced, there are cases which suggest that a functional disturbance may occur in such a part, and moreover may occur *in utero*. Such an explanation seems on the whole to be the most rational that has yet been offered to explain these cases of congenital hypertrophy of the pylorus; but there is one point in the theory put forward by Dr. Thomson which seems to require some emphasis in the light of further observations. He considers it most likely that a derangement *probably from faulty development* of the nervous mechanism may be the cause of the over-action of the pylorus.

This faulty development, which he elsewhere speaks of as "delayed or imperfect development," must be regarded as a potentially transient condition, not a permanent developmental fault even of function; for there is, as I have already mentioned, increasing evidence that infants with this condition do occasionally recover. And there is, I think, no difficulty in such a supposition; co-ordination of the voluntary muscular actions is only gradually acquired, and even the not altogether voluntary action of the respiratory muscles is but imperfectly co-ordinated in infancy; moreover the time at which perfect co-ordination is acquired varies

Digitized by Google

*Measurements of the normal pylorus in infants.**

Age.	Thickness of whole wall.	Whole muscular layer.	Circular layer.	Longitudinal layer.	Submucosa.	Mucosa.
4 weeks (*a*)	About 1·8 mm.	1·18 mm.	1·05 mm.	·13 mm.	·2 mm.	—
4 weeks (*b*)	„ 2·2 „	1·55 „	1·3 „	·25 „	—	—
4 months (*a*)	1·5 mm.	1·05 „	·75 „	·3 „	·2 mm.	·25 mm.
4 months (*b*)	2 „	1·36 „	1·06 „	·3 „	—	—
5 months (*a*)	2·6 „	1·6 „	1·1 „	·5 „	·5 mm.	·5 mm.
5 months (*b*)	3·3 „	2·5 „	2·1 „	·4 „	—	—
5 months (*a*)	1·7 „	1·15 „	·9 „	·25 „	·25 mm.	·33 mm.
5 months (*b*)	2·3 „	1·5 „	1·2 „	·3 „	—	—
6 months (*a*)	1·6 „	·9 „	·7 „	·2 „	·2 mm.	·5 mm.
6 months (*b*)	2·4 „	1·73 „	1·4 „	·33 „	—	—
10 months (*a*)	1·5 „	·82 „	·66 „	·16 „	About ·23 mm.	·4 mm.
10 months (*b*)	2·1 „	1·61 „	1·25 „	·36 „	—	—
10 months (*a*)	2·4 „	1·51 „	1·1 „	·41 „	·3 mm.	·6 mm.
10 months (*b*)	2·9 „	2 „	1·5 „	·5 „	—	—
12 months (*a*)	2·31 „	1·55 „	1·1 „	·45 „	·26 mm.	·5 mm.
12 months (*b*)	2·41 „	2·65 „	2·2 „	·45 „	—	—

Measurements of hypertrophied pylorus.†

Case 1. 12½ weeks	3·5 mm.	2·4 mm.	2·1 mm.	·3 mm.	·3 mm.	·8 mm.
„ 2. 14 weeks	3·7 „	2·7 „	2·4 „	·3 „	·4 „	·6 „
„ 3. 14 weeks	4·7 „	3·4 „	2·6 „	·8 „	·9 „	·4 „

* (*a*) Taken at a point about 2 mm. on the cardiac side of the duodenal opening; (*b*) at thickest part, *i.e.* just at valve.

† Taken at a point about 2 mm. on the cardiac side of the duodenal opening, and therefore to be compared with (*a*) in the previous table, not with (*b*). The measurements in this table are taken after hardening in Müller's fluid, and are consequently different from the measurements of the fresh specimens mentioned in the paper.

Digitized by Google

within certain limits; it may well be that in some cases, at any rate, the establishment of perfect co-ordination in the involuntary muscular action is also delayed, and so antagonistic action occurs leading to hypertrophy.

Other references are—*Siemon-Dawosky*, 'Caspar's Wochenschrift,' 1842, No. 7, p. 105; *De Bruyn Kops*, 'Nederlandsch Tijdschrift voor Geneeskunde,' 1896, No. 25, and 'Brit. Med. Journ.,' 1897, i, Epitome 103; *Meltzer*, 'Medical Record,' August, 1898 (bibliography); *Rolleston and Hayne*, 'Brit. Med. Journ.,' 1898, i, 1070; *Cautley*, 'Med.-Chir. Trans.,' 1898, p. 41 (full bibliography).

February 7th, 1899.

---

15. *Congenital hypertrophy of the pylorus.* (*Card specimen.*)

By H. Morley Fletcher, M.D.

The pylorus, stomach, and part of the œsophagus of an infant, presented to the museum of St. Bartholomew's Hospital by Dr. J. Raglan Thomas, of Exeter.

There is great hypertrophy of the muscular coat of the pylorus. The stomach is also thickened, and the œsophagus is dilated. The mucous membrane of the pylorus is congested and swollen. Microscopical examination showed nothing of the nature of any tumour, the thickening being simply an overgrowth of the unstriped muscular tissue. This ceases quite suddenly on the distal side of the pylorus, but gradually tapers off towards the cardiac end of the stomach.

From an infant aged seven weeks, quite healthy at birth. When three weeks old vomiting began, which continued in spite of all treatment until the child died of inanition. At the autopsy no cause for death could be discovered beyond the hypertrophied pylorus. This measured 2 inches in diameter, and felt very hard.

February 7th, 1899.

Digitized by Google

16. *Carcinoma of the cardiac orifice of the stomach.* (*Card specimen.*)

By H. D. Rolleston, M.D.

There was a firm, raised growth surrounding the cardiac orifice and almost entirely limited to the stomach. There was no reason to think that it had begun in the lower end of the œsophagus and subsequently spread to the cardiac orifice. Microscopically it was a spheroidal-celled carcinoma, thus agreeing with the histological nature of carcinoma of the cardiac end of the stomach; it did not show any sign of a transition from squamous-celled carcinoma, the characteristic growth of the œsophagus. There was some dilatation of the œsophagus in its lower half. The specimen is brought forward to show that though Fagge's *dictum* that almost all the cases that have been set down as examples of carcinoma affecting the cardia have really been cases of carcinoma of the œsophagus spreading to the stomach is very often justified, it is not invariably supported even by the cases which *a priori* should be most likely to do so. These cases are those of carcinoma surrounding the cardiac orifice, which are, one would think, much more likely to have spread from the œsophagus than those cases of carcinoma abutting on the cardiac orifice, but not passing completely round its circumference as in the present instance. It is noteworthy that Hale White, in his article on tumours of the stomach in Allbutt's 'System of Medicine,' vol. iii, p. 564, comes to the conclusion, on the basis of Shaw and Perry's valuable statistics, that carcinoma limited to the cardiac end of the stomach arises there and may spread up to the œsophagus, and not *vice versâ* as Fagge[1] supposed. I have seen cases of extensive carcinoma at the cardiac end of the stomach send out feelers of growth under the mucous membrane of the œsophagus on its last inch or two, but I believed until I came across this specimen that carcinoma of the margin of the cardiac orifice was of œsophageal rather than of gastric origin. The morbid anatomy and histological appearances of this specimen are strong evidence,

[1] H. Fagge, 'Principles and Practice of Medicine,' vol. ii, p. 146, 1st edit., 1886.

Digitized by Google

however, that carcinoma may attack the gastric surface of the cardiac orifice.

The patient was under my care in St. George's Hospital, and died with rapidly increasing weakness seven days after admission.

For three months previously he had complained of debility, flatulence, and vomiting shortly after food. He was cachectic, and his skin was very inelastic and dry. He was fed *per rectum* to combat the vomiting, but his strength failed so rapidly that milky food was again tried by the mouth and vomiting returned. It was not thought that he had any œsophageal obstruction, but the autopsy showed that there must have been. During life no tumour could be felt and no dilatation of the stomach made out, but he was thought to have malignant disease, possibly of the body of the stomach.

February 7th, 1899.

---

17. *Carcinoma of the cardiac end of the stomach.* (*Card specimen.*)

By Arthur Voelcker, M.D.

Case 1.—The stomach is not dilated. At the cardiac end is a mass of new growth 3 inches in diameter, which does not involve the œsophagus. The growth is a malignant adenoma. The left lobe of the liver is adherent to the growth.

Metastatic deposits were present in the liver, lungs, cœliac, mesenteric, and lumbar glands. Thrombosis of inferior vena cava.

From a woman aged 42, who died in the Middlesex Hospital.

Case 2.—The cardiac end of the stomach on both its anterior and posterior walls is the seat of a new growth which has destroyed the stomach wall and invaded the liver and pancreas. The lower end of the œsophagus is free from growth, except that some strands of new growth can be seen running upwards in its long axis.

Duration of symptoms (pain and vomiting) eighteen weeks.

From a man aged 61, who was admitted under the care of Dr. Coupland to the Middlesex Hospital.

February 7th, 1899.

Digitized by Google

18. *Spheroidal-cell carcinoma of stomach involving the œsophagus.* (*Card specimen.*)

By W. S. Lazarus-Barlow, M.D.

The specimen was taken from the body of a man, aged 56 years. who suffered from chronic renal fibrosis and its cardiac sequels, as well as from malignant disease. During his stay in hospital the renal symptoms were more pronounced than those due to the stomach. The only symptoms certainly referrible to the latter were emaciation and dyspepsia, with vomiting and hæmatemesis.

At the autopsy it was found that the stomach, so far as concerns the lesser curvature and the greater portion of the anterior and posterior walls, was the seat of a mass of new growth, which has obviously commenced at the cardiac end of the stomach, where the growth had degenerated and formed a foul ulcer about the size of a five-shilling piece. The greater curvature was free from growth. The œsophagus also shared in the growth; at the gastric end is was thickened, and composed of a material which grated on section with the knife. Above, it was the seat of innumerable nodules extending right up to the pharynx. Most of the nodules were collected into three lines running in the long axis of the tube on its anterior surface, and corresponding to the course of lymphatic vessels. In two or three places the masses had broken down and formed ulcers about the size of a threepenny piece. The mass described must be regarded as single, for there was no line of demarcation between the gastric and the œsophageal portions of the growth. Secondary nodules, strictly so called, were chiefly found in the lumbar glands, which were greatly enlarged. In the liver only one small nodule the size of a pea was found. The vessels at the hilum were contained in a hard but not extensive case of new growth that extended upwards from the main growth in the stomach. An extension from the main growth involved the left adrenal. A secondary nodule of growth was present in the right adrenal. Nodules were also found in the left kidney and on the serous surface of the intestines close to the mesentery, but none

Digitized by Google

elsewhere in the body than in the sites mentioned. The primary growth in the stomach and œsophagus, as well as all the secondary growths, were definitely examples of spheroidal-cell carcinoma, differing from one another only in minor details dependent upon situation, rapidity of growth, &c. In the œsophagus the growth had greatly encroached upon the muscular bundles, and showed a general tendency for the cancerous cells to be arranged in long files.

The interest of the case lies, firstly, in the fact that the gastric growth extends upwards into the œsophagus rather than downwards into the stomach; secondly, that the growth obviously extends by way of the lymphatics; and thirdly, in the extensive degree to which the œsophagus is affected.

February 7th, 1899.

19. *Case of colloid carcinoma of the stomach.*

By R. G. Hebb, M.D.

The following case, though chiefly interesting from its clinical aspect, only an outline of which is subjoined, presents some pathological features worthy of record.

A. G—, aged 30, office cleaner, was admitted to Westminster Hospital on August 4th, 1898, for vomiting, pain in upper part of abdomen, and emaciation. Family history unimportant. Lived in the country until twelve years old, when she came to London. Was married in 1893; had a miscarriage at three months. Was in St. George's Infirmary, February, 1898, for rheumatism, since which has been troubled with pains and stiffness of the limbs. Has suffered from pains in the chest on and off for years. In April, 1898, she began to vomit after meals. The vomiting occurred ten minutes to thirty minutes after food, and has increased in severity. During the same period has also suffered from pain at the epigastrium and back before and after food, and lasting sometimes for hours. The pain was relieved by vomiting. There has been no hæmatemesis. Is a sallow, thin little woman; weight 5 st. 4 lbs. 8 oz. Besides the pain at epigastrium, &c.

Digitized by Google

she complains of an uncomfortable feeling in the throat on swallowing. There is some tenderness on palpation at the epigastric region. The abdomen is markedly retracted, and there is nothing abnormal to be felt or heard therein. There is no evidence of dilatation of the stomach or of any tumour in the abdomen. Urine *nil*. Temperature normal throughout. Thorax *nil*. Tongue slightly furred. Bowels constipated. The cervical lymphatic glands, especially on the right side, are easily felt. There is lateral nystagmus. Examination of the œsophagus and stomach showed that there was no impediment to the passage of a large bougie in the former, and that the latter was small and tender. The amount was variable, but often Oj—Oiss. The vomit was a frothy, watery fluid, usually containing reddish-brown floccules, which much resembled semi-digested beef-tea. The reaction of the vomit was always markedly amphoteric, and on the occasions it was tested the absence of free HCl was noted.

On October 11th the abdomen began to swell in the lower half, and by the 18th was generally distended with fluid.

On the 28th she was transferred to the surgical wards, laparotomy was performed, and much clear ascitic fluid evacuated from the peritoneal sac. The patient died next day.

The *post-mortem* examination was made fifty-one hours after death. Body much emaciated, flaccid; eyes sunken in orbits. *Post-mortem* decomposition commencing. Surgical wound four inches long in the middle line between pubes and umbilicus; edges united by sutures and early adhesions.

On opening the abdominal cavity the peritoneal sac is found to contain some pints of clear, thin, sanious fluid. There is no indication of recent peritonitis. The intestines are drawn upwards, none lying in the pelvis. The peritoneum of mesentery, of pelvis, and of abdominal wall is somewhat thickened, white and opaque. The omentum is quite shrivelled. There is no subperitoneal thickening. The stomach measures 6 inches transversely. Its wall in the pyloric portion is hypertrophied, especially close to the ring, which is 1·5 inches in circumference. A great deal of the mucosa of the pyloric portion is absent (roughly estimated at about 2 square inches). The anterior surface is chiefly affected. At the margin of the ulcerated portion the mucosa is much swollen, soft, and red.

The lower half of the œsophagus is dilated, its wall thickened,

Digitized by Google

and the surface covered with white patches of thickened mucosa. Some few prevertebral lymphatic glands immediately above and below the diaphragm are enlarged, indurated, and buff-coloured on section.

There are no peritoneal bands or adhesions. The intestines are normal. Liver 24 oz., *nil*; spleen 1¾ oz., *nil*; pancreas 2¾ oz., *nil*; kidneys 5½ oz., *nil*; adrenals *nil*; uterus *nil*; ovaries indurated, puckered, about size of large almonds; lungs *nil*; heart 4¾ oz., *nil*; brain *nil*.

Microscopical examination of the stomach shows the characteristic appearances of colloid degeneration of the mucosa with thickening of the submucous connective tissue. In the muscular coat are numerous collections of spheroidal cells, which in some parts have undergone the colloid change. In most places the cells have no definite disposition, and they form merely irregular collections between the muscle bundles. Yet there are a few areæ where there is evidence of arrangement in tubules, and these tubules are closely adjacent to the peritoneum.

In the lymphatic glands the cells are larger and of a more polyhedral type. The nucleus is large; in many places it is represented by a collection of granules—fragmented, in fact. There are also not a few large multinucleated cells with six or more nuclei. In the ovary, which presents the ordinary features of shrinking ovarian tissue, there are scattered throughout the stroma not a few cells which, though not absolutely identical in appearance with those in the stomach and lymphatic glands, present a striking resemblance to them. These are arranged in short tubules and cylinders. There is no evidence of colloid change either in lymphatic gland or in ovary, but there is some hyaline fibrosis in both. In the lymphatic glands there are areæ where the cells are in the granular condition of necrosis common in malignant growths. I was unable to detect the presence of a blastomycete.

There are several points in the microscopical appearances to which allusion may be made, and which might serve as texts for discussing some interesting and unsolved pathological problems. Such are the why and wherefore of the fragmentation of the nucleus, the origin of the multinucleated cell as distinguished from the giant-cell, the reasons for the occurrence of the granular condition of necrosis, the causation of the colloid degeneration, and its relation to other viscous states. It might afford a basis for attacking

Digitized by Google

the histological definitions of carcinoma and sarcoma, and of attacking them with success. But perhaps the chief point of interest lies in the relationship between the neoplastic cells in the ovary, in the lymphatic glands, and in the stomach. The cells are few in number, and are arranged in tubules and cylinders in the ovary. Are they to be regarded as secondary derivatives, or is the ovary the original focus?—the stomach, although showing by far the greatest amount of damage, being secondarily affected; or is there such a thing as cancerous diathesis due, say, to a contagium fluidum, and not to a corpuscular or morphotic virus?

February 7th, 1899.

---

20. *A case of gastrectomy for carcinoma of the stomach.*

By THOMAS F. CHAVASSE.

THE patient, a man aged 64, was admitted into a medical ward of the General Hospital, Birmingham, on October 8th, 1898, under the care of my colleague, Dr. Rickards. He complained of pain in the stomach, flatulence, and vomiting, and for a long time had suffered from dyspepsia, but there was no history of hæmatemesis; the bowels were generally constipated.

On examination there was marked retraction of the abdominal walls, and extremely flaccid muscles. A swelling was visible below the left costal margin, and on palpation a large sausage-shaped tumour was evident in the epigastric, umbilical, and left hypochondriac regions. The tumour was of firm consistence, and moved freely with each respiration. On percussion there was an area of absolute dulness. On examining the stomach contents no free hydrochloric acid was found; lactic acid was present at first, though absent at a later date. The patient had marked atheroma of the vessels, and also suffered from chronic bronchitis and emphysema. The urine contained no abnormal constituents.

On November 2nd, after a consultation, the patient was removed to a surgical ward.

Operation (November 3rd).—The abdomen was opened by a small incision to ascertain the extent of the growth and adhesions. The stomach being found much contracted and moveable, it was decided to make an attempt to remove it entire. The incision was

Digitized by Google

therefore enlarged and extended from the xiphoid cartilage to the umbilicus. Commencing at the left border of the greater omentum and working towards the pylorus, that membrane was divided successively between pressure forceps, and its vessels tied with silk ligatures. The same process was undertaken with the lesser omentum, from the pylorus to the lower end of the œsophagus. Two clamps were then applied beyond the pylorus, and the duodenum divided between them. The lower opening was closed with Lembert's sutures, and dropped into the peritoneal cavity.

The organ having been separated from its adhesions, it was found that the carcinoma had ulcerated through the stomach wall, and a round opening nearly the size of a sixpence was disclosed on the anterior surface near the cardiac end. The gastro-splenic omentum was next clamped and divided piecemeal. The œsophagus being pulled down as much as possible, a clamp was applied as high up as the diaphragm permitted, a second one being placed just above the cardiac end of the stomach, and, a division having been effected between them, the stomach was removed. By sponge packing the large cavity was kept quite dry, and some enlarged mesenteric glands were dissected out. An attempt was then made to fix a Murphy's button in the œsophagus so as to connect it with the jejunum, but partly owing to the retraction of the œsophagus and to the movements of the diaphragm, and partly to the extreme friability of the œsophageal walls, after several ineffectual attempts this proceeding had to be abandoned. No effort was made to unite the bowel and gullet by suture, as the anæsthetist gave warning that the operation should soon be concluded. Accordingly the lower end of the œsophagus was closed by silk sutures and left *in situ*. The divided end of the duodenum was stitched to the lower end of the abdominal wall, the remainder of the wound being closed in the usual manner with silkworm-gut sutures. The duration of the operation was one hour and fifty minutes.

After removal to bed there was a little restlessness, and three hours after the operation a quarter of a grain of morphia was given subcutaneously. The patient slept during the afternoon, and was fed with nutrient enemata given four-hourly.

At 6 p.m. the temperature was 97°, pulse 96; the patient complained of thirst, flatulence, and a desire to vomit. During the night he slept for six hours.

November 4th.—At 11.30 a.m. the duodenum was opened, a

Digitized by Google

catheter introduced, and the patient fed with peptonised milk, egg, and brandy. Duodenal feeding was carried on four-hourly. The temperature remained subnormal. The heart's action becoming weaker strychnia was administered subcutaneously.

The patient died of cardiac failure on the morning of the 5th, forty hours after the completion of the operation.

At the *post-mortem* examination made on November 6th the main points noted are—

Body much emaciated.

Heart.—Small and contracted. Marked atheroma of the walls of all the larger arteries examined.

Lungs.—Some old pleuritic adhesions. Hypostatic congestion at both bases.

Œsophagus.—Length 8¼ inches, lower ¾ inch, soft, friable, and infiltrated with new growth. Lower end completely occluded and watertight.

FIG. 15.

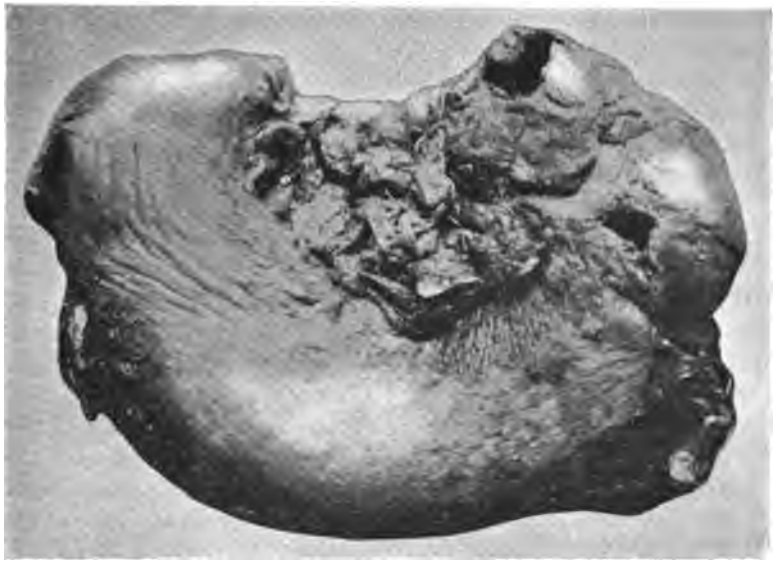

Carcinomatous stomach removed during life.

Abdomen.—There was no general peritonitis. The cavity where the stomach had rested was dry and entirely shut off by adhesions;

Digitized by Google

the duodenum was securely fixed to the lower end of the abdominal incision.

Stomach.—Small and very much contracted, bent on itself, and measuring 9¼ inches along its greater curvature and 3¼ inches along the lesser. The organ was almost entirely solid and its cavity nearly completely obliterated, its lumen averaging ½ to ¾ inch; its weight was 6 ounces. A perforation, the size of a sixpence, existed anteriorly near the cardiac end. Numerous glands showing secondary growths were found along the smaller curvature.

For the microscopical sections and the description of the same I am indebted to Dr. McDonald, pathologist to the General Hospital, who reports that there is hypertrophy of all the coats of the stomach wall, but especially of the submucosa. Although the new growth was apparently diffused throughout the organ, the sections near the pylorus show only fibrous thickening of the submucous coat, without any evident cancer cells. Examination of the enlarged glands along the lesser curvature showed typical spheroidal-celled secondary growths. Proceeding towards the cardiac end, there was increasing infiltration of the submucous coat with irregular spheroidal cancer cells, this being the prevailing type of new growth throughout. In places, however, the cells were arranged as in an ordinary scirrhous cancer, and at one point there was a nodule coming up to the surface of the mucous membrane, in which the cell clusters had a distinct peripheral layer of columnar cells. In the mucous membrane, and in some places in the other coats of the stomach, there is a wide-spread small-celled infiltration, with marked congestion and some small hæmorrhages; this is well seen near the special nodule previously referred to, and in the same neighbourhood there is a distinct fibrinous exudation on the surface of the mucous membrane showing leucocytes and degenerating desquamated cells. It would appear, therefore, that an acute inflammatory condition was superadded to the cancer, but there is no evidence that this was in any way connected with the perforation which existed, and which was apparently due to cancerous ulceration. No organisms were detected in any part of the stomach wall.

The chief points of interest are the mixed form of carcinoma present, the existence of ulceration and perforation together with the diffuse induration and extreme contraction of the organ, and the apparently superadded inflammatory process.

Digitized by Google

The method employed for removal of the stomach was, in the main, that successfully carried out by Dr. Carl Schlatter, of Zurich, the exception being the effort made to join the œsophagus and the jejunum by means of a Murphy's button instead of by sutures. The patient being very feeble, it was conjectured that a saving of time might be thus effected. The difficulties met with were the short portion of the œsophagus left, the depth of the wound, and the movements of the diaphragm hampering one's manipulations. The œsophageal wall, owing to its invasion by the neoplasm, proved very friable, and any tension upon the encircling ligature resulted in a tearing out. The button was three times placed in position, each time with more difficulty, before the attempt was abandoned.

The examination of the œsophagus after death showed that its walls were infiltrated to a point three quarters of an inch higher than the point of removal.

Unless the operation for removal of the entire stomach is employed instead of pylorectomy, the cases in which it can be employed with chance of a successful issue must be very limited. If the cardiac end of the organ be the site of the commencement of the new growth, then, as in this case, the walls of the œsophagus will probably be implicated to an unknown extent. Fixation to and implication of the neighbouring organs will also prove deterrents. In the present instance, excepting the lower end of the œsophagus, the whole of the diseased tissue proved to have been removed. *April 18th*, 1899.

---

21. *Carcinoma developing in the cicatrix of a gastric ulcer.* (*Card specimen.*)

By H. R. Belcher Hickman, M.B. (introduced by Dr. Lazarus-Barlow).

The specimen was taken from the body of a woman aged 29, who died in St. George's Hospital. The patient was a general servant; she had never been strong, but gave no history of any definite illness. She had suffered for three months preceding her death from epigastric pains, vomiting, and general dyspeptic sym-

Digitized by Google

ptoms. On admission she complained of pain and swelling of the abdomen. A hard swelling could be felt occupying an area about the lower edge of the liver. The patient gradually got worse, and died three weeks after admission.

At the autopsy the lungs were found to be œdematous, and there were numerous small nodules of new growth on the pleura and in the lung substance. There were also nodules infiltrating the mesentery. The liver contained several masses of growth. The pancreas was involved in a growth about the pylorus.

The specimen showed a dilated stomach, the mucous membrane of which appeared normal about the fundus, but towards the pyloric end of the lesser curvature there was a slight rough cicatrix of a former gastric ulcer, 1½ inches in diameter. Still nearer the pylorus was a slightly raised mass, which, with a cicatricial fibrosis, had caused a stenosis of the pylorus barely admitting the little finger. There was also great hypertrophy of the sphincter muscle.

Microscopically the primary growth was found to be a spheroidal-celled carcinoma composed of various-sized cells; the secondary deposits were made up mostly of rather large spheroidal cells.

Hemmeter and Ames ('Medical Record,' September 11th, 1897) describe a similar case (but in this there was also phlegmonous gastritis), and give a full biography of cases published to that date. Hayem met with a case in which the ulcer was entirely latent during life ('La Presse médicale,' August 4th, 1897). Dieulafoy describes a case in which the ulceration was very extensive, and the growth was composed of variously sized cells ('La Presse médicale,' November 10th, 1897). The subject is briefly mentioned by Debove and Rémond ('Traité des Maladies de l'Estomac'); they credit Dittrich ('Prager Vierteljahresschrift,' v, 1884, p. 1) with being the first to record a case of cancer as a complication of gastric ulcer, and they give also the following references:

Eisenlohr.—'Deutsche Wochenschrift,' 1243, 1890.
Biach.—'Wien. med. Presse,' No. 13, 1890.
Werner.—'Württ. med. Corresp.,' Nos. 22—24, 1869.
Lebert.—'Die Krankheiten des Magens,' Tübingen, 1875.
Flatour.—Inaug. Dissert., Munich, 1887.

Haeberlin says that in 3 per cent. of cases of cancer of the stomach the previous existence of ulcer is certain; whilst he is of opinion that in 4·2 per cent. it is nearly certain, and in 3 per

Digitized by Google

cent. very probable. Hauser, in a memoir on the subject (Leipzig, 1883), asserts that 5 to 6 per cent. of pyloric cancer has started in chronic ulcer. Descriptions of similar cases are to be found in the 'Pathological Transactions,' vol. ix, p. 200; vol. xl, 1890; vol. xlvi, 1895. *February 7th*, 1899.

---

22. *A specimen of duodenal ulcer from a case of melæna neonatorum.* (*Card specimen.*)

By T. D. Lister, M.D.

A spirit preparation consisting of the stomach, liver, and the duodenum as far as just beyond the biliary papilla. The duodenum has been opened and laid out on the under surface of the liver. The stomach has been opened and closed again by sutures along its greater curvature, and is turned over so as to show the opening of the pylorus into the duodenum, and is therefore not closed right up to the valve. The head of the pancreas and the bile-ducts remain attached under the duodenum, and the gall-bladder is intact, containing very dark green bile.

A shallow ulcer is seen near the cut edge of the duodenum, a quarter of an inch from the pylorus. Its edge is slightly raised, and shelves gradually to the centre of the ulcer and into the surrounding bowel. At the centre the ulcer deepens suddenly into the submucous tissue, and its base is semi-transparent for an area of about 2 mm. by 1 mm.

In the recent condition the ulcer was plugged by a small clot which remained adherent for some time, but which was eventually loosened, and is shown in a small vial beside the specimen. This clot apparently extended into a rather large vessel in the base of the ulcer, which seemed to be derived from the gastro-duodenal artery. The pylorus was closed, and there was no blood in the stomach. The intestines were, however, full of blood, red and fluid in the small intestine, but darker and more or less coagulated in the colon and rectum. There was no other change in the whole of the intestinal canal, and the mucous membrane appeared quite normal on being washed.

Abstract of case.—Baby C—, aged 3 days, was admitted to the

Digitized by Google

East London Hospital for Children, under Dr. Donkin, on the 29th of November, 1897, having begun to pass blood in large quantities on the 28th *per rectum*. There was no hæmorrhage from any other mucous surface.

On admission the temperature was 97°, and the patient was continually passing blood *per rectum*. A saline enema was administered, and was followed by very abundant hæmorrhage, leaving the patient very anæmic and collapsed, and the patient died on the 30th, when four days old. The skin was thought to be icteric the day before death, and a few small petechial spots appeared on the right cheek and side of the neck on the same day.

At the autopsy the condition already described was found. The funis was still adherent, but dried brown and shrivelled. There was no œdema or congestion, either superficial or deep, in the tissues in the neighbourhood of the umbilicus. The mucous membranes were generally anæmic, as were also the solid viscera. There were no petechiæ on the serous membranes. In the lungs were a few scattered, small, superficial, pyramidal infarcts of a deep brilliant crimson colour. Their bases on the surface of the lung were usually of a square shape, and the largest was about a quarter of an inch square at its base, and extended about three eighths of an inch into the lung. These infarcts were not attended by pleurisy, nor were they appreciably raised above the surface. They were very sharply defined from the surrounding anæmic lung tissue. There were no infarcts in any other organs.

Comment.—In this case the probable cause of all the lesions would seem to be the separation of thrombi from the umbilical vein, which could be swept at once into both the general circulation and into the lungs—the view expressed by Landau in 1874.

REFERENCES.

Rilliet and Barthez.—'Traité des Malad. de l'Enfance,' 2nd edit. (20 cases), vol. xi, pp. 295—310.

Silbermann.—'Gerhardt's Handb.,' iv (37 cases), S. 415.

Landau.—"Ueber Melaena der Neugeborenen," 'Habilitationsschrift,' Breslau, 1874.

Orlowski.—'Méd. mod.,' August 25th, 1897.

Neumann.—"Melæna Neonatorum," 'Arch. f. Kinderh.,' xii, 1891.

Homén.—Art. in 'Cent. f. allg. Path.,' ii, 1892.

Kundrat and Winckel.—Quoted in 'Starr's Text-book,' i, p. 93.

May 16th, 1899.

Digitized by Google

23. *Healed perforation of duodenum after passage of gall-stones.* (*Card specimen.*)

By Cecil F. Beadles.

Duodenum with its surrounding attachments, the bowel being laid open along its upper surface.

There is a small cicatricial depression seen on the inner lining of the duodenum just short of an inch from the pylorus, which is quite distinct from the orifice of the biliary pancreatic duct, the latter being situated 3½ inches from the pyloric opening. This depression corresponds to the firm adhesion of the wall of the gall-bladder on the outside, where also folds of the omentum have become drawn in during the process of cicatricial contraction, and in this thickened tissue a small biliary calculus lies embedded.

The gall-bladder was shrunken and tightly contracted over a single faceted calculus, in size that of a marble, and weighing 20 grains. Its surfaces are somewhat worn, showing that although other calculi were at one time present, they had not recently left the viscus. No fluid existed, and no other stones were found.

The old adhesions above referred to, and a certain amount of matting of the intestines in the neighbourhood, clearly prove a localised peritonitis had been set up at the time stones had left the gall-bladder, these having possibly passed both into the bowel and into the peritoneal cavity.

The liver was small, and weighed but 29½ oz.; the larger bile-ducts were dilated.

From a woman aged 70, who died insane after a short residence in Colney Hatch Asylum. It appears that she had been paralysed for eleven years. She had lived in the West Indies for five years some forty years ago, and had ague while there. Had drunk heavily of late. Her father died insane. No history was obtained that pointed to gall-stone disease or peritonitis. She was admitted in a very feeble and paralysed state, and died demented within six months.

At the autopsy advanced cardiac and arterial disease was found,

Digitized by Google

and the brain presented appearances common to senile dementia, but no lesion was discovered to account for the old paralysis.

January 17th, 1899.

---

24. *Three cases of sprue.*

By J. H. Drysdale, M.D.

Case 1.—Man aged 49 years, admitted to St. Bartholomew's Hospital under the care of Dr. Church on February 10th, 1898.

History.—In February, 1897, he went on the hospital ship to Benin; while there he suffered from fever and ague.

In March of the same year he returned to England, and then went to Crete. While there he had ague again, and began to suffer from diarrhœa. Five or six dirty white stools in the twenty-four hours passed without pain. His mouth began to be "sore," and he had "ulcers" on the tongue.

In May he went to China, and suffered all the voyage from diarrhœa and wasting. The diarrhœa has never ceased. No history of dysentery. Has lost over 7 stone in weight during his illness. While in the hospital the stools were always coloured. Temperature never raised. He died on April 6th, 1898.

Post-mortem examination.—Very emaciated. Tongue smooth, papillæ hardly visible. Œsophagus natural.

Stomach.—Small and tubular, resembling in shape the colon rather than a healthy stomach. Near the fundus and the pylorus the walls of the stomach were much thinned and quite smooth. The body was thickened, apparently from muscular hypertrophy and contraction, the mucous membrane being thrown into folds. In this region the circumference of the stomach when laid open only measured 3¼ inches.

Small intestine.—Jejunum natural. Ileum: hyperæmic zones alternated with zones where the valvulæ were absent. In the latter situations the gut was very thin, and print could easily be read through it. No obvious ulceration.

Large intestine.—A single follicular ulcer.

Digitized by Google

Liver (45 oz.).—The gall-bladder contained orange-coloured bile, and the bile-duct was patent.

Pancreas.—Rather small, but not harder than natural.

Lungs.—Miliary tubercle of both lungs and pleuræ.

A bacteriological examination of the stools only revealed the *B. coli communis*. Unaltered bile was found on examination in the stools.

A blood examination showed only anæmia of the usual secondary type.

Microscopical examination.—Tongue.—In the portion cut the epithelium was everywhere thinned, and in places altogether absent. The underlying tissue appeared healthy.

Stomach.—Portions of the thinned areas near the cardiac and pyloric orifices showed an atrophic condition of all the structures composing the wall. The superficial portion of the mucous membrane stained badly and appeared almost structureless. This was probably in part due to *post-mortem* digestive action. In the deeper portion there was some increase of connective tissue in between the gland tubules. The cells lining the tubules are deformed and small, and at the cardiac end it is impossible to distinguish between the central and parietal cells.

In the body of the organ corresponding to the "hypertrophied" portion the mucosa appeared less changed, the increase in thickness being due to a greatly thickened submucosa, a great increase of the fibrous tissue in that region having taken place.

Small intestine.—The wall was very thin, and all the structures composing it seemed to be atrophied. In places the villi have quite disappeared, and where they remain have lost their epithelium and are converted into shrunken tags infiltrated with small round cells. Many of the cells lining the crypts of Lieberkühn are deformed, and the lumina of the crypts themselves in places have become dilated. The fibrous tissue in the submucosa is relatively if not absolutely increased.

The pancreas shows no marked change, the connective tissue not being increased in amount.

Case 2.—A woman admitted to St. Bartholomew's Hospital under the charge of Dr. Church on May 16th, 1898.

History.—Eighteen months before admission, while in Bombay, the patient began to suffer from diarrhœa and sore tongue. The

Digitized by Google

stools were white and copious. Formerly weighed 15 stone; shortly before death reduced to 5¼ stone. No history of dysentery. After admission the diarrhœa continued until the patient died. The stools were usually faintly coloured, but were sometimes quite white or grey. The individual stools were not copious, but were often frothy and offensive.

Post-mortem examination.—Very emaciated.

Tongue quite smooth and shrivelled.

Œsophagus natural.

Stomach natural.

Small intestine.—Much thinned. No active ulceration. In the lower 4 feet of the ileum at intervals there are scars left by the healing of ulcers. They are pigmented and puckered, and are situated opposite the attachment of the mesentery.

Liver (28 ounces).—The gall-bladder contained bile; bile-duct patent. There was some bile in the duodenum.

Pancreas small and firm.

Spleen looks natural; weight 7 ounces.

A bacteriological examination of the stools gave a negative result.

A blood examination showed a well-marked anæmia of a secondary type.

Microscopical examination.—The tongue was not examined, having been preserved intact as a museum specimen. Œsophagus and stomach natural.

Small intestine.—The changes resemble those in the first case. The villi are much diminished in size, have lost their epithelium, the whole of the remaining structure being infiltrated, though not densely, with small round cells.

Pancreas.—Sections of the organ show a most extraordinary change. The connective tissue throughout is much increased in amount. Strands of fibrous tissue, visible in stained specimens to the naked eye, give the specimens at first sight almost the appearance of a coarse hepatic cirrhosis. All trace of alveolar structure is lost, the cells being tightly packed within the interlacing strands of new-formed fibrous tissue. The cells themselves are many of them degenerate and vacuolated, both the nuclei and cell protoplasm staining badly.

Case 3.—A man admitted to St. Bartholomew's Hospital under the care of Dr. Brunton on April 22nd, 1898. While in India in

Digitized by Google

November, 1896, began to suffer from diarrhœa. The stools were white and frothy, but contained no blood, and were passed without pain. In 1894 had an attack of dysentery.

After admission the patient passed stools greyish white in colour, frothy, copious, and foul-smelling. Sometimes the stools were yellowish, and occasionally on standing turned green from the presence of biliverdin.

A *blood examination* shortly after admission showed a secondary anæmia of a mild grade. Before death the anæmia became more pronounced, without altering its character.

A *bacteriological examination* of the stools gave negative results.

Post-mortem examination.—Much emaciated.

Tongue.—Papillæ over dorsum dwarfed. Surface quite smooth, no loss of substance.

Œsophagus natural.

Stomach smooth and thinned over the greater part.

Small intestine.—Thinner than normal, but not quite transparent.

Colon.—The ascending and transverse portions of the colon were somewhat contracted, and the walls apparently much thickened. The mucous surface is covered by what looks like a greyish-white granular exudation.

The descending colon contains several large ulcers, irregular in shape, with well-defined, rather sharply-cut edges.

Pancreas natural.

Gall-bladder contains orange-coloured bile.

Microscopical examination.—Tongue.—In parts, though quite smooth, the surface epithelium, so far from being thinned, is considerably increased in thickness, but as in the other case (1) the underlying structures seem unchanged.

The small intestine.—The changes were similar to those present in the other two cases, though the atrophy of the mucous membrane was more pronounced.

The ascending and transverse colon.—The thickening evident macroscopically proved to be due entirely to an enormous increase of the connective tissue in the submucosa, the mucosa and the muscular coats being thinner than natural. The surface of the mucous membrane in places was fused into a solid mass of inflammatory exudation, all the normal structure being lost. The exudation consisted of a structureless mass, containing in its substance

Digitized by Google

a few small round cells. The homogeneous substance did not give the staining reactions of fibrin. Towards the deeper portion remains of glandular structure could be seen. The cells were cubical and the lumina of the crypts dilated, giving them a cystic appearance.

Pancreas natural.

Remarks.—In none of the cases was the disease in an active state, so that one can hardly describe the changes as those of sprue. The changes are, however, those commonly found in patients who die from the effects of sprue, and include not only the alterations due to the local effects of the disease, but also changes in the portions of the bowel unaffected by the primary disease, due to what is practically a death from starvation.

The bacteriological examination showed in all cases an overwhelming predominance of the *B. coli communis*. The result is only what might be expected when the period in the disease at which the examination was undertaken is considered.

In all the cases the normal colouring pigment of fæces was present. In Case 1 the stools were always coloured, but in 2 and 3 the examination was made when the stools were greyish white in colour. At this time there was no difficulty in extracting, by means of acidified alcohol, a large quantity of deep brown pigment. Whether the colouring matter is present as a colourless chromogen, or whether the excess of fat which is present in these stools masks the colour which is present, I have not been able to decide.

April 18th, 1899.

---

25. *Fatal summer diarrhœa with acute enteritis.*

By F. W. Andrewes, M.D.

The specimens shown are from a case of fatal summer diarrhœa, which is of some interest not only because the intestinal lesion found *post mortem* was unusually intense, but because the bacteriological examination afforded a probable explanation of what was found.

The patient was an unmarried girl of 19, in previous good health. In August last she was attacked by diarrhœa and vomiting, slight

Digitized by Google

at first, but soon becoming more intense, till on the evening of the second day she was admitted to St. Bartholomew's Hospital in a state of profound collapse, from which she never rallied. Death occurred some fifty-six hours from the first onset. There is little to relate of the symptoms. The case was apparently an ordinary one of so-called "English cholera." While under observation the stools were frequently passed, colourless, and not unlike the rice-water evacuations of Asiatic cholera, from which, indeed, apart from bacteriological examination, the case could not be distinguished. At the *post-mortem*, held twenty-four hours after death, the sole lesion found was an enteritis of unusually intense character. The mucous membrane of the entire jejunum and ileum was of a vivid crimson colour and somewhat thickened. No ulceration was found, but the solitary follicles stood out very conspicuously, and were evidently swollen. Peyer's patches were not so much affected. The specimen shown has been prepared with formalin, and gives a good idea of the condition, though its colour has faded considerably.

It will be admitted that so intense an enteritis is rarely found in fatal acute diarrhœa. I have seen many *post-mortems* on similar cases, and I cannot remember to have seen anything approaching it. Commonly, in my experience, there is little or no evidence of enteritis after death, even in the most acute and rapidly fatal cases. At the most one sees a little injection of the intestinal mucous membrane, with or without slight swelling of the lymphatic structures. Even these may be absent. Within a few days of the occurrence of the present case we had at St. Bartholomew's another *post-mortem* on an adult man who died of acute diarrhœa, as sudden, as rapid in its course as the preceding, and not to be distinguished from it in clinical features. Yet the intestine showed no sign whatever of any inflammatory change; indeed, no sign of the cause of death was to be found *post mortem*.

There must clearly be reasons for such differences. The causation of summer diarrhœa is still an unsettled question, though it is generally conceded to be of microbic origin. Personally I accept the *Bacillus enteritidis sporogenes* (of Klein) as the probable cause of the disease. Not only is it constantly present in a virulent form in fatal summer diarrhœa, but what is known of its life history fits in very well with the hypothesis framed by Ballard in explanation of the epidemic incidence of the disease. It is, however, out-

Digitized by Google

side my aim to discuss the matter here, as the point I wish to suggest is that over and above the infection, whatever it be, which caused the primary diarrhœa in this case, there was also a definite streptococcus infection of the bowel, which seems to me possibly to account for the special character of the lesion.

Both a stool passed before death and a portion of the contents of the ileum taken at the autopsy were subjected to bacteriological examination. The spirillum of Asiatic cholera was searched for in the usual routine manner, and was not found. The *Bacillus enteritidis sporogenes* was found readily enough in both specimens. It was demonstrable microscopically by Gram's method of staining, though not in very large numbers, and it was obtained in pure culture in the ordinary way by inoculating milk tubes with the fæcal material, heating these to 80° C. for ten minutes, and then incubating anaërobically in Buchner tubes. Of the whey from one such tube, forty-eight hours old, one c.c. was injected subcutaneously into a guinea-pig and proved highly virulent, causing intense local œdema and gangrene, with death in about thirty-two hours. All this is what may be found in almost any case of acute summer diarrhœa. The special feature of this case lay in the very large number of streptococci present in the intestinal contents; they formed, indeed, the great bulk of the organisms present, which in my experience is unusual. (A stained specimen of the stool was shown.) Sections of the inflamed intestine stained by ordinary bacterial dyes showed enormous numbers of short bacilli (presumably *B. coli communis*, Proteus, &c.). Sections stained by Gram's method showed in the necrotic mucosa small numbers of streptococci and *B. enteritidis sporogenes*, not merely on the surface, but actually in the tissue. Ordinary agar-agar cultures made from the mucous membrane yielded a large crop of *B. coli communis* and other organisms, but amongst these were a number of streptococcus colonies, and the organism was obtained in pure culture. I am not prepared to state that it was identical with *Streptococcus pyogenes;* it made broth uniformly turbid, and formed comparatively short chains. I regret that I did not test its virulence.

These observations, imperfect as they are, seem to me to indicate that the special characters of the enteritis in the case described were due to streptococcus infection. I am, however, far from asserting that such infection was the primary cause of the disease, for I imagine that it is only infrequently to be found in fatal

Digitized by Google

summer diarrhœa. I conceive it to have been a secondary infection grafted upon an ordinary summer diarrhœa. The occurrence of streptococci in enteritis is well known; amongst others, Hirsch and Liebmann have described the condition ('Centralbl. f. Bakt. u. Parasitenkunde,' Bd. xxii, pp. 369 and 376), and more recently Escherich. *October 18th*, 1898.

---

26. *Two unusual cases of intussusception.*

By D'Arcy Power.

I bring forward this evening two specimens of intussuscepted bowel to show that death may result from the two opposite conditions of absolute irreducibility, and from an intussusception which is too easily reducible. Both cases were in the hospital at the same time, and it was my misfortune to operate upon them on successive evenings.

A. R—, a girl aged 5 months, was admitted to the Victoria Hospital for Children, 16th June, 1898. A cooling powder had been administered to her on the 13th inst., and had caused a single action of the bowels. The child was suddenly seized with a screaming fit on the evening of the 14th inst., and it was evident that she was in great pain. She began to vomit at once, and on the following day she passed blood and slime. The vomiting and discharge of blood-stained mucus continued until her admission on the 16th. The child had always been healthy before this attack, and had never suffered from diarrhœa.

There was no distension of the belly at the time of the patient's admission to the hospital, but there was some tenderness on palpation, especially upon the right side. No tumour could be felt through the abdominal walls, but by rectal examination it was easy to detect a swelling situated about 3 inches from the anus, and the finger was stained with blood when it was withdrawn.

The child was anæsthetised, and as soon as the abdominal walls were relaxed a distinct sausage-shaped tumour could be felt in the

Digitized by Google

left flank. An attempt was made to reduce the intussusception by irrigation with hot saline solution for five minutes, under a pressure of three feet. As no alteration took place in the size or position of the tumour the abdomen was opened immediately by a 3-inch incision. The intussusception was exposed and an endeavour was made to reduce it in the ordinary way. It proved to be quite irreducible, and I therefore stitched part of the small intestine to the abdominal wall, selecting a piece of the ileum as near as possible to the tumour. The patient was collapsed and feeble after the operation, but she survived until the next day.

A *post-mortem* examination showed a large ileo-cæcal intussusception. The intestines above the invagination were not greatly congested, and a piece of ileum about 2 inches from the beginning of the intussusception had been opened and attached to the abdominal wall. There was no trace of peritonitis.

The intussusception was cut out without previous reduction. It was hardened, and a longitudinal section was then made through it. Fig. 16 shows that it was of an extremely complex nature. The primary invagination was ileo-cæcal, of the ordinary descending type, the apex of the invagination consisting of the congested and thickened ileo-cæcal valve, with the openings of the ileum and vermiform appendix. The primary invagination was enveloped in a second intussusception passing in the reverse direction, that is to say, of the retrograde variety, and this retrograde intussusception was itself complicated by a third intussusception, also of the retrograde kind. The primary intussusception and the first retrograde invagination had occurred during life, for their apposed surfaces were glued together with inflammatory exudation. The third invagination, which was much smaller, was formed after death by a wrinkling of the bowel. The primary intussusception measured $3\frac{1}{2}$ inches in length, the retrograde invagination was $2\frac{1}{2}$ inches long. The section showed that two lymphatic glands were carried down in the first intussusception, and that both were inflamed. The ileum measured 11 mm. in transverse diameter, and the colon was 19 mm. across.

This specimen was extremely complicated, but it is an important one, for I believe it to be an example of a form of intussusception which is by no means uncommon. It is a particularly deadly variety,—first, because distension of the colon has no effect in relieving it; and secondly, because after a laparotomy any attempt

Digitized by Google

FIG. 16.

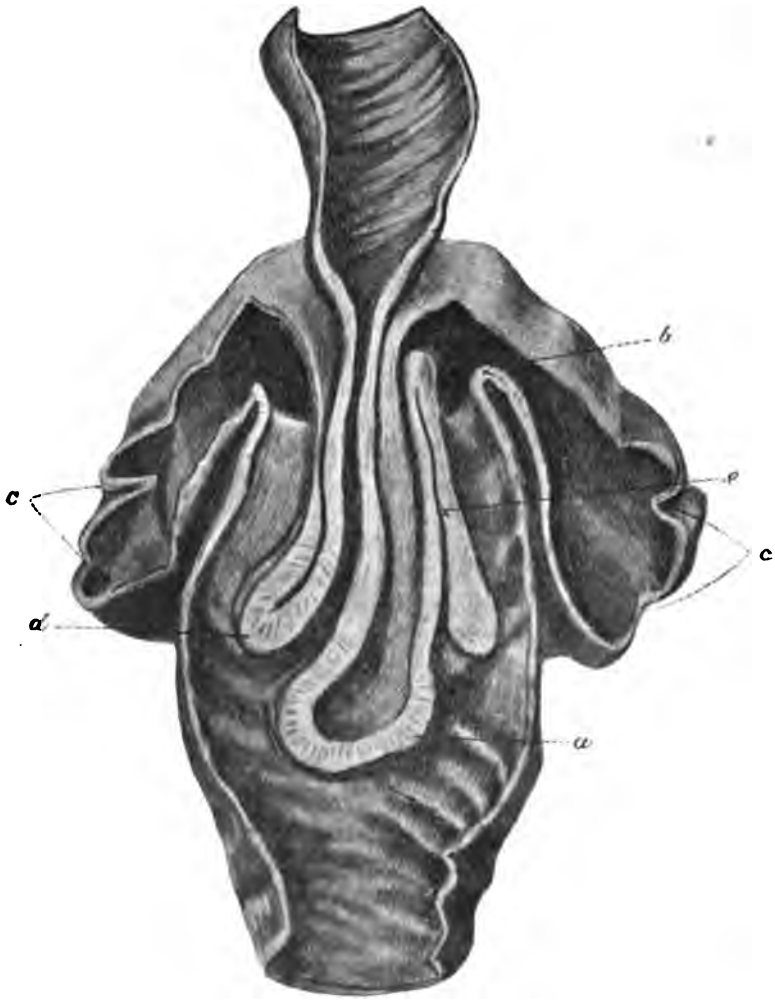

A semi-diagrammatic drawing of a longitudinal section through a descending ileo-cæcal intussusception (*a*), complicated by a retrograde or ascending invagination (*b*). The puckering at *c* and *c* was more marked when the specimen was fresh, and gave the appearance of an additional intussusception. *d* is the thickened ileo-cæcal valve. *e* is the vermiform appendix.

Digitized by Google

to reduce the intussusception tends to increase the retrograde invagination and so make matters worse. It was impossible to reduce the intussusception in this particular case, because the youth of the child and the amount of bowel involved prevented the tumour being brought to the surface, and it had to be manipulated, therefore, as it lay in the small abdominal cavity.

The original drawing of this specimen is in the museum of St. Bartholomew's Hospital, No. 457A.

The second specimen is as simple as the former was complex. The patient was a boy aged 6 months, who was admitted to the Victoria Hospital for Children on June 16th, 1898, under the care of my colleague, Dr. Walter Carr, with the history that he had fainted on the 14th inst. The attack of syncope was followed by vomiting, and on the following day he passed blood and slime but no fæcal matter. The blood-stained mucus was passed four times on the day before his admission to the hospital, and he suffered much pain. The vomiting continued at intervals from the first attack until the time he was seen.

The patient had been suckled for the first three months of his life, and after he had been weaned he was fed upon cow's milk and barley water. Two months before he had suffered from congestion of the lungs and inflammation of the bowels.

On admission to the hospital he appeared to be a healthy and well-nourished child, presenting no physical signs of disease. No abdominal swelling could be felt either on palpation or *per rectum*. He had one motion on the evening of his admission, passing a little blood with it, and he was sick after his food. It is reported on the following day, the 17th inst., that he had been sick through the night, and that his aspect was bad, but no swelling could be felt in his abdomen.

He got worse during the day, and at 8.30 p.m. I was called in to treat the case as one of intussusception. The patient was anæsthetised, and it was easy to feel a sausage-shaped tumour in the upper part of the abdomen. An unsuccessful attempt was made to reduce the intussusception by irrigation with hot salt solution under a pressure of three feet, and the abdomen was then opened immediately by an incision carried just to the right of the middle line. I introduced my fingers, and as soon as I had lightly grasped the bowel just below the tumour the intussusception reduced itself spontaneously. I satisfied myself that the ileo-colic angle was fully

Digitized by Google

unravelled and then closed the abdomen. The operation was not attended with any satisfactory result, for there was no action of the bowels; the temperature rose to 103°, and the child died twenty-four hours after the operation.

The *post-mortem* examination showed the presence of an ordinary ileo-cæcal invagination, which was quite easily reducible, for there were no adherent surfaces.

A month or two after the cases which I have just recorded came under my observation, Mr. Lucy, of Plymouth, sent me the accompanying specimen to show before this Society, saying, "This is the description of a case I saw in consultation eight days ago. A delicate girl, thirteen years of age, was seized with violent pains in the right iliac region four days before I saw her, and vomiting followed by almost complete obstruction of the bowels, but there was no passage of blood or mucus nor any tenesmus. When I saw her the abdomen was uniformly distended, especially tympanitic in the epigastrium, but dull in either flank, a sign which gave way to resonance on rolling her over. There was no visible peristalsis, the rectum was empty and ballooned, and the child indicated a spot to the left and just above the level of the umbilicus as being most tender.

"I thought there was a band or volvulus, and advised immediate operation. The abdomen was opened just below the umbilicus, and in the middle line. Clear fluid escaped, and a coil of distended small intestine was drawn down and secured by a few points of suture to the transversalis fascia and parietal peritoneum. The wound was then packed round with gauze, and the intestine was opened, allowing large quantities of green fluid and gas to escape, with evident relief to the heart and respiration. It proved, however, to be one of those "too late" cases we see so often, and she died poisoned in six hours.

"I obtained a *post-mortem* examination, and found that the enterostomy had been made three feet from the pylorus, and one foot on the proximal side of the obstruction. I removed the distended coil entire for further examination, noting that beyond it there were four feet of deeply congested ileum ending at the ileo-cæcal valve. A subsequent examination of the intestine showed that the gut narrowed suddenly a foot below the artificial anus and disappeared beneath a horseshoe-shaped coil of purple and distended intestine. This coil of intestine contained an intussusception, and on slitting open the intussusception I

Digitized by Google

found about three feet of collapsed and slaty-blue ileum, packed away and adherent between the entering and returning layers. This portion of the ileum ended in the intussusception proper."

It is clear, I think, from Mr. Lucy's description, that this is a very unusual form of enteric intussusception, similar in some respects to my first specimen. It is an intussusception enclosed in a sheath of bowel, but with the additional complication that a very considerable length of the small intestine has slipped in between the two layers of the intussusception itself. I have thought, therefore, that the case should be recorded in the Society's 'Transactions,' for I know of nothing like it.

January 3rd, 1899.

---

27. *Appendix vermiformis in which a pin was lodged.* (*Card specimen.*)

By H. A. Lediard, M.D.

The appendix was removed *post mortem* from the body of a man aged 23, who died of gangrene of the lung in the Cumberland Infirmary in February, 1899.

The *post-mortem* was made by Dr. Wade, Assistant House Surgeon, who was not led to examine the appendix region by any symptoms, for during life there were none. The discovery of the pin was purely accidental. For a distance of two and a quarter inches from the free extremity the appendix is thick and a little dilated, and at the junction of the healthy part of the appendix with the diseased portion there is an area of ulceration of the mucous membrane the size of a threepenny piece, due possibly to irritation from the sharp point of the pin. The pin lay with the head at the extreme tip of the appendix. The length of the pin is about one and a half inches.

May 16th, 1899.

Digitized by Google

28. *Peculiar condition of the colon in pernicious anæmia.*[1]

By H. Morley Fletcher, M.D.

These specimens from a case of pernicious anæmia are shown on account of the unusual lesions present in the intestines.

The case was a typical one of pernicious anæmia. The patient, a hair-cutter aged 34, was admitted three times to St. Bartholomew's Hospital under Dr. Hensley's care for this complaint. I am indebted to Dr. Hensley for his kind permission to refer to the clinical notes.

The first occasion on which the patient was admitted was in June, 1897, and he presented well-marked and typical signs of the disease. As so often occurs in these cases, great though temporary improvement took place.

In June, 1897, the condition of his blood was—hæmoglobin 17 per cent.; red corpuscles 920,000, white corpuscles 3000.

In October, 1897, the hæmoglobin had risen to 73 per cent.; red cells to 3,340,000, white 3000.

In March, 1898, he was again admitted. His hæmoglobin had fallen to 18 per cent.; red corpuscles were 1,200,000, and white corpuscles 3000. There was some epistaxis and moderate pyrexia, the temperature being generally 100° at night-time.

He was readmitted in September, 1898, with aggravated symptoms due apparently to an attack of pleurisy, with some congestion of the base of the right lung, and he died three days later. His temperature varied during these days from 103° to 106°.

Two days before his death his blood was examined. Hæmoglobin was 19 per cent.; red corpuscles 700,000, white 2000. The legs were œdematous.

The day before his death he had small frequent stools, four per diem, which are stated in the notes to have been "evidently the result of constipation;" at no time did he have diarrhœa.

The *post-mortem* examination was made by Dr. Garrod. The notes are as follows:

A spare man; well-marked rigor mortis; no hæmorrhages.

Brain weighed 48 oz., and was natural. The spinal cord was not examined.

[1] St. Bartholomew's Hospital Museum, No. 1995B.

Digitized by Google

Œdema of both *lungs* with slight pleurisy at the right base.

The *heart* weighed 16 oz. It was hypertrophied. The valves were natural. There was well-marked "tabby cat" striation of the muscular tissue, which gave no iron reaction.

The *stomach* was natural.

The *liver* weighed 87 oz., and exhibited a well-marked iron reaction.

The *gall-bladder* was full of dark brown bile.

The *spleen* was large, weighing 15 oz.; it gave *no* iron reaction.

The *kidneys* weighed 8 oz. each, and gave a well-marked iron reaction.

The *pancreas*, *abdominal lymphatics*, and *supra-renals* gave *no* iron reaction.

The *pectoral muscle* gave *no* iron reaction.

Bones.—The marrow of the clavicle was pale in colour and gave no iron reaction. That of the tibia was of a very deep red colour, and gave a vivid iron reaction. I am showing sections of the tibia both stained and unstained, though the unstained specimen has lost unfortunately some of the brightness of the red colour.

The intestines.—Peyer's patches were very long, some of them at least four inches. The mucous membrane showed remarkable roughening in the colon and lower part of the ileum. It appeared as if covered with a warty growth of yellowish-brown colour. In places this appearance was continuous, in other parts patchy with intervals of healthy mucous membrane. The affected intestines were peculiarly tough, thick, and leathery. Nothing abnormal was noticed in the intestinal vessels. I am showing a portion of the colon, and sections are placed under the microscope.

Further comment on the case or the *post-mortem* notes is unnecessary, except that it is interesting to note the fact that this case shows very well the way in which certain organs may exhibit the so-called iron reaction to a marked degree, while in others, notably the spleen, it is sometimes entirely absent.

The *microscopical* changes in the intestine are as follows:—There is necrosis, in parts complete, of the mucous membrane occurring in patches, associated with great hyperæmia. In places hæmorrhages have occurred. The glandular structure can be made out, though greatly altered and covered by masses of necrotic material. These are evidently recent changes. The increased thickness of the gut is largely due to the fibrotic condition of the submucosa,

Digitized by Google

which is also hæmorrhagic and œdematous. The fibrosis can only be regarded as due to some older inflammatory affection of the colon.

This condition of the intestines in connection with pernicious anæmia appears to be very unusual, and I have been unable to find records of any similar case. The question naturally arises, is this condition simply coincidental, or is it in any way associated with the primary blood disease, as other lesions of the alimentary tract, especially of the stomach, have been considered to be?

The duration of the illness—eighteen months—is opposed to the view that this condition of the intestines could have existed for any great length of time without giving rise to some symptoms, such as diarrhœa, when we consider that the entire colon was affected. In the clinical history of the case there were present none of the alimentary disturbances which have been described by Hunter[1] and others as occurring in pernicious anæmia. Vomiting and diarrhœa were conspicuously absent, while constipation was present.

There is no doubt that in many cases of pernicious anæmia, *gastritis* with marked changes in the mucous membrane of the stomach is a prominent symptom, and that atrophy of the gastric glands may possibly be a cause of the disease as suggested by Dr. Samuel Fenwick.[2] It is far more probable, as Hunter has argued, that these lesions are not the cause but are only associated with the primary disease.

The changes in the intestine which I am showing, appear to me to have been produced late in the course of the disease—perhaps quite near its termination. *How have they been brought about?* No cause of irritation of the mucous membrane can be found; arsenic was given over long periods, though never in larger doses than 5 minims of Fowler's solution. The normal appearance of the stomach and duodenum would exclude the possibility that this drug might have produced the lesion. Purgatives were occasionally given, but never calomel.

The microscopical appearance of the intestine almost suggests thrombosis of the mesenteric veins by the great congestion of the mucosa and œdema of the submucosa, but there was no evidence

[1] 'Lancet,' Sept. and Oct., 1888.

[2] Ibid., 1887, vol. ii, pp. 1, 39, 77.

Digitized by Google

of this at the *post-mortem*, and the intestine would have been dark red in colour rather than a pale yellow.

Repeated hæmorrhages into the submucosa might perhaps account for some of the changes, but the hæmorrhages which are apparent under the microscope are too minute and limited to have produced a result so extensive, and there is no evidence of pigmentation pointing to former hæmorrhage.

The only other hypothesis I can bring forward, but for which there is no evidence, is that the extensive changes in the intestines may have been caused by some neurotrophic lesion. Cases have been described by Banti, Eichhorst, and others in which definite lesions in the alimentary canal have occurred apparently as the result of changes in the sympathetic system whether of the ganglia or the plexuses of Auerbach and Meissner. In such cases the nerve changes are probably due to degeneration resulting from impaired nutrition. It is conceivable that something analogous may have occurred in this case, but there is no evidence for it.

As I have already pointed out, the intestinal lesions are of two kinds: the one, an old inflammatory change affecting the submucosa and resulting in fibrosis and thickening; the other, and more recent, a coagulation-necrosis of the mucosa. These changes may possibly be accidental, but it is far more probable that the older change in the submucosa is an intestinal lesion comparable to those described in other parts of the alimentary canal by Hunter and others, and which may be directly associated with the blood disease. The necrotic condition of the mucosa is probably accidental and connected with the acute termination of the disease. *December 20th*, 1898.

---

29. *A specimen of diffuse ulcerative colitis with secondary acute interstitial hepatitis.* (*Card specimen.*)

By T. D. Lister, M.D.

A formalin preparation, consisting of the last four inches of the ileum, the ileo-cæcal valve, the cæcum, and all the large intestine. The intestine is laid open, and the whole of the mucous

Digitized by Google

membrane of the vermiform appendix and of the colon is seen to be covered with minute ulcers. There is no ulceration in the four inches of ileum exhibited, though there is a moderate degree of hyperæmia. The ulcers of the colon are mostly hemispherical depressions of 1 to 2 mm. diameter, but in many places they have run together, forming small oval or even irregular ulcers with deeper and steeper edges than have the single ulcers. In a few instances, chiefly in the sacculi between the longitudinal bands, the ulcers have a fissured linear form, but there are none of any form greater than 5 mm. in length. Their distribution is quite irregular, and bears no particular relation to the follicles, many follicles being normal and many ulcerated, and many of the ulcers being placed between the follicles. The process is most marked in the ascending colon, the vermiform appendix, and in the sigmoid flexure. There is also a greater degree of congestion in these parts than elsewhere, though the whole is congested. In the rectum the process is almost entirely follicular. There is nowhere any "flaking" or membranous sloughing.

In the recent state the colon contained both fresh and altered blood and some mucus, and in the rectum there was some bile-stained feculent mucus, but no other liquid or solid fæces anywhere in the intestines.

Case.—The case was that of a boy aged 5, admitted under the care of Mr. H. B. Robinson at the East London Hospital for Children on April 11th this year, with somewhat anomalous symptoms of intussusception, for which abdominal exploration was performed. The clinical history of the case is dealt with elsewhere by Mr. H. B. Robinson, to whom I am indebted for permission to show the specimen. The symptoms were not relieved, and the boy died eight days after the operation with gradually increasing hæmorrhage from the bowel, and finally hæmatemesis, the wound having healed perfectly.

At the autopsy the large intestine was found in the condition described above. The abdominal wound was completely healed deeply and superficially. There was general diffuse bronchopneumonia. The internal organs were all strikingly anæmic, except the mucous membrane of the small and large intestines and that of the stomach. The mucous membrane of the stomach and small intestine was acutely and very generally congested, but nowhere presented any ulceration. There was altered blood in

Digitized by Google

the stomach, and fresh and altered blood all through the intestinal tract, which seemed to be derived from no definite focus or foci, but to arise from a more or less general oozing.

The microscopical preparations shown include sections of the colon and of the liver. The latter organ in the recent state was of a very pale colour and somewhat fatty. It was rather firm.

Sections of the colon show, firstly, an extensive destruction of the glandular epithelium, the columnar epithelium being entirely absent in many of the tubes, and in most of them being only represented by a few loose cells lying irregularly in the lumen, these cells having separated in masses of one to ten or twelve. Secondly, a small-celled infiltration of the basement membrane and connective tissue, especially close to or at the fundus of the tubes. Thirdly, an extension of this infiltration into the submucosa from some of the tubes, which is traceable in some instances as an infiltration beginning in the connective tissue between the glands, extending more deeply to the fundus, and then into the submucosa to expand into a considerable mass of round cells. Fourthly, by an extension of this process, the formation of ulcers in which the glandular tissue is entirely lost. Fifthly, the dilatation of the vessels of the mucosa and submucosa into quite considerable blood spaces. In many places the inflammatory change can be traced by the masses of round cells into the muscularis mucosæ.

Sections of the liver show, firstly, a severe diffuse cellular infiltration; where a lobule has been cut through centrally there is seen to be a zone of round cells completely surrounding it, and this process is general throughout the perilobular and interlobular tissue; there seem to be no foci; the cellular infiltration extends to a greater or less extent towards the centre of the lobule, but in no instance can there be found any aggregation of cells in or near the centre of a lobule; the average thickness of the inflammatory zone is about one quarter of the radius of the lobule. Secondly, a large proportion of the liver cells contain fat globules, especially those of the intermediate zone, the cells otherwise appearing normal. Thirdly, the bile-ducts are normal. Fourthly, the tissue is very anæmic. In sections of the liver stained for organisms, numerous rods can be seen, but their nature was not ascertained by cultures, and the autopsy was made more than twenty-four hours after death.

Digitized by Google

REFERENCES.

Somewhat similar cases of colitis leading to clinical difficulties are described.

(*a*) By *Dr. Samuel Adams*, in Starr's 'Text-book,' vol. i, 488.
(*b*) By *Rosenheim*, in Eulenberg's 'Encyklop. Jahrb.,' iv, 1894.
(*c*) By *Ashby and Wright*, 'Diseases of Children,' p. 87.

May 16*th*, 1899.

---

30. *Villous papilloma of rectum.* (*Card specimen.*)

By T. CARWARDINE, M.S.

THE specimen was a portion of a villous tumour discharged spontaneously *per anum*. It must have been at least the size of a closed fist, judging from the quantity of villous material which came away. The patient was a young woman about 25, who for the last four years had suffered agonies from piles and prolapsus ani, and latterly bits of jelly-like material had frequently come away, appearing like villous fronds on examination.

The piles were treated by operation, but for special reasons no further search *per rectum* was desirable at the time. A week after the operation the patient passed a very large quantity of what the nurse called "mucus," and for the twelve months subsequently the patient has been perfectly well, with no indications of papilloma remaining.

The villous fronds were in some cases three inches long, branched, and often with somewhat clubbed terminals. The substance was little firmer than that of a jelly-fish, rendering it quite impossible to suspend the fronds in a bottle owing to friability. There was no indication of a much thickened base, and no suggestion of malignancy. The spontaneous discharge of a villous papilloma is a rare but recognised event. *January* 17*th*, 1899.

Digitized by Google

31. *Enterolith from the rectum.* (*Card specimen.*)

By Samuel G. Shattock.

An irregularly oval concretion about 2 inches in chief diameter, which was removed (in 1857) from the rectum of a lady 69 years of age; its weight immediately after removal was 3 oz. (avoirdupois). A concretion had previously been removed by Dr. Oldham, of Guy's Hospital. The central cavity was filled with a crumbling material mixed with shining crystals, some of which remain projecting from its sides; the material was fusible, and may be assumed, therefore, to have consisted of phosphate of lime mixed with ammonio-magnesian phosphate. The peripheral part of the calculus, which has a coarse radial structure, is composed largely of organic matter with ammonio-magnesian phosphate and a small proportion of phosphate of lime. The specimen was presented to the museum of the Royal College of Surgeons last year by Mr. Norris F. Davey.

As I was anxious to ascertain whether the periphery contained any calcium oxalate, a portion was kindly examined by Mr. Gordon Salamon, but with a negative result. Intestinal calculi of this substance occur amongst herbivora, where they may attain considerable dimensions; and although none such have as yet been recorded in the human subject, it is not unlikely that the progress of vegetarianism may bring about their formation, seeing that the substance in question is derived solely from that ingested in vegetable food. *May 2nd*, 1899.

---

32. *Achroo-amyloid liver, spleen, and kidneys.*

By W. J. Hadley, M.D.

Clinical history.—A man aged 75, taken ill suddenly with violent pains in abdomen, followed by œdema of legs and then ascites, after thirty-five days getting gradually worse, was

Digitized by Google

admitted into hospital with enormous ascitic distension of abdomen, great œdema of flanks and legs, marked general wasting, and a dry, brown tongue. Jaundice supervened a few days after admission. Several hundred ounces of fluid were drawn from the abdomen. The liver was felt to be much enlarged. The urine was very scanty (only 10—19 oz. in twenty-four hours), contained bile and a considerable quantity of albumen (one tenth to two thirds).

There was never any rise of temperature; vomiting came on, and the man gradually sank twelve days after admission and forty-seven days after the onset of the disease.

Post-mortem appearances.—The lower limbs and scrotum were œdematous, and there was marked jaundice. There was a little bile-stained fluid in left pleural cavity, and the lungs were œdematous.

The *heart* was contracted, cavities practically empty. There was *acute endocarditis* (small granulations) of the *mitral* valve.

Abdomen.—Much excess of fluid, adhesion round liver and spleen.

Spleen (12½ oz.) very hard, no reaction to iodine (like "ague cake").

Kidneys (15 oz.) peel readily, surface smooth. Cortex slightly increased, a few cysts, no hæmorrhages. A few isolated points stain dark brown with iodine.

Liver much enlarged, hard; no reaction to iodine, though it presents typical bacony appearance of lardaceous disease, but feels harder. There was perihepatitis, and several coils of intestine were matted together and adherent to liver and spleen.

Microscopic appearances.—Liver.—With ordinary staining, an infiltration is seen between and in the cells, chiefly affecting the central zone of the lobule, but being for the most part widely spread throughout the organ. This material is structureless and homogeneous, seems to replace the whole liver cell, and, although having the general appearances and anatomical distribution of lardaceous degeneration, it does not give the characteristic staining reactions of that material on the one hand, nor, on the other, does it give those of hyaline degeneration. This material, therefore, which is somewhere in position between amyloid and hyaline (both derivatives of fibrin), has been styled achroo-amyloid, on account of its non-staining properties. Dr. Bullock, to whom I am greatly indebted for his aid in working out this case, has tried a whole pharmacopœia of reagents with hardly any success in staining it. These attempts have been made on fresh material and also on tissue

Digitized by Google

hardened in sublimate and alcohol. Briefly it does not give any of the staining reactions of amyloid, nor any of those of hyaline. Anatomically it is amyloid; chromatically it is neither amyloid nor hyaline. It stains faintly with orcin, eosin, logwood, and methyl blue.

Spleen.—Here too, as in the liver, there are the typical histological appearances of *diffuse* amyloid disease, but no characteristic staining.

Kidneys.—These are the only organs that show any characteristic amyloid staining; for in a few of the Malpighian tufts an imperfect or hybrid reaction to methyl and gentian violet is seen. Otherwise the kidneys show the appearances of chronic nephritis contracting, but still large.

Staining methods.

Spleen and liver.—1. *Against true amyloid.*—Iodine, iodine and H_2SO_4, thionin, iodine green, and polychrome methylene blue; no amyloid reaction. Methyl and gentian violet: evanescent, impossible to fix colour.

2. *Against true hyaline.*—Van Gieson's stain (picric acid and Säurefuchsin): indefinite colour, yellowish brown.

3. *Weigert's fibrin method.*—No reaction.

Kidneys.—Some Malpighian tufts give hybrid reaction to methyl and gentian violet.

April 18th, 1899.

---

33. *Acute degeneration of liver cells supervening in the course of chronic cirrhosis.* (*Card specimen.*)

By F. Parkes Weber, M.D.

The liver of a man aged 20, working as a tailor in London, who died with cerebral symptoms and jaundice, following an attack of vomiting and diarrhœa. When I saw him the day before his death he was unconscious, but sometimes moved restlessly or cried out when disturbed. He had previously been wandering in his mind and noisy. The pupils were equal, of medium size, and did not react to light. The corneal reflex was present. The tongue

Digitized by Google

was dry and brown. Respirations shallow, about fourteen in the minute. Pulse 120, regular, soft. Temperature 97° F. No abnormal physical signs were found in the thorax or abdomen. The urine was slightly acid, clear, and of a dark brown colour, changing to green on the addition of nitric acid; there was no precipitate on boiling, but acetic acid either before or after boiling gave rise to slight opacity; no sugar.

Past history.—Quite uncertain.

Necropsy.—The *brain* presented nothing abnormal.

The *heart* was of about normal weight, and showed nothing noteworthy.

In the *lungs* a few small subserous petechial patches and one small recent hæmorrhage infarction was observed. The bronchial glands were slightly enlarged.

Kidneys rather hard, capsule slightly adherent in parts.

Spleen weighed about 7½ oz.

Pancreas apparently natural.

In the *large intestine* some redness of the mucous membrane and enlargement of the lymph-follicles were observed.

The *liver* (weight about 55 oz.) was of rather firm consistence, as it would be if there were some fine cirrhotic process in progress. No hobnail appearance. Microscopic examination shows, firstly, that there is a considerable amount of uniform cirrhotic change, mainly "interlobular" in distribution; and secondly, that the liver cells have undergone a very marked (doubtless acute) fatty degeneration.

Remarks.—Owing to the deficient history the explanation of the case is not quite obvious. No information pointing to the exact cause of the cirrhosis was obtained, and no bacteriological examination of the liver was made. The pathological anatomical sequence of events seems to me clearer. A chronic interlobular fibrosis (whatever its cause may have been) of the liver doubtless already existed, when the acute degeneration of the gland-cells gave rise to the fatal termination with jaundice and cerebral symptoms.

It is almost useless to speculate as to the original cause of the hepatic disease. For such a chronic interlobular cirrhotic change without much increase in the bulk of the whole organ there are probably many possible causes. Aufrecht's experiments, however, throw much light on the whole subject. This observer[1] produced

[1] 'Deutsches Archiv für klin. Medicin,' Bd. lviii, S. 302.

Digitized by Google

a cirrhosis of the liver in rabbits by small repeated doses of phosphorus. He thinks that small doses of phosphorus lead to partial atrophy of the hepatic cells in the outer zones of the acini, giving rise to the appearance of interstitial inflammation between the acini. Some of the cases of acute atrophy supervening on chronic cirrhosis of the liver in man may be explained by supposing that the chronic action of some irritant leads at first to a progressive cirrhosis, and that afterwards a sudden increase of the irritant process (such as may be set up by intestinal catarrh) brings on acute degeneration of the remaining glandular cells and the symptoms of icterus gravis. *February 7th*, 1899.

---

34. *Diffuse infiltration of the liver in congenital syphilis.*

By H. Morley Fletcher, M.D.

The specimens [1] were taken from the body of a female child aged 7 weeks, who was under my care in the Children's Hospital, Shadwell.

She was three weeks old when admitted. The mother stated that ten days after birth she noticed that the child's belly was swollen and apparently tender. There had been no jaundice or vomiting. The bowels were regular, the stools green, but not offensive. The child was said to have had snuffles, but no rash. There were seven other children alive and healthy, and besides these the mother had one born dead, but no miscarriages. No further evidence of a history of syphilis was obtainable.

The child appeared well nourished on admission, was free from any form of skin eruption, and had no snuffles.

The abdomen was greatly distended, and the superficial veins were prominent. The liver occupied the greater part of the abdominal cavity, the edge reaching half an inch below the umbilicus. The spleen could not be felt. Slight peritoneal friction could be felt over the liver when the child cried There was no great abdominal tenderness and no evidence of free fluid in the abdomen. The case was treated as one of congenital syphilis with mercurial inunction, and later with grey powders.

[1] St. Bartholomew's Hospital Museum, No. 2202r.

Digitized by Google

When the child was five weeks old it began steadily to lose flesh, its general condition up to this time having been fairly good. The temperature throughout the course of the illness was irregular, ranging from 100° to 102°. There was also a good deal of diarrhœa, the stools being generally of a brown or yellow colour, though occasionally green. There was no trace of jaundice at any time, nor was there œdema. The child died when seven weeks old, having been in the hospital for four weeks. I am indebted to Dr. Shardlow, the resident medical officer, for these notes.

The *post-mortem* examination was made by Dr. Shardlow.

The body was wasted. Neither eruptions nor petechiæ were present.

The *lungs* and *bronchial glands* were natural.

The *heart* weighed 1 oz., and had a patent foramen ovale.

Abdomen.—There was no ascites.

The *liver* weighed 28 oz. It was generally enlarged and very hard. There was slight roughening on the upper surface, which probably caused the peritoneal friction felt during life. The capsule was thickened. The upper surface was fairly smooth, but had a blotchy appearance. The under surface was much more uneven and nodulated, though the irregularities could hardly be said to amount to scarring.

The right supra-renal was firmly adherent to the under surface of the right lobe of the liver. The gall-bladder was distended with bile. Nothing abnormal could be detected in the portal or hepatic veins. There were no petechiæ on the serous surfaces. The section of the liver showed a remarkable mottled appearance, due to large brown patches mingled with paler areas. The brown colour was due to hæmorrhage. The amount of fibrosis was not apparent to the naked eye, though there was obviously but little normal liver substance left. No circumscribed masses or nodules resembling gummata could be seen.

Both *supra-renals* were nearly as large as the kidneys, and on section had a transparent appearance with a deep chocolate colour, which was much darker in the medullary portion. The usual distinction between cortex and medulla was entirely lost.

The *spleen* (¾ oz.) showed no naked-eye changes.

The *kidneys* appeared normal.

The *intestines* and *mesenteric glands* were normal.

Microscopical examination of the liver.—The capsule is thickened.

Digitized by Google

There is an extreme degree of fibrosis, which is most marked in the portal spaces. The fibrosis is so extensive, and has led to such great destruction of liver cells, that it is difficult to recognise any well-marked pericellular cirrhosis. Here and there may be seen a few small isolated clumps of fairly healthy-looking liver cells. There is a nearly continuous narrow layer of almost normal liver cells immediately under the capsule. In the dense masses of fibrous tissue can be seen very numerous slender branching tubules, some containing bile pigment. These somewhat resemble the so-called newly formed bile-ducts, but it is more probable that they are the remains of liver cells separated in columns by the fibrous tissue, and much compressed. In places the continuity of these slender columns of cells with a clump of healthy cells can be demonstrated.

The most striking microscopical change is a diffuse infiltration of the liver by small round cells. Under a high power it is found that the majority of these cells are small round cells, not unlike those found in some primary sarcomata of the liver. Between the cells can be made out a delicate reticulum and spindle-shaped cells with oval nuclei. There is evidently very active connective-tissue formation in progress. There is great vascularity and considerable hæmorrhage in these parts. In no place is there the slightest trace of any caseation. The vessels show no change. The sections gave no lardacein reaction.

Sections of the supra-renal capsules show an extensive destruction of the cortex by a small-celled infiltration closely resembling that in the liver. The whole of the medullary portion is filled with hæmorrhage and organising blood-clot. Hæmorrhage into the supra-renals in infants is not an event of great rarity, but the cases described are generally associated with purpuric eruptions and fever. I have been unable to find any similar cases recorded in connection with congenital syphilis. In describing a case of pericellular cirrhosis in an infant of ten weeks, Penrose[1] states that the supra-renals were "of a dull red-grey colour, quite unlike ordinary supra-renal colour." No microscopical account is given. The colour is the same as in the case I am describing. There are hæmorrhages in the kidney also, but the structure appears otherwise normal. Sections of the spleen show nothing of interest.

The question naturally arises as to the nature of the extensive

[1] Penrose, 'Path. Soc. Trans.,' vol. xxxix, 1888, p. 135.

Digitized by Google

small round-celled infiltration present in the liver. There are some points of resemblance between this and two cases of primary round-celled sarcoma of the liver which have been described in the 'Transactions' of this Society, one by Dr. Norman Dalton,[1] and the other by G. Heaton.[2] The former of these shows an infiltration of the organ by cells closely resembling those I have described, but there can be little doubt that this was a case of congenital sarcoma. In neither case was there anything approaching the amount of fibrosis which is found in congenital syphilis.

It must be admitted that the evidence of syphilis in this case, though strong, is not conclusive, but the cirrhotic changes in the liver can hardly be due to any other cause. A series of closely similar cases, with diffuse infiltration of the liver, has been described by Marchand.[3] In most of these the liver was greatly enlarged, and of a dark brownish-red colour. Ascites and petechiæ were generally present. Marchand points out that this diffuse infiltration is only found in children who die shortly after birth. It is possible, as Wilks[4] suggested in describing a case of syphilitic cirrhosis in an infant in 1866, that some such changes might be present in the active stage of acquired syphilis. Hutinel and Hudelo[5] describe the condition in the fœtal or new-born liver as a "diffuse embryonal infiltration," a term implying that an active proliferation in the young connective-tissue elements is set up by an exciting agent brought probably by the umbilical vein. Hence the resemblance to a sarcomatous growth, another form of connective-tissue proliferation. It is possible to mistake a syphilitic liver with this diffuse infiltration, or "diffuse gummatosis," as Hutinel and Hudelo have called it, for a congenital diffuse round-celled sarcoma, and it is probable that some of the so-called diffuse sarcomata which have been thus described are really syphilitic in origin.

November 1st, 1898.

[1] 'Path. Soc. Trans.,' xxxvi, 1885, p. 247.
[2] Ibid., xlix, 1898, p. 140.
[3] 'Centralblatt für allgem. Path.,' 1896, Bd. vii, S. 273.
[4] S. Wilks, 'Path. Soc. Trans.,' xvii, 1866, p. 167.
[5] Hutinel and Hudelo, 'Archiv. de Méd. expérimentale,' 1890, p. 509.

Digitized by Google

35. *Diffuse syphilitic change in the liver.*

By F. Parkes Weber, M.D.

The patient (a carman), C. W—, aged 47, was brought to the German Hospital, February, 1898, in an apoplectiform condition, due to cerebral hæmorrhage. As evidence of syphilis (for which he had recently been under treatment) there was a perforation of the palate and disease of both testes, one being uniformly enlarged and the other fungating. The temperature varied between 100·2° and 102·2° F. He lived three days after admission. The primary syphilis had probably been acquired several years ago.

Necropsy.—Besides the cerebral hæmorrhage and evidence of syphilitic disease of the testes, glottis, and palate, there was pneumonia at the base of one lung, and slight interstitial fibrosis of the kidneys.

The *spleen* weighed about 14 oz., and microscopically presented nothing remarkable.

The *liver* weighed 67 oz., and was indurated, but no distinct gummatous masses or scarring were noted. Microscopic examination of the organ shows a remarkable diffuse change, differing in degree in different parts. In the sections exhibited to-night the amount of change is very considerable; a great portion of the glandular cells have disappeared, their place being taken by a fibrous material, which in most parts is not very rich in nuclei. The feature to which I wish to draw attention is that the fibrous change is generally most advanced in the central portions of the acini, and least noticeable around the portal spaces. In fact, the change is quite distinct from that of all ordinary cases of cirrhosis, in that the best preserved liver cells are those at the periphery of the acini, precisely those which are most likely to be encroached upon in ordinary cirrhosis.

This is not the only case in which I have observed the peculiar feature in question. Perhaps it is exclusively to be found accompanying diffuse syphilitic change, and it is on this account that I have brought the present case before the Pathological Society.

Professor Adami[1] has recently drawn special attention to the

[1] "On the Stages and Forms of Syphilis, with more especial reference to the

Digitized by Google

diffuse changes in the liver met with in some cases of acquired syphilis. He points out that the hepatic changes are found to be essentially of the same order, whether the affected liver be examined in the first year after primary syphilis or long afterwards, though the longer the time that has elapsed after infection the greater is the tendency to the development of cicatricial changes with contraction and deformity of the organ. He writes: "It is generally laid down that in tertiary syphilis affecting the liver, gummata, whether well-marked and caseous, or the cicatrised remains of such, with well-formed stellate surroundings of fibrous bands, are the characteristic changes in the organ, while a condition of generalised and pericellular cirrhosis is wanting. It must, however, be remembered that even years after the primary affection such cirrhotic change may be recognisable, and not a few cases are on record of such a condition." The diffuse change in the liver found in the present case abundantly confirms Adami's words, though the precise lapse of time since the primary syphilitic infection is uncertain. Adami proceeds to describe special instances of tertiary syphilis of the liver in which he has met with circumscribed areas of pericellular fibrosis.

A process of pericellular fibrosis must indeed be recognised as occurring in the liver of acquired syphilis, similar to that which has long been recognised as characteristic of hepatic disease due to congenital syphilis of children. Miliary gummata, moreover, certainly occur in the livers of adults as they do in those of infants, and in all probability in the acquired as well as in the congenital disease. In the present case, although the liver showed no distinct gummata or scars from old gummata, there was a more or less generalised fibroid change, which may be regarded as the result of a process commencing with pericellular cirrhosis, analogous to that spoken of by Adami.

A fact, however, which, as I have already stated, should be noted in the present case, is the decided tendency of the fibrotic process to invade the whole inner area of the acini, and to leave the outer zone of hepatic cells least affected. This tendency of the diffuse syphilitic change to spare the hepatic glandular cells nearest to the interlobular spaces is certainly not peculiar to the present case. I have noticed it in some other cases, though apparently it has not

Hepatic Manifestations of the Disease," published in the 'Montreal Medical Journal,' June, 1898; and in 'Treatment,' London, November 24th, 1898.

Digitized by Google

been recorded by other observers, who have perhaps regarded it as too unimportant to mention. There is, however, possibly a special significance to be attached to it, which I shall now endeavour to explain.

The glandular cells which in these cases suffer most are, I repeat, those of the middle and inner zones of the hepatic acini, those which are least affected in ordinary forms of cirrhosis, but which suffer most in chronic passive congestion (nutmeg liver[1]) and amyloid disease.[2] The middle and inner zones of the acini are those supplied by the finest branches of the hepatic artery. In fact, this form of "diffuse syphilitic cirrhosis" may be termed "pericapillary" quite as justly as "pericellular."

The distribution of the fibrotic change in ordinary cirrhosis, which is chiefly "periportal" (the glandular cells of the outer zones suffering especially), has been supposed by many to point to the portal vessels as the channels by which, in such cases, the agents are introduced which injure the hepatic cells and determine the fibrosis. The distribution of the change in a "diffuse syphilitic cirrhosis" (when it resembles that of the present case) has led me to suspect that some abnormal condition of the arterial blood-supply may be the chief determining cause of this variety of cirrhosis. A striking histological feature in some cases of cardio-sclerosis (fibroid disease of the heart muscle) is that the most affected portions of the myocardium, where the muscle-fibres have almost completely undergone fibroid degeneration, are precisely those portions which are furthest removed from the small branches of the coronary arteries from which their blood-supply is derived. The cardiac change has, therefore, been supposed by some observers to be due to ischæmia brought about by an arterio-sclerotic change, which causes narrowing of the lumina of the small arterioles. In the case of the liver, however, the explanation of the somewhat analogous change which is shown by my sections must remain, at least for the present, still more doubtful. *March 21st*, 1899.

[1] The change in the centres of the acini resulting from chronic passive congestion of the liver occasionally resembles a real fibrosis when examined under the microscope; the term "centro-acinous" cirrhosis has, I believe, probably incorrectly, been applied to it.

[2] It may be remarked that sections stained with methyl violet for amyloid disease gave a negative result in the present case.

Digitized by Google

36. *A case of cirrhosis of liver, apparently due to congenital syphilis, with thrombosis of the hepatic veins.*

By T. CHURTON, M.D.

A MAN aged 26, whose father died at fifty of apoplexy, his mother at fifty-six of anæmia, his elder and only sister in infancy, and who had never been strong, noticed some enlargement in the epigastric region two years ago; but though somewhat sallow, and for the last three or four months rather languid and inefficient at his work, had not been seriously ill until a week before his death. On July 26th a planing machine weighing 6 cwt. fell upon, or rather, perhaps, against his right arm (? and side), bruising the arm severely. He could not work, but did not seem ill.

On August 4th he had diarrhœa for two days.

6th.—Abdomen began to increase in size.

9th.—Felt weak; abdomen larger; occasional pain in it; no superficial veins visible (Dr. J. H. Woods). Was walking about.

10th.—Much more ascites; surface veins conspicuous; was sent the same evening to the Leeds Infirmary. The history of previously perfect health then given, but subsequently found to be incorrect, caused a suspicion of hydatid. Tapping the lower abdomen obtained only 2 or 3 pints of blood-tinged fluid; after this a fluid thrill could be obtained over the liver in any position of the patient. On August 13th, as the man was worse, a small exploratory incision was made over the liver margin. This showed the nature of the case, and that fluid had apparently been imprisoned between the liver and diaphragm. The fluid re-accumulated rapidly; no peritonitis occurred, but the exhaustion increased and the patient died two days later.

Necropsy.—In the centre of the cirrhotic liver was found a hepatic vein containing an old whitish clot; the other branches of the vein contained dark red fresh or recent clot. The mouth of the vein in the vena cava was very narrow and completely blocked by whitish clot, so that it was not easily found. Microscopically, the thrombi are in some parts adherent to or rather fused with the wall of the vein and the connective tissue beyond, as though the connective tissue had invaded the vein and projected into it. The main veins are not much, if at all, enlarged. The intra-lobular

Digitized by Google

radicles are, however, some of them distended. The portal veins are not thrombosed. The cirrhosis is diffuse, intercellular and chiefly monolobular. The outer parts of some of the lobules appear to have been converted into "new bile ducts." The transition is (or appears to me to be) traceable by the staining of the protoplasm of the liver-cells, which shrink until the bare nuclei—larger, rounder, and less deeply tinted than the connective tissue nuclei—form parallel rows or small circles of nuclei lying in a canal formed by connective "protoplasm" or "basement membrane." No effusions of blood are visible.

Upon the disputed question as to whether congenital syphilis can cause a fibrosis so uniform as this, and a phlebitis with consequent thrombosis, I can offer no opinion, but I have twice in the same patient treated a case of acute uniform enlargement of the liver in a young man, four years after acquired syphilis, with mercury with suggestively rapid success. In the present case no other cause, lead, malaria, alcohol, dyspepsia and auto-intoxication, or acquired syphilis could be found.

November 1*st*, 1898.

---

37. *Thrombosis of hepatic vein associated with cirrhosis of the liver, probably syphilitic.*

By W. S. Lazarus-Barlow, M.D.

This specimen was obtained from the body of a boy aged 13 years, who had enjoyed good health until the last four months of his life. The commencement of his illness showed itself by enlargement of the abdomen, and he sought admission to hospital by reason of general languor and breathlessness, coupled with hæmatemesis and melæna. On admission the abdomen was noticed to be covered by a plexus of distended veins; he was thin, slightly jaundiced, bore distended venules on the cheeks, and had considerable ascites with great respiratory distress. The edge of the liver was felt three fingers' breadths below the costal margin. With regard to the question of syphilis, the evidence available was (1st) that the mother had had no miscarriages up to this, the third child, but four afterwards; (2nd) the histological character of the

Digitized by Google

hepatic fibrosis. The patient's teeth were normal, and he had no interstitial keratitis. There was no alcoholic history. During his sojourn in the hospital the patient was tapped twice, considerably over twelve pints of fluid being removed in the two tappings. He gradually sank after the second paracentesis.

At the autopsy there was found a localised suppurative peritonitis. The liver weighed 2 lb., 10 oz., was granular and mottled on the surface. On the upper surface posteriorly was a large mass of cicatricial tissue which extended 1½ inches into the depth of the organ and involved the hepatic vein. Numerous branches of the hepatic vein, both large and small, were occluded by partially adherent and decolourised thrombus. The cicatricial mass suggested a former gummatous condition, and its edges shaded off in the form of trabeculæ of fibrous tissue into the (macroscopically) normal substance of the liver. At the same time the branches of the portal vein served as centres of a fibrous-tissue overgrowth throughout the organ, so that a section revealed macroscopically a mottled surface, in which foci of what appeared to be normal liver substance were separated by irregular trabeculæ of fibrous tissue which stretched in all directions. Here and there were seen sections of the occluded hepatic vein.

Microscopically the liver, even in its apparently most nearly normal regions, showed the existence of a mixed fibrosis. The greater part was of the multilobular variety, but there was much of the intercellular type. None of the white masses in the liver were found to be gummatous.

Remarks.—Thrombosis of the hepatic vein appears to be a somewhat uncommon condition, nevertheless several cases are on record. In a communication by Kelynack[1] on the same subject, reference is made to a case published by Frerichs, and in the notes of a case reported by Gee[2] reference is made to an autopsy made by von Recklinghausen, and published by Rosenblatt, in which the same condition obtained. In none of these cases was the occurrence of syphilis certain, though for the most part its occurrence was highly probable. In Gee's case, which was one of a child aged 17 months, the hepatic veins were cut off from the inferior vena cava by a thin membrane, and the positions at which these veins should normally open into the vena cava were only represented

[1] 'Medical Press and Circular,' vol. cxv, 1897.

[2] See 'St. Bart.'s Hosp. Rep.,' 1871, p. 144.

Digitized by Google

by small dimples. In Kelynack's case the aperture of only one hepatic vein into the vena cava was distinguishable, and this was only large enough to admit a small probe. In the present case no abnormality of this kind was present. It is therefore impossible to determine how far stenosis induced by contraction of cicatricial tissue may play a part in inducing the thrombosis, but it must be mentioned that in Gee's case it is expressly mentioned that the appearances about the junction of the vena cava and the hepatic veins were quite dissimilar from those of ordinary scars.

The specimen is preserved in the museum of St. George's Hospital, series ix, 174 I. *November 1st*, 1898.

---

38. *Liver in hepatic and portal thrombosis.* (*Card specimen.*)

By H. D. Rolleston, M.D.

The liver weighed 46 oz., and to the naked eye appeared atrophied and nutmeggy. The portal spaces were unduly prominent, but there was no evidence of ordinary cirrhosis.

Microscopically the liver cells are extremely atrophied and are shrunken, while the fibrous tissue of the portal canals is so prominent, that it seems difficult to doubt that it has undergone some increase in size. No doubt the atrophy of the liver cells shows up the normal fibrous framework, but some increased growth on the part of the interstitial supporting framework—a fibrous replacement—may well be expected under such circumstances. There is, however, no small-cell growth or evidence of recent hyperplasia in the fibrous tissue.

The result of hepatic and portal thrombosis in this specimen, then, is atrophy of the hepatic cells and greater prominence of the fibrous framework.

At the *post-mortem* there was an old parietal clot in the inferior vena cava, which did not interfere with the passage of blood through it. The adherent clot was situated near the openings of the hepatic veins. The right hepatic vein was blocked up by a thrombus of about the same age as that on the inferior vena cava,

Digitized by Google

while the left hepatic vein was free. There was no continuity between the thrombus in the right hepatic vein and the parietal clot in the inferior cava, but it seems highly probable that they were not independent of each other. There was thrombosis of more recent date in the portal and splenic veins. It seemed not unlikely that the portal thrombosis was secondary to the thrombosis in the right hepatic vein, and was related to venous stagnation and changes in the vitality of the liver cells. The spleen weighed 9 oz., and did not contain any infarcts; the weight is, perhaps, worthy of note as bearing out the general rule that in mere mechanical congestion, without any toxic or septic condition, the spleen is not enlarged. I have on several occasions, however, seen such enlargement in cases of simple thrombosis of the splenic vein so as to suggest that when the obstruction is so close to the spleen as in the efferent vein, the general rule which applies to the backward pressure, due to obstructive heart or lung disease, does not necessarily hold good.

Death was due to concealed hæmorrhage into the stomach and intestines, which were found full of blood. There were numerous small hæmorrhages into the skin, mediastina, and substance of the pericardium. These were probably due to hepatic insufficiency, allowing poisons which should have been destroyed to circulate freely. During life ascites which required paracentesis and rapidly reaccumulated occurred, and was evidently due to portal thrombosis.

November 15*th*, 1898.

---

39. *Cysts in the liver containing living* Paramœcia coli.

By A. E. Russell, M.D., and E. F. Buzzard, M.B.

The patient was a man aged 59, who was admitted into St. Thomas's Hospital with carcinoma of the stomach. There was nothing unusual in the history nor in the course of the disease. Death occurred rather unexpectedly on May 6th, 1898.

At the *post-mortem* examination there was a large malignant growth of the pylorus, the orifice being so stenosed as only to admit

Digitized by Google

the tip of the little finger. At the pylorus the growth was three quarters of an inch in thickness; it extended for four inches on the stomach, involving its circumference uniformly. The mucous membrane at the pylorus and for about two inches on the stomach-wall had disappeared. The stomach was enormously dilated. There were no secondary growths anywhere. The liver was normal, save for the presence of about a dozen small cysts situated in the region of the larger portal canals. In size they were barely as large as peas. They were firm to the touch, and contained brownish or orange-stained material of caseous consistence. The contents of two of the cysts were found to contain living *Paramœcia coli*, which were identified by Dr. Hawkins.

Examination of mounted and stained specimens showed that the cysts possessed a thick fibrous wall and almost structureless contents, the presence of what appeared to be faint nuclei suggesting indefinitely necrosed liver tissue. Unfortunately the specimens did not show the parasites, presumably on account of their delicate structure and poor staining qualities.

According to Leuckart, the *Paramœcium coli* is an almost constant parasite in the pig, occurring in the cæcum and colon. It was first discovered as a human parasite by Leuwenhoek. Malmsten, however, was the first to recognise it as being associated with any pathological process, finding it in cases of diarrhœa. Mitter regards it as proved that infection is conveyed in some means from the pig, either by inhalation of the encysted parasite, which may frequently be found in the fæces of the pig, or through contaminated food. Schneidemuhl[1] gives references to the cases in the literature, altogether some thirty-six having been recorded. The parasite appears to be associated with diarrhœic conditions, and may be the exciting cause of an attack, or aggravate the condition in such diseases as cholera, dysentery, &c. In the case under notice, constipation with light-coloured stools appears to have obtained, and there was no history of any diarrhœa.

As regards the cysts, the most reasonable assumption seemed to be that they owed their origin to an irritative process set up by these parasites, and that the latter found their way into the liver from the intestinal tract by way of the common bile-duct, the

[1] 'Die Protozoen als Krankheitserreger des Menschen und der Hausthiere,' 1898.

Digitized by Google

bile-stained contents of the cysts suggesting an origin in the bile-duct system. All the cysts were of about the same size, and it is possible that the parasites reached the liver simultaneously.

At the meeting Mr. Shattock observed that the case was unique, and agreed as to the location of the parasites in the bile-ducts. The condition was in some respects comparable with that of psorospermosis in the rabbit's liver, in which the protozoa certainly wandered from the intestine up the bile-ducts; in fact, the condition was a "paramœciosis." In the psorospermial liver the dilated ducts became the seats of complex papillary ingrowths, but nothing of this kind was shown in the cysts described.

April 18th, 1899.

40. *Biliary calculi in children.*

By George F. Still, M.D.

Gall-stones are a rare occurrence in childhood, but it is important that it should be realised that this period of life is by no means exempt from them. The following three cases have occurred within the past six months at the Hospital for Sick Children, Great Ormond Street.

Case 1.—Carrie B—, aged 9 months, was admitted under the care of Dr. Lees for vomiting and wasting. The bowels were very costive; the child was irritable, and had been feverish at times; there was some cough. Feeding had been by breast for the first six weeks, then cow's milk (boiled) with barley-water, and lately condensed milk, to which more recently some brandy had been added. There was no history of jaundice.

On admission the child was pale and emaciated; eyes sunken; fontanelle depressed; purpuric patches on the trunk; no jaundice. The heart and lungs were normal. The stools were hard and "clay coloured." Purpura increased; vomiting was frequent but not persistent; diarrhœa supervened, and the child became more exhausted and died. No symptoms of colic or abdominal pain and no jaundice were observed during the five and a half weeks that the child was in the hospital.

Digitized by Google

Post-mortem.—Some broncho-pneumonia and recent pleurisy were found; the pelves of both kidneys were dilated, and there was some secondary nephritis. The liver was of normal size, rather dark in colour, but otherwise seemed perfectly normal. The gall-bladder was filled with golden-yellow bile, and on opening it eleven small calculi were found, the smallest about the size of a pin's head, the largest measuring 3·5 mm. × 2 mm. They were angular in shape, dull black in colour, and easily friable on pressure. Adherent to some of these little calculi and entangling them was thick viscid material, apparently inspissated bile, probably with some mucus.

Three of these calculi, rather smaller than the largest mentioned, were found impacted in the common duct about 1·5 cm. above the duodenal opening. They did not completely block the duct, apparently, as bile could be squeezed through from the gall-bladder; but as this was tried before opening the bladder, it was possible, though I think very unlikely, that these calculi had been driven there by pressure during this examination. So far as could be ascertained from a careful examination of one of the minute fragments, they contained no cholesterin, but consisted mainly of bile pigment.

Case 2.—May T—, aged 8 months, was admitted under the care of Dr. Barlow with cerebral symptoms of five days' duration. The child had been ailing since measles two months previously, and died two days after admission. The history was very incomplete: but no mention was made of jaundice or of abdominal pain. The child had been breast-fed until one month before admission, and since then some patent food had been given.

Post-mortem.—There was acute miliary tuberculosis, with tubercular meningitis. The liver showed numerous grey tubercles on its surface and in its substance, but otherwise seemed normal. The gall-bladder contained some golden-yellow bile; near its neck there was a small area about 3 mm. in diameter where the mucous membrane showed superficial erosion, and adherent to this was some thick mucus, entangled in which was one of the minute calculi shown. Only three of these minute concretions were present, and inasmuch as they are barely the size of a pin's head, they are hardly worth calling calculi, but are of importance only as showing the tendency to formation of calculus. They were too minute to allow of any satisfactory chemical examination.

Digitized by Google

Case 3.—Henry C—, aged 5 months, was admitted under Dr. Barlow for vomiting and wasting of three months' duration. Sometimes he seemed to have pain in the abdomen, screaming and drawing up his legs. The bowels were costive, there was much straining at stool, which was of a pale colour. Breast milk had been given until three months ago, then boiled milk with water (equal parts). There was no history of jaundice.

On admission the child was emaciated, with sunken eyes and depressed fontanelle; the abdomen was retracted; the liver was felt one and a half fingers' breadths below the costal margin in the right nipple line; there was no jaundice. A few râles and rhonchi were heard over the lungs; the heart was normal. There was occasional vomiting; diarrhœa supervened; the child wasted and became more exhausted, and died four weeks after admission. No abdominal pain was observed.

Post-mortem.—There was slight broncho-pneumonia. The liver appeared perfectly normal both to the naked eye and on microscopic examination. The gall-bladder was moderately full of rather dark amber-coloured bile, and in the fundus of the bladder were three small calculi, the largest being about the size of a millet seed, measuring nearly 3 mm. × 2 mm. and being roughly oval in shape with rounded contour, not angular. The colour was a dingy black, the consistence was very hard, but they were friable under considerable pressure. No calculi were found in the liver substance. Examination of one of these calculi showed no trace of cholesterin; the stone seemed to be made up almost entirely of bile pigment associated apparently with some carbonate, as a few bubbles of gas escaped on adding an acid.

A fourth case is perhaps worth mentioning in this connection, for although no gall-stones were seen, it appeared from the clinical symptoms to be one of biliary calculi. A boy, aged ten years, recently came under my observation suffering from attacks of abdominal pain at intervals of a few months. About six years ago he was admitted under the care of Dr. Barlow for severe abdominal pain with vomiting and jaundice. A fluctuating tumour could then be felt in the position of the gall-bladder, and indeed it was thought that it might be the distended gall-bladder. The swelling suddenly subsided, the jaundice passed off and the child seemed well, but since then has had repeated attacks of abdominal pain which last

Digitized by Google

about half an hour, and are referred to the umbilicus. During these attacks the mother says the boy is of a sallow colour, but it seems doubtful whether he is actually jaundiced. The liver is now slightly enlarged, and feels firmer than normal. The diagnosis of biliary colic seems at least probable in this case.

Here, then, are three cases in which gall-stones were actually found in children, and other similar cases have been recorded. I have been able to find altogether twenty published cases[1] in addition to those recorded here.

Of the twenty-three cases thus collected, ten were in infants who were stillborn or died within a few weeks of birth; one is simply stated to have been "an infant;" four were between three months and nine months of age; and eight were in children from about three to fourteen years old. In all these cases the calculi were actually seen, in four cases in the fæces during life, in the rest at the autopsy.

Of the ten cases which occurred in newborn children, seven are stated to have been jaundiced, and in most of these the jaundice was present at birth. Abdominal pain, apparently of the nature of colic, was also present in some of these cases, but not in all.

In one case (Bouisson) some narrowing of the ductus choledochus was also found; in another (Cuffer) the gall-bladder appeared to be shrunken. A tendency to hæmorrhage was also associated with the latter case; hæmaturia and hæmorrhage from the bowel were present during life, and hæmorrhage into the psoas muscle was found after death. The jaundice in these new born infants was very intense, and in five of the cases was shown *post mortem* to be due to impaction of calculi in the bile-ducts. It is evident, therefore, that biliary calculus must be reckoned amongst the causes of icterus neonatorum of a severe and persistent variety, which in some cases at least ends fatally.

The presence of gall-stones in later infancy and in childhood has rarely been associated with any distinctive symptoms during life. The occurrence of jaundice with colic was recorded only in one (Walker) of the thirteen cases, while in another (Case 3) it was

[1] Only cases in which the gall-stones were actually seen are included in these statistics, and only those which occurred not later than fourteen years of age. Several other cases are on record where colic, supposed to be biliary in origin, occurred in childhood (*vide* Mercat, "Colique Hépatique chez l'enfant," 'Thèse de Paris,' 1884).

Digitized by Google

especially stated that the child had screamed much and drawn up its legs as if in pain. In the remaining eleven cases no special symptoms of calculus were recorded. It is to be remembered, however, that five of these thirteen cases occurred in infancy, when pain in the abdomen is so apt to be overlooked or to be attributed to such common causes as flatus or dyspepsia, and it is quite possible or even probable that some pain may have been present in other cases besides the two in which it was mentioned. At any rate, both in the new-born and in these older cases definite abdominal pain was sometimes observed, and it seems almost certain that the impaction of calculi in the ducts, as in Case 1 recorded above, or even the passage along the ducts of such calculi as were found in Case 3, must be attended with some degree of pain.

I lay some stress on this point because these little biliary concretions are much more common in early infancy than at any other period of childhood, and it is quite possible that biliary colic may be the cause of some of the obscure screaming attacks with drawing up of the legs which are so common in infancy, and which are sometimes so difficult to assign to any definite cause. The passage of calculi along the bile-ducts, like the passage along the ureters of the uric acid concretions, which one finds so often in the infantile kidney, is certainly an occasional cause, perhaps a more common one than we suspect, of colic in infants.

As regards the ætiology of gall-stones in childhood, one point seems to be of special importance, namely, the much greater tendency to formation of gall-stones during early infancy than in later childhood. Fifteen out of the twenty-three cases collected here were infants, and fourteen of these were under the age of ten months; and this preponderance of infants seems to be independent of sex. Of seven infants in whom the sex were recorded, four were males, three were females. Further, as Dr. John Thomson has pointed out, it seems quite certain that in many, if not in all, of the new-born cases the calculi have actually been formed during intra-uterine life.

It would appear, therefore, that some condition is present during intra-uterine life and early infancy which particularly favours the production of biliary concretions. This condition is perhaps to be found in the tendency to stagnation of bile in the gall-bladder, which seems to exist at this period. In making a considerable number of autopsies on infants it has struck me, as it seems to

Digitized by Google

Cases of Biliary Calculus in Childhood.

No.	Age.	Sex.	Symptoms.	Remarks.	Reference.
1	Stillborn about the 8th month	—	Jaundice	Calculus impacted in common duct	Lionel S. Beale, 'Slight Ailments,' Lond., 1880, p. 121.
2, 3, 4	Newborn	—	—	Minute calculi in each case, the largest the size of a pin's head; blackish colour	Valleix, 'Maladie des enfants,' Paris, 1838, p. 316.
5	Newborn	—	Intense jaundice	Three calculi found in common duct, and some narrowing of the duct	Bouisson, quoted by Frerichs, 'Leberkrank.,' Bd. ii, 488.
6, 7	"Died shortly after birth"	—	Intense jaundice	Bile ducts filled with biliary calculi	Portal, 'Maladies du foie,' Paris, 1813, p. 125; *vide* also p. 128.
8	20 days	M.	Jaundice, pain in belly, constipation, retching	Several calculi in gall-bladder, largest 6 mm. long; dark brown rusty colour; commencing cirrhosis of liver	J. Thomson, 'Edinb. Hosp. Rep.,' vol. v.
9	25 days	—	Intense jaundice	Several calculi in gall-bladder and ducts	Lieutand, 'Mem. Acad. Roy. de Méd.,' Paris, 1847, xiii, 237.
10	29 days	M.	Jaundice when first seen at 12 days old	Calculi blocking common and cystic ducts	Cuffer (from Parrot's Clinique), 'Bull. Soc. Anat.,' 1877, ii, 478.
11	"Infant"	F.	—	Calculi found *post mortem*	Roth, 'Festchrift R. Virchow,' 1891, p. 5.

Digitized by Google

12	3 months	M.	Jaundice and colic	Three calculi, apparently cholesterin, passed from intestine	Walker, 'Brit. Med. Journ.,' 1882, i, 575.
13	"Less than 4 years"	—	Colic	Gall-stones passed in fæces	Andouart, 'Journal de Méd. de l'Ouest,' series i, 3.
14	About 5 years	F.	Colic	Gall-stones passed in fæces	Simon, quoted by Mossé, 'Thèse d'Agrégation,' 1880.
15	7 years	F.	None	Calculi associated with lardaceous disease of liver	Frerichs, 'Leberkrankheit,' ii, 488.
16	10 years	M.	—	Gall-stones passed in fæces	Wolff, 'Virchow's Archiv,' xx, p. 1.
17	12 years	M.	—	Many gall-stones of yellowish colour in common duct; gall-bladder enormously distended with bile	Gibson, quoted by Thudichum, 'Treatise on Gall-stones,' p. 205 (probably same as "Gibbons," quoted by Servenière, "Lithiase biliaire dans l'enfance," 'Thèse de Paris,' 1889).
18, 19	13 years, and "less than 13 years"	—	—	Gall-stones found *post mortem* in each case	Beverhoyt, quoted in 'Dictionnaire de Méd.,' 1822, iv, p. 59.
20	14 years	F.	—	Calculus, dark green, friable, weight 2 grms., found in gall-bladder	Orfila, quoted in 'Dictionnaire de Méd. et de Chir. Pratiques,' 1830.

Digitized by Google

have struck several of the writers on the anatomy of childhood, that the bile in the gall-bladder is often very viscid in early infancy, and such a viscidity would naturally favour, if, indeed, it be not the result of, stagnation.

That a mechanical hindrance which causes stagnation of bile may be associated with the formation of calculus is shown by the case quoted above, in which a narrowing of the common duct was associated with the presence of calculi.

Moreover, a potent cause of stagnation must exist in the muscular inactivity of this period; the contractions of the diaphragm in particular are probably completely in abeyance during intra-uterine life, and the general movements of the body are extremely slight. To a less degree, in extra-uterine life also, the feebleness of muscular activity, especially in the weakly infants in whom these calculi have been found, must favour the formation of biliary concretions. *April 4th*, 1899.

---

41. *Syphilitic stricture of bile-ducts.* (*Card specimen.*)

By W. S. Lazarus-Barlow, M.D.

The body from which the present specimen[1] was obtained was that of a boy aged 17 years. He was the subject of well-marked congenital syphilis, for which he was treated as an in-patient of St. George's Hospital in 1898. On the present occasion he was admitted for intense jaundice and weakness of gradual onset of several weeks' duration. Liver and spleen much enlarged; no ascites.

After treatment in hospital for two months, during which he suffered from vomiting at frequent intervals, though the jaundice improved somewhat, the patient died from erysipelas, to which on this, as on the previous admission, he had shown an extreme susceptibility. The erysipelas was complicated by recent pericarditis.

At the autopsy the body was extremely emaciated, and was of an olive-green colour. Nodes were present on the skull bones and the

[1] St. George's Hospital Museum, series ix, 191B.

Digitized by Google

left tibia. There was a small quantity of bile-stained fluid in each pleural cavity and in the peritoneal cavity. The lungs were normal. Except for a fine recent pericarditis the heart was normal. The alimentary tract was normal except for a perforation of the hard palate; the intestinal contents were devoid of bile-pigment. The other organs, with exception of liver and spleen, were normal. None of the organs gave the lardaceous reaction.

Liver and bile-passages.—The liver weighed 5 lbs., was of a dark green colour from retained bile, and was almost entirely constituted by an enormously hypertrophied left lobe, which was normal in its composition. The right lobe was very small, and showed numerous cicatrices and depressions, the seat of old gummata. One mass of fibrous tissue of this description especially involved the bile-ducts, but its major portion lay on the dorsal surface of the organ. The gall-bladder was of normal size, and full of dark green bile. The common bile-duct and the left hepatic duct were each the size of a No. 16 catheter; the ampulla at the blind end of the common duct was the size of a hazel nut. The left hepatic duct was not only dilated, it was also separated from the common duct by a thin but perfect membranous septum. There was some difficulty in deciding the position of the right hepatic duct, but it is apparently represented by a depression into which the tip of a small probe will enter, and situated in a small diverticulum in the ampulla at the blind end of the common duct. The author suggests that the bile found in the gall-bladder may have been derived from the atrophied right lobe of the liver through this stenosed right hepatic duct; it appears impossible that it should have been derived from the left lobe. The occlusion of the left hepatic duct is sufficient explanation of the severe jaundice which obtained. A gall-stone (bilirubin-calcium) was present in the dilated common duct, but did not in any degree occlude it. It was probably formed in the ampulla, judging from its shape and size. The spleen weighed 2 lbs. 13 oz.; it was much firmer than normal, but presented no special features beyond its size. *May 16th*, 1899.

Digitized by Google

42. *Tuberculous cavities in the liver.*

By HERBERT MORLEY FLETCHER, M.D., M.R.C.P.

[With Plate IV.]

IT is somewhat remarkable that so little notice of this form of hepatic lesion should have been taken in this country; in fact it is difficult to find any reference to it, whereas it has been freely described by foreign writers for many years past.

Judging by the number of cases quoted by French and German authors, the condition appears to be of more frequent occurrence abroad than it is in this country, though in all probability it is not of such great rarity here as might be supposed.

The history of the case is briefly as follows:

The patient was a boy aged 6, who was under the care of Sir Dyce Duckworth at St. Bartholomew's Hospital.

He was admitted in September, 1898, in an unconscious condition. He had been in his usual health till three days previously; he then became irritable, had severe headache, and rapidly grew worse. There was no jaundice.

He died the day after admission. The clinical symptoms pointed to its being an extremely rapid case of tuberculous meningitis, the duration of symptoms being less than a week. There was no family history of phthisis. For some months past the boy had suffered from repeated attacks of diarrhœa. He had had measles, but no other illness.

Post-mortem examination.—The *post-mortem*, made by Dr. Garrod, showed that the case was one of general tuberculosis. There was tuberculous meningitis. The lungs and pleuræ contained miliary tubercles. There was a large caseous bronchial gland attached to the right bronchus. The intestines and omentum were covered with tubercles. The jejunum and ileum contained many tuberculous ulcers, and there were a few in the large intestine. The spleen and kidneys contained miliary tubercles; the pancreas, supra-renals, ureters, and bladder were normal. The liver weighed 23 oz. The gall-bladder was natural and contained bile; the ducts were patent and were not dilated. There were many miliary tubercles in the substance of the liver, and a few under the

Digitized by Google

Digitized by Google

DESCRIPTION OF PLATE IV,

Illustrating Dr. H. Morley Fletcher's paper on Tuberculous Cavities in the Liver. (Page 160.)

FIG. 1.—A tuberculous cavity in the liver. The wall of the cavity is composed of dense, well-developed fibrous tissue, in which are embedded several giant cells. Within this is a partially caseous zone containing the remains of a bile-duct. In the centre is a mass of dark-brown, bile-stained, granular *débris*.

FIG. 2.—To show an earlier stage in the formation of a cavity. There is a capsule of fibrous tissue enclosing a typical tubercle. The outer part of the tubercle contains several giant cells. In the central caseous portion is a partially destroyed bile-duct.

Digitized by Google

Digitized by Google

Digitized by Google

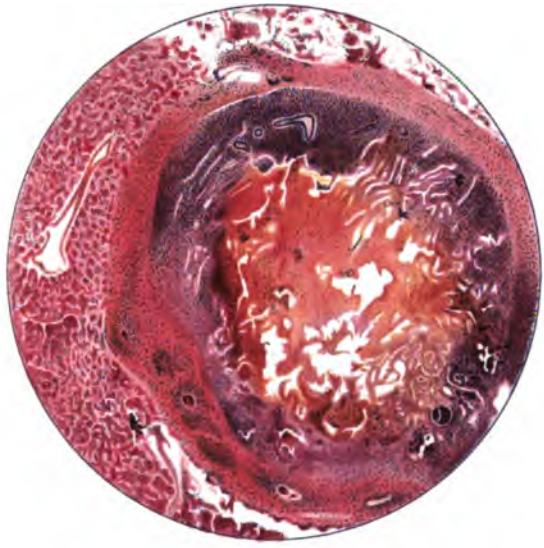

1.

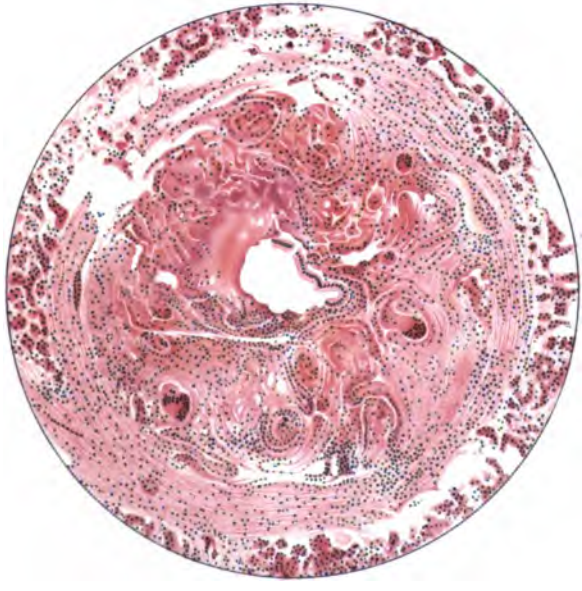

2.

Lith. Anst. v. F. A. Brockhaus, Leipzig.

Digitized by Google

Digitized by Google

capsule. Some of these, especially those under the capsule, had the ordinary grey translucent appearance. The majority of those in the liver substance were larger, and had a distinctly green tint, the green colour being chiefly confined to the centre of the tubercle.

In addition to these miliary tubercles there were numerous cavities, each about the size of a large pea. They were enclosed by a thick, white capsule, and filled with bile-stained *débris*. In some instances the contents of these cavities had a metallic lustre (? cholesterin). No communication between the cavities and the bile-ducts could be made out at the *post-mortem*. The liver tissue was congested, but showed no other naked-eye change.

Microscopical examination.—Sections showed the presence of tubercles of obviously different characters. There was a comparatively small number of quite recent miliary tubercles under the capsule and within the lobules. These presented the usual features of tubercles associated with an arterial infection, and were obviously of quite recent date. They were quite small, and showed ittle or no signs of caseation.

In addition to these there was a far greater number of larger tubercles situated in the portal canals. They exhibited very extensive caseation, and were surrounded by a thick, well-developed fibrous capsule. Many of these larger tubercles were bile-stained. In some of these in the central caseous area could be made out the remains of a bile-duct, the wall of which has been broken down. This is well shown in the drawing (fig. 2, Plate IV). The remaining epithelium of the duct can be seen partially detached. Near the periphery are numerous giant-cells, and surrounding the tubercle is a well-defined fibrous wall. This illustrates an early stage in the formation of the cavities. Later, when caseation has further advanced, the bile-duct becomes completely destroyed, and a cavity is produced filled with bile-stained *débris*. This can be seen in fig. 2.

The wall is composed of dense fibrous tissue forming a complete investment, and embedded in it are a few rather shrunken giant-cells. Within this is a narrow zone of small round-cells, in which may be seen a proliferated bile-duct. This surrounds a large cavity filled with granular dark brown *débris*.

A large number of sections from different parts of the liver were cut in order to fully investigate the changes in the bile-ducts themselves. In many places there was distinct evidence of cholangitis,

Digitized by Google

as shown by the swelling and proliferation of the epithelium, but it was found that these changes were almost invariably associated with the presence of a tubercle in the immediate vicinity of the duct. There was little, if any, evidence of a generalised or diffuse inflammation of the ducts. Sections stained to show tubercle bacilli gave a positive result.

Remarks.—As has been previously stated, very few similar cases have been described in this country.

Dr. Wethered, in 1889, showed at the Pathological Society a liver containing similar cavities with bile-stained contents, some as large as a chestnut, which was obtained from a man aged twenty-one, who died of general tuberculosis. In this case there was tuberculous peritonitis. Dr. Wethered regarded it as a case of primary tuberculosis of the liver, though I have little doubt that it was one of tuberculous cholangitis.

Dr. H. Mackenzie, in 1890, brought before this Society a case in a man aged twenty, probably of the same nature, which he described as tuberculous disease of the liver, with the formation of multiple abscesses. He regarded an old ulcer which was present in the small intestine as the probable source of infection of the liver.

Many cases of these cavities in the liver have been described by foreign authors. Cruveilhier, who was one of the first to mention them, regarded the cavities as due to simple dilatation of the ducts, and called them biliary cysts. He did not recognise their tuberculous origin. Rilliet and Barthez, Orth, Arnold, Virchow, and others described similar cases, and showed that the cavities were the results of deposition of tubercle in the liver. Rilliet and Barthez in particular compared them to cavities in the lung produced by tubercles breaking into the bronchial tubes. They also state that in seventy-six cases of tuberculosis of the liver these cavities were present in forty-six. Other cases have been recorded by Toupet, Gaucher, Quinquand, &c.

The first minute investigation into the mode of formation of these cavities was that of Sabourin in 1883, who was the first to recognise the presence of cholangitis. He maintained that the infection reached the liver by the blood, that tubercles were formed in the portal spaces, and might burst into the bile-ducts, or, as he expressed it, the ducts are infected from without inwards.

Three cases, in patients aged sixteen, seventeen, and fifty-eight years respectively, are described by Kotlar in an admirable paper.

Digitized by Google

In this he holds that the lesions are not due to a tuberculous cholangitis, but that the infection is hæmatogenous, and that the cavities are due to caseous degeneration in a caseous nodule, the bile-duct being secondarily involved.

Sergent, in 1895, confirmed these views of Sabourin's by experimental observation. He showed that inoculation of the portal vein leads to a non-systematic infection of the bile-ducts passing from without inwards. Inoculation of the common bile-duct causes a systematic tuberculosis of the biliary canals, which passes from within outwards. He further showed that the tubercle bacillus is unaffected by bile, and that the bile taken from various cases of tuberculous cholangitis contained tubercle bacilli. Somewhat similar experiments made by Gilbert and Claude show similarly that tuberculous infection of the bile-ducts can readily be produced in animals.

In short, we may roughly divide the writers on this subject into two classes: those who hold the view that the primary cause of a cavity is the formation of a tubercle in the portal space secondarily involving a bile-duct, and those who believe that the lesion is due to a biliary infection with resulting tuberculous cholangitis.

The possible channels by which tubercle bacilli may reach the liver, are the hepatic artery, the portal vein, the lymphatics, and possibly the bile-ducts. To these we must add the umbilical vein in the fœtus. The most common variety of hepatic tuberculosis is that in which, as the result of an arterial infection, bacilli are conveyed to the liver by the hepatic artery, and produce the common variety of miliary tuberculosis.

In the liver I have described, it is more than probable that some of the small, recent, non-bile-stained tubercles have been produced through this channel. This is, however, evidence, I think, that infection has been brought about through the portal vein, from the situation of the tubercle in the portal canals, and their close correspondence with those produced by experiment. This infection is probably the result of the lesions in the intestines, which were of comparatively long standing. The tubercles found in the portal canals are certainly of greater age than those occurring in the lobules and under the capsule. There is evidence in sections of the liver that some of these tubercles have brought about a destruction of the walls of the bile-duct adjacent to them, so that their caseous contents have been in free communication with the lumen of the duct. This is entirely in accord with the views of Sabourin and

Digitized by Google

Kotlar, and with the experimental work of Sergent, that in dogs inoculated by the portal vein, infection of the bile-ducts occurs from without inwards. This will account, I think, for the formation of some, at any rate, of the smaller cavities in this liver.

It is interesting to note that in many of the recorded cases of tuberculous cavities in the liver, ulceration of the intestine was present. In some of the others there was tuberculous peritonitis.

We have next to consider whether the infection may have arisen by the lymphatics. This is highly improbable, as the current of lymph in the lymphatics of the liver is towards the hilum, so that infection brought to the liver by the lymphatics is directed against an opposing flow. Such infection, if it occurs, must be of extreme rarity. Further, as Sergent showed in cases where artificial tuberculosis of the bile-ducts had been established in dogs by inoculation of the bile-ducts, and also in cases of tuberculous cholangitis in man, he invariably found an infected gland at the angle between the common duct and the pancreas,—a further evidence as to the direction of conveyance of the bacilli.

Lastly, is there evidence of infection by the bile-ducts? The larger bile-ducts are probably rarely, if ever, infected from the intestine, and in this case it is extremely improbable that this had occurred, as they were apparently quite normal. Sergent, by his experiments, showed that tubercle bacilli were unaltered by bile, and retained their virulence, and, with other writers, considered that these cavities were associated with cholangitis of tuberculous origin. In the case I have described there is no evidence of a general cholangitis, nor is there conclusive evidence of this in the cases described previously. The bile-ducts appear to be affected locally, and in the neighbourhood of a tubercle. It is noteworthy that in none of the recorded cases that I have found is the occurrence of jaundice mentioned.

In conclusion I agree with Kotlar, that the lesions are not due to tuberculous cholangitis, and that this term is a misnomer. At the same time we must recognise the possibility of cholangitis being secondarily set up by the discharge of tuberculous material into the ducts during the process of formation of the cavities. This secondary cholangitis is to be found in the liver I have examined. In places, generally near a tubercle, the epithelium of the duct may be found swollen, proliferated, and undergoing desquamation, the canals in

Digitized by Google

some places being filled with the products of degeneration. In other parts the ducts are apparently quite normal.

A considerable length of time has probably been necessary to produce the cavities of dense fibrous tissue—at least several months—as after three months Gilbert showed experimentally in dogs the cavity formation had not occurred, the animals dying before their proper development.

We may sum up the sequence of changes present in the liver as follows:—A quite recent arterial infection by the hepatic artery; an older infection through the portal vein, probably associated with the intestinal lesions, and resulting in the formation of tubercles in the portal spaces.

Next, a destruction of the walls of the bile-ducts, with formation of a cavity filled with bile-stained caseous material; and secondarily, the production of localised cholangitis.

In conclusion, I must tender my thanks to Sir Dyce Duckworth for allowing me to publish this case, and to make use of the Ward notes.

References.

Arnold.—'Virchow's Archiv,' Bd. lxxxiii, s. 377.

Cruveilhier.—'Anatomie pathologique générale,' tome iv, pp. 839—841.

Gaucher.—'Bull. Soc. anat. de Paris,' 1879, p. 545.

Gilbert et Claude.—'Compt. rend. Soc. de Biol.,' Paris, 1895, pp. 841—844.

Kotlar.—'Zeitschr. f. Heilk.,' Berlin, 1894, Bd. xv, S. 121.

Mackenzie.—'Trans. Path. Soc. Lond.,' vol. xli, p. 156.

Orth.—'Virchow's Archiv,' Bd. lxvi, p. 113.

Rilliet et Barthez.—'Maladie des Enfants,' 3rd edition, 1894, vol. iii, p. 1273.

Sabourin.—'Arch. de physiol. norm. et path.,' Paris, 1883, p. 52.

Sergent.—'Compt. rend. Soc. de Biol.,' Paris, 1895, pp. 336 and 351; 'Thèse de Paris,' 1895.

Toupet.—'Bull. Soc. anat. de Paris,' 1886, tome lxi, p. 647.

Wethered.—'Trans. Path. Soc. Lond.,' vol. xl, p. 139.

January 17th, 1899.

Digitized by Google

43. *A case of carcinoma of the liver believed to have been primary in that organ.*

By CHARLES D. GREEN, M.D., F.R.C.S.

THE specimen consists of portions of liver taken from the body of a woman who at the time of her death was 54 years old, and who died after several months' illness.

The organ is seen to be very extensively invaded by a malignant growth having its centre in the right lobe; the growth has reached the capsule on the convex surface of the liver and to a less extent on the under surface and at the free border; the central portion of the growth has undergone fibrous transformation, and is tough and dense; blood-vessels, which are still patent, can be seen in it. The disease has extended from the main growth by the development of numerous secondary nodular tumours, which can be seen surrounding it; they vary considerably in size; the more recent and outlying of them have remained discrete, but those nearer the main mass have to a great extent coalesced. In the peripheral portions of the main mass are a few small patches of congestion, and several of the secondary nodules show a white central portion bounded by a narrow vascular or hæmorrhagic zone, beyond which the growth shades off without any clear line of demarcation into the surrounding liver tissue. The liver substance in places is of a dark green colour from distension of the biliary capillaries, but this appearance was shown over only a comparatively limited area; elsewhere the liver substance between the growths was of a pale colour and relatively soft consistence, suggesting fatty change.

The glands in the portal fissure are enlarged and infiltrated by the growth, but have not coalesced; they are preserved attached to the specimen with the common bile-duct and a portion of the pancreas and of the duodenum. The bile-duct is not distended, and appears to have been only partially obstructed. The gall-bladder is contracted rather than otherwise, is not involved in adhesions, and shows no signs of new growth; there is no evident infiltration of the connective tissue of the portal fissure.

About a third of the left lobe of the liver was free from any large mass of new growth, but even here there were several small

Digitized by Google

scattered nodules. The larger portal canals appear thickened, but no such appearance is noticeable about the hepatic veins. Histologically the growth is a carcinoma showing much variety of structure in sections taken from different parts.

In the central portion of the growth fibrous transformation has taken place, and the cellular elements are few; the epithelial cells have a distinctly polygonal outline. In many places the bands of fibrous tissue can be seen to radiate from islands of dense connective tissue; these I take to be the remains of portal canals from which vessels have in many places disappeared; in some of these bands of fibrous tissue long columns of epithelial cells can be seen, in some instances unbranched for comparatively long distances, in others branching in a manner recalling the ramifications of vessels. There are in places large areæ of what appear to be degenerated liver cells; there are also seen cells with a large spheroidal nucleus and containing pigment granules. The cancer cells in the dense fibrous tissue of the central portion are smaller than those seen elsewhere, and appear to be undergoing atrophy.

In sections taken through one of the secondary discrete nodules several different appearances can be seen:

1. A central zone where considerable development of fibrous tissue has taken place, and where the active cellular elements are relatively few; columns of epithelial cells can in places be seen as above described; the liver tissue where recognisable is undergoing necrotic change.

2. A narrow zone of vascular congestion, in the vicinity of which is—

3. The more typically carcinomatous zone. This shows in places a fairly perfect alveolar structure, in others the cells are in masses without definite arrangement. The cells are for the most part definitely polygonal; they stain deeply with hæmatoxylin; in some places the cells have a trabecular arrangement. Here and there are granules of bile pigment.

4. The margin of the growth shading off without definite boundary into the surrounding liver substance, which shows much fatty change. A section taken from one of the affected lymphatic glands shows the same tendency to the trabecular arrangement of the cells and to the formation of necrotic areæ that is seen in the main growth, and the cells have the same polygonal outline.

Sections of the liver substance taken from beyond the visible

Digitized by Google

limits of the growth show much fatty change, with some increase of fibrous tissue in the portal canals, but without annular cirrhosis. The epithelium of the bile-ducts shows up very distinctly. Nearer the growth the increase of fibrous tissue in the portal canals is much more marked, and shows some admixture of epithelium.

Sections of the pancreas showed no distinct evidence of new growth.

At the autopsy no other new growths were found; there was a small patch of recent inflammatory deposit on the upper surface of the liver, and the duodenum was loosely adherent for about half an inch to its under surface. There was no ascites.

The *spleen* showed no obvious change.

The *kidneys* presented some narrowing of their cortex, and the capsules were slightly adherent. No other lesion of importance was detected in the body.

The whole length of the intestine was not slit up, and permission to make the examination having only been granted subject to the condition that the head should not be opened, the state of the brain could not be ascertained.

The examination was made under circumstances of some difficulty.

The clinical history of the case is as follows:—I had known her for some years prior to her death, but until the present year she had shown no sign of serious illness. There was no history of alcoholism.

She came to me twice in December, 1897, complaining of headache and giddiness, but I did not see her again until July 21st, 1898, when she came to me complaining of frequent and obstinate vomiting; it was then quite evident that there was considerable loss of flesh and general deterioration of health. No abnormal physical signs were detected on examination, and the urine was free from albumen and from sugar. It seemed probable that she was suffering from malignant disease of stomach.

The vomiting was not persistent, but occurred in paroxysms at varying intervals, and was generally accompanied by headache and giddiness; there was no optic neuritis, no paralysis, nor any direct evidence of cerebral mischief. Constipation was a prominent symptom throughout.

She continued to get weaker, but no definite diagnostic indication of the seat of disease occurred until early in September, when she

Digitized by Google

began to complain of pain localised in the right side and aggravated by deep inspiration. A friction sound could soon afterwards be heard at the right base, which persisted for about ten days and could then be no longer heard; the pain, however, did not abate. There was also about this time some epigastric tenderness.

During the last week in October an ill-defined swelling could be felt, apparently connected with the liver, just below the ribs, a little to the right of the middle line, and this persisted and seemed to increase in size, but no definite limits could be assigned to it.

There was never any evidence of ascites, but the abdomen was somewhat distended during the last few days of life, owing to gaseous accumulation in the bowels; there was slight jaundice noticed for fourteen days before death.

Death took place on November 26th from very slowly progressive nutritional failure.

The only noteworthy feature found at the autopsy besides the conditions described in connection with the specimen was that there was no trace of recent pleurisy; the pain and friction must therefore have been due to the growth reaching the capsule of the liver on its convex surface.

We have here a growth which has destroyed the greater part of a large and important organ, but beyond infiltrating a few lymphatic glands in its immediate vicinity has given rise to no secondary deposits. It has thus shown great local malignancy and but little tendency to dissemination. The central portions have undergone fibrous transformation and atrophy, perhaps similar to what occurs in atrophic scirrhus of the breast, and this tendency is exhibited not only by the main growth but also by the outlying nodules; the clinical history and the *post-mortem* appearances both point to a slowly growing tumour.

I think the absence of calculi, the apparently normal condition of the gall-bladder, and the absence of columnar epithelium in the lymphatic glands, together with the late appearance of jaundice, are facts pointing against the disease having originated in the gall-bladder or in the main bile-ducts; there is, it is true, some approach to the short columnar type in some of the cells in certain places in the growths in the liver, but this may well be due to irritation of the bile-ducts by the development of the disease and their secondary participation therein; besides, polymorphism is not unknown in carcinomatous growths.

Digitized by Google

The total absence of ascites and the fact that there was no enlargement of the spleen practically negative the hypothesis of cancer following upon cirrhosis, and the appearance of the sections of liver taken from well beyond the visible limits of the growth showing but little development of fibrous tissue is also against this view. I therefore think that in this case the growth originated in a morbid activity, beginning in the liver cells themselves.

MM. Hanot and Gilbert, in writing of primary carcinoma of liver in their work on diseases of that organ, remark: "C'est la cellule hépatique, c'est à dire l'élément noble du foie, qui fait tous les frais de la métamorphose; les autres éléments ou bien disparaissent par atrophie, ou bien concourrent seulement à la formation du stroma."

Dr. Rolleston, in his paper on malignant disease of the gall-bladder and bile-ducts, published in the 'Clinical Journal' of April, 1897, says that carcinoma beginning in the bile-ducts is almost always columnar-celled, and mentions progressive jaundice usually lasting about six months as one of the symptoms.

In a case of my own, which was probably primary in the gall-bladder, there was a large carcinoma involving the liver, the colon, and the stomach, and which was associated with a single large calculus. The secondary nodules in the liver showed groups of epithelial cells, the peripheral layer of which was distinctly columnar, and the central layers were spheroidal and flattened, with, in places, tendency to the formation of nests so commonly seen in surface epitheliomata.

Hanot and Gilbert, in the work above quoted, speaking of the affection of the interstitial tissue in cases of primary cancer of the liver, say: "Le tissu interstitiel est le siège de lésions inflammatoires étendues à la totalité du foie. Dans le cancer trabeculaire l'on constate presque toujours l'existence d'une cirrhose véritable. Celle-ci parfois insulaire presque toujours annulaire se fait remarquer fréquemment par le grand nombre de canalicules biliaires disseminés ou agminés en plaques qui criblent ses jetées ou ses anneaux."

January 3rd, 1899.

Digitized by Google

44. *Atrophied pancreas from case of diabetes mellitus.* (*Card specimen.*)

By T. W. P. Lawrence.

The pancreas retains the normal shape and exhibits slight signs of lobulation; but it is greatly reduced in size, measuring five inches in length, five eighths of an inch in width, and one quarter of an inch in thickness. Its weight is 4 drachms 15 grains. The specimen was presented to the Museum of University College by Dr. Henry J. Price, of Maldon, Essex, and was taken from a single woman aged 32, who was suffering from diabetes mellitus and who had been under treatment for six months before her death. The daily excretion of urine varied between three and five pints. The normal acini of the gland are not recognisable under the microscope, and their place is taken by masses of granular material in which nuclei are visible in places. There is considerable increase of the fibrous tissue of the gland, and the vessels exhibit marked fibroid degeneration. *April 4th*, 1899.

---

45. *Primary columnar-celled carcinoma of the tail of the pancreas.* (*Card specimen.*)

By H. D. Rolleston, M.D.

Clinical Abstract.—A woman aged 49 years was admitted with great pain in the back and abdomen. She was thin and distinctly pigmented, but no trace of jaundice was ever present. There was no glycosuria. A projection was felt in the back to the left of the spine at the level of the ninth dorsal vertebra; nothing could be felt in the abdomen. After she had been in a week she had an epileptic fit, and a week later her mind became deranged and she refused to speak. Two days later small tumours were felt under the skin of the right thigh over Hunter's canal and on the

Digitized by Google

perinæum. Five days later she died. The diagnosis was primary malignant disease of the spine.

Post-mortem examination showed a primary growth on the tail of the pancreas close to the spleen. The growth was white in colour, fairly firm in consistence, and had begun to eat its way into the capsule of the left kidney. Several of the branches of the splenic artery were compressed and obstructed by the growth. The splenic vein was thrombosed, and the thrombus extended into the portal vein. The spleen contained a number of recent anæmic infarcts. Microscopic examination showed the absence of any trace of growth in the infarcted areas. The adrenal bodies were free from growth. The œsophagus, stomach, and intestines were normal. There was no fat necrosis. There were secondary growths in the pleuræ, in the liver, in the muscles of the back opposite the ninth dorsal vertebra, and in the subcutaneous tissue of the right thigh and perinæum. There was an old clot in the aorta near its bifurcation, and in the left common iliac artery. There was also an adherent thrombus on the left ventricle, and some vegetations on the mitral valve. There were pulmonary apoplexies in both lungs, and a cerebral hæmorrhage into the right external capsule.

Microscopically.—The growth was a columnar carcinoma. The structure was well seen in the secondary growths, in the liver and in the muscles of the back. In places there was a transition to a spheroidal-celled carcinoma.

Remarks.—The following points are of interest:

(1) Situation of the growth. While the tail of the pancreas is said to be the commonest part of the gland for secondary growths (Vernay), it is a rare one for a primary neoplasm. Mirallie, in his digest of 113 undoubted cases of primary carcinoma of the pancreas, only refers to one instance (Laennec's) of the disease arising on the tail. Norman Moore in his collection of cases says that the duodenal end was always the part affected. Lancereaux, however, says that in fifteen cases observed by him, the tail was affected in two. Ebstein has recently reported a case of latent carcinoma of the tail of the pancreas. A case recorded by myself in the 'Transactions' of this Society (vol. xliv, p. 320), of carcinoma of the tail of the pancreas with a secondary growth in the anterior mediastinum, is open to the objection which I now share, that the growth was primary in the thymus gland or its remains, and that the pancreatic growth was secondary.

Digitized by Google

(2) The nature of the growth. Carcinoma of the pancreas is nearly always spheroidal-celled. Bard and Pic described columnar-celled carcinoma, and pointed out that it was derived from the epithelium of the ducts of the gland, carcinoma of the "excretory type" as they called it, or as it would be now termed duct cancer. Kühn recorded a most exceptional case of this histological form of pancreatic carcinoma in a girl aged two years. Cases have also been recorded by R. Pott and by E. Wagner, but Cornil and Ranvier consider that the growth in the latter case spread to the pancreas from the duodenum. Mr. Beadles described a case of columnar-celled carcinoma in the earlier part of this session (p. 174).

(3) The coincidence of an exceptional position for carcinoma of the pancreas with an exceptional form of growth. The pancreatic duct is so comparatively small at the tail end that the occurrence of a duct carcinoma there is remarkable.

(4) The invasion of the branches of splenic artery by the growth and the resulting obliteration, which was accompanied by anæmic infarcts in the spleen and thrombosis of the splenic vein.

(5) The general tendency to thrombosis, as shown by the thrombosis in the aorta, the left common iliac artery, and the left ventricle.

(6) The fairly wide-spread generalisation of the growths.

(7) The latency of the primary growth, the secondary growth in the muscles of the back appearing during life to be the primary.

Vernay.—'Thèse de doctorat,' 1884, Lyon (quoted by Mirallie).
Mirallie.—'Gaz. des hôp.,' Paris, 1893, Aug. 19th, p. 889.
Laennec.—'Gaz. méd. de Nantes,' 1892 (quoted by Mirallie).
N. Moore.—'St. Bart.'s Hosp. Rep.,' vol. xviii, p. 205.
Lancereaux.—'Traité des Maladies du foie et du pancréas,' p. 844, 1899.
W. Ebstein.—'Deutsche med. Wochenschrift,' Feb. 2nd, 1899, No. 5, S. 71.
Bard and Pic.—'Rev. de Méd.,' 1888.
Kühn.—'Berlin klin. Wochenschrift,' 1887, No. 27.
R. Pott.—'Deutsche Zeitschrift f. prakt. Med.,' 1878, Bd. v, S. 181.
E. Wagner.—'Archiv d. Heilkunde,' 1861, Bd. ii, S. 285.
Cornil and Ranvier.—'Manuel d'histologie pathologique,' vol. ii, p. 490.

May 16th, 1899.

Digitized by Google

46. *Lesion of the pancreas with fat necrosis.* (*Card specimen.*)

By Cecil F. Beadles.

In this specimen necrosis of the peritoneal fat is associated, as is commonly the case, with disease of the pancreatic gland; but the latter lesion is of an unusual character, and is itself of considerable interest, for in addition to a general fibrosis of the organ there is a localised mass of malignant growth situated in its right extremity, having the microscopical features of columnar-celled carcinoma, so that it has doubtless taken origin from the wall of the pancreatic duct.

The patient was a female lunatic aged 62, who had been insane for a period of over sixteen years. Her mental state at first was that of melancholia, with well-marked aural hallucinations and delusions of electricity; she passed, however, into a state of chronic mania with periodical outbursts of excitement and violence; was of an impulsive and threatening nature. Her delusions persisted, and she finally became more demented.

Three months before death she began to get jaundiced. This increased, and she had a vague pain in the epigastric region, which she was unable to exactly localise. Although no abdominal tumour could be detected, it was believed she was suffering from malignant disease. Slow and gradually increasing weakness set in, and she remained confined to bed. During the last week or two she had a sense of nausea, but no vomiting. There was no diarrhœa, and she passed no blood either by the mouth or rectum. Bowels acted fairly regularly, but the motions were pale in colour. She is not known to have met with any injury.

At death the body was well nourished, the skin jaundiced, and all the internal organs deeply bile-stained. Fat on the abdominal parietes was two to three inches thick, and appeared of a natural character. A considerable excess of fluid existed in the pericardial cavity. The cardiac valves were fairly healthy, but the right ventricular wall was much thinned and replaced by fatty tissue. Bases of both lungs congested. Excess of fluid within the skull. The brain softened, choroids deeply bile-stained, but finer membranes and blood-vessels healthy. Stomach and intestines natural;

Digitized by Google

spleen slightly enlarged and soft; pelvic organs healthy; both kidneys a little enlarged. The liver was large and bile-stained; weighed 56 oz. The biliary ducts throughout were greatly dilated, and filled with glairy fluid. The gall-bladder contained a dozen small calculi and some bile somewhat altered in character.

The specimen consists of the pancreas, duodenum, left kidney, and its surrounding perinephritic fat. This fat differs from that elsewhere in the fact that it is of a denser character than natural, being pervaded by thick bands of fibrous tissue, which under the microscope are seen to be composed of a young and loose form of connective tissue. Scattered about this fat are extensive areas of necrosis; they are of an opaque white colour, in parts bile-stained, resembling to the naked-eye areas of caseation. This adipose tissue formed a thick investing capsule around the left kidney and readily shelled out with it, whereas the fat on the right side was natural in appearance and not in excessive amount. The right kidney lay free.

The true capsule of the left kidney is thickened. That organ is a little enlarged, its cut surface soft and deeply bile stained, its surface granular. There are several small cysts in the cortical portion, and these contain dark clotted blood. The pelvis is filled with fat. Microscopically the condition of the organ is best described by the term "mixed kidney," meaning thereby a certain amount of fatty degeneration of the renal epithelium with an increase of the interstitial connective tissue; there is hæmorrhage into this in places. Section through one of the cysts shows a thick fibrous wall with deposits of old blood pigment in it.

In the fresh state the pancreas presented an unnatural degree of hardness throughout. The organ is unduly adherent to the surrounding fat, and is intimately blended to the wall of the small intestine, more particularly the lower and inner part of its head to the third portion of the duodenum. Section through the length of the gland reveals a hard fibrous nature, with considerable dilatation of the duct; this latter was filled with a nearly colourless sticky fluid, so that there was clearly an obstruction to the outflow of the glandular secretion. A small area of the gland, less than an inch in diameter, where its attachment to the duodenum was most marked, is of a firmer and denser structure, and the cut surface of this closely resembles that of a scirrhous growth.

The histological character of this tissue is that of typical carcinoma of the columnar-celled variety, that is to say, alveolar spaces

Digitized by Google

lined by cubical or columnar-shaped cells, either arranged in a single row or massed together more irregularly. This malignant growth appears to be strictly limited in extent to the small area above mentioned, and does not exist elsewhere in the gland. But sections taken from various other parts of the organ reveal changes of an abnormal character but which are not of a malignant nature.

There is throughout the pancreas a condition of fibrosis. An overgrowth of fibrous connective tissue, varying in places between fully-formed fibrous bundles which encircle the lobules, and wide bands of young connective-tissue formation. Within these latter there are frequently collections of small, round, inflammatory cells, which present the appearance of miniature abscesses. The proper secretory cells of the gland are for the most part largely degenerated, either by a process of self-digestion or have passed into a state of necrosis. In unstained sections the former are still translucent, but the latter appear as small opaque areas: the frequency of these two conditions varies in different parts of the gland.

The malignant growth in this organ, owing to the absence of any other growth in the body, clearly proves it a primary carcinoma of the pancreas, and its situation and minute structure suggest that it took its origin from the duct of the gland. Further, the exceedingly limited extent of this malignant deposit, presenting at the same time active growth and a rapidly extending margin associated with a chronic inflammatory change throughout the entire gland, suggests to my mind that the simple chronic changes existed primarily, and that malignancy has supervened at a comparatively late date, possibly as a result of obstruction to the outflow of the secretion or an alteration in the composition of the pancreatic juice. In cancer of the pancreas it is not usual to find a general fibrosis of the organ as a part of the malignant process.

From the point of view of the fat necrosis, the combination with cancer of the pancreas is interesting. This singular lesion of the peritonitic fat still requires much light thrown on its ætiology. So far, cases appear to have been mostly associated with hæmorrhage or inflammation involving in some way the pancreatic gland, but the true connection between the two lesions has yet to be explained. Two recorded cases of this lesion with pancreatic carcinoma are those of Newton Pitt[1] and Mayer;[2] the former was a large

[1] 'Path. Trans.,' 1894.

[2] 'Wien. med. Presse,' No. 1, 1899 (epitome, 'Brit. Med. Jn.,' 1899, vol. i, p. 46).

Digitized by Google

carcinomatous growth, the latter "fibrous carcinoma" of the pancreas.

But apart from all other considerations, the present specimen is of interest from the early state of the cancer and the fact that it is a columnar or duct variety.

Brief notes of a second case of peritoneal fat necrosis may be worthy of record, as there are points of interest apart from the fact that this is the only other instance of the lesion found amongst the insane dying in Colney Hatch Asylum since the case recorded by myself in the 'Pathological Transactions' for 1893.

A man aged 63 died in July, 1898, from heart disease, having been the subject of chronic mania for 8½ years. There was much superficial fat and a great accumulation of adipose tissue in the omentum and folds of the mesentery. Scattered about that of the omentum were areas of necrosis. The walls of the stomach were thickened, intensely congested within, and adherent externally to the spleen, which was hypertrophied and weighed 15 oz. Between these organs, and in contact with the pancreas, was an abscess cavity containing 2 oz. of grumous fluid. Both kidneys were much enlarged, each weighing over 9 oz., fatty and congested; the left contained an abscess on its cortical surface, closely connected with the perinephritic fat. The liver was of great size, weighed 71 oz., was very fatty and congested, the gall-bladder was distended with numerous faceted calculi, sixty-six in number, and in the aggregate weighing 106 grains. These were of about equal size, yellow colour, and composed largely of cholesterin. The majority presented an appearance that is usually attributed to spontaneous fracture during life; one side of the stone exhibits the internal structure, but the surface is smooth and glistening, and the edges are worn and rounded off.

The man had always been exceedingly stout, and for some time had suffered from a large fatty heart, with valvular incompetence. In 1895 he had an attack of gout. A month before he died he had hepatic colic with jaundice. There was already albumen in his urine. Bronchitis set in and general anasarca followed.

January 17th, 1899.

Digitized by Google

47. *Sarcoma of pancreas; glycosuria.* (*Card specimen.*)

By T. CHURTON, M.D.

R. B—, a coal miner aged 54, height 5 feet 5 inches, weight 8 st. 4 lbs., formerly 10 st. 2 lbs., was admitted into the Leeds Infirmary on March 12th, 1898, for pain in left side of chest or upper part of abdomen. Muscles and adipose tissue wasted. There were no teeth in the upper jaw; no complaint of dyspepsia; recent constipation. Urine 38 ounces daily; sp. gr. 1035, sugar, no albumen. Radials rather thick. Slight pain in left elbow; occasional tingling in right little finger. His mother died young. At twenty-seven he had sciatica for five months; at forty-nine, influenza; never quite so well since, but was at work and not ill until March 10th, 1898; on this day he had chills followed by slight cough and dyspnœa.

March 26th.—Diabetic diet ordered, in aid of diagnosis.

April 1st.—Diarrhœa; urine 29 ounces, sugar 350 grains, no albumen.

2nd.—Diarrhœa checked by opium and catechu. Temperature began to rise. Diabetic diet stopped.

4th.—Temperature 105·5° at midnight; urine in previous twenty-four hours 43 ounces.

5th.—Patient died.

Post-mortem.—The pancreas was not markedly enlarged, but when incised its structure appeared almost homogeneous, whitish, and not showing the familiar finely lobulated or fissured section-surface. Microscopically, the connective tissue was infiltrated with small round-cell sarcoma; the lobules were also invaded, and in some of them the normal epithelium was replaced by sarcoma cells; here and there some of these cells had fallen out, leaving small cavities whose walls were formed by the growth. In the liver there were many spherical and (near the surface) hemispherical growths. Simple adhesions had been formed between the pancreas, left kidney, and spleen. *November 1st*, 1898.

Digitized by Google

V. DISEASES, ETC., OF THE GENITO-URINARY ORGANS.

1. *Contracted kidney with multiple adenomata.* (*Card specimen.*)

By F. Parkes Weber, M.D.

The kidney is small, hard, and typically "cirrhotic," weighing only about 1½ ounces. When first removed from the body it was red, and contained a number of small yellowish-white nodules scattered over the outer part of the cortex beneath the capsule. These little tumours were of rather soft consistence, somewhat resembling tuberculous nodules in process of caseation. Microscopical examination shows them to be multiple papillary adenomata, such as Charles Sabourin[1] described in connection with granular kidneys. The structure is that of a cyst filled with delicate branching papillary growths, the walls of the cyst and the papillary processes being covered with a more or less cubical epithelium. No concentrically marked bodies, such as are termed "corpora amylacea" (or, when hard and gritty, "microscopic calculi") were found in this case, though their presence has sometimes been noted in or about similar small renal adenomata in other cases.[2]

The present kidney (the right kidney) is from a man aged 57, who had a large aneurysm of the transverse part of the arch of the aorta pressing on the trachea.

It may be remarked that no adenomata were observed in the man's other kidney (the left one) which was much the largest and healthiest of the two. As Sabourin[3] has pointed out, there seems

[1] "Sur quelques cas de cirrhose rénale avec adénomes multiples," 'Revue de médecine,' Paris, 1884, p. 441.

[2] Sabourin, loc. cit., p. 446; F. Parkes Weber, 'Trans. Path. Soc. Lond.,' vol. xlix, p. 177.

[3] Sabourin, loc. cit.

Digitized by Google

to be a special connection between these multiple tumours and chronic renal fibrosis; this connection is of great interest in the question of the general influence of chronic irritation (or chronic inflammation) on the development of tumours. Kelynack[1] thinks that the adenomata described by Sabourin and Oetlinger, in connection with interstitial nephritis, are probably more "of the nature of a glandular proliferation than true growths."[2] The occurrence, however, of these little tumours in contracted kidneys reminds me of the multiple cutaneous tumours sometimes produced by chronic irritation or inflammation of the skin (such as by the chronic action of some external irritant, as in some trades, or by the prolonged internal use of arsenic). Papillary adenomata of contracted kidneys probably sometimes develop in connection with the little cysts,[3] whose presence constitutes a frequent characteristic of chronic interstitial nephritis. According to my view, such tumours may be regarded as analogous to multiple warty growths developing on a chronically irritated skin, or to multiple excrescences of the mucous membrane occurring in some cases of balanitis, &c. It seems, indeed, as if in certain kidneys, as in certain skins and mucous membranes, chronic irritation may lead to the formation of multiple warty growths, though in many individuals similar irritation does not induce a similar development of tumours.

January 3rd, 1899.

[1] T. N. Kelynack, 'Renal Growths,' Edinburgh and London, 1898, p. 115.

[2] In this connection R. Marie's observation is very interesting. This experimenter ('Proceedings of the Anatomical Society of Paris,' January 27th, 1899), in the case of twenty-five dogs, grafted a fragment of renal cortex below the capsule of the kidney. In two of these cases a small tumour developed from the graft, having somewhat the appearance of an alveolar renal adenoma. The growth was destitute of glomeruli, and consisted of acini without any central lumen.

[3] Papillary adenomata of the kidney easily undergo degenerative changes. It is probable that their growth and subsequent degeneration give rise to the formation of small cysts in the renal cortex filled with a pultaceous *débris*. In the contents of this kind of cyst I have several times recognised the presence of minute concentrically marked spherules ("corpora amylacea" or "microscopic calculi"), such as are also seen in sections of renal adenomata.

Digitized by Google

2. *Small true lipoma of kidney. (Card specimen.)*

By F. Parkes Weber, M.D.

The little tumour, of the size of a millet seed, is situated in the renal cortex close to the capsule. It is made up of ordinary fat cells of various sizes closely packed together, mostly without any fibrous tissue intervening. Here and there, however, especially around one or two relatively large blood-vessels, are collections of fibroid cells, some of which contain small fat globules. These cells are, doubtless, those from which the ordinary fat cells of the tumour are formed. There is no distinct capsule, and the little tumour has therefore a slightly irregular margin. A study of the microscopic sections in the present case makes it probable that the tumour has originated from a focal multiplication of peri-vascular and intertubular fibroid cells, which, after multiplication, undergo fatty metamorphosis, and produce atrophy of the glandular cells they press on.

Virchow[1] speaks of fatty nodules sometimes found in the renal cortex, which may attain the size of a cherry. He mentions these as examples of heteroplastic lipomata, there being no true fatty tissue normally present in the kidney substance.

Dr. T. N. Kelynack[2] says, "True lipomata are extremely rare. Small aggregations of fat, however, are sometimes found in a subcapsular position." Though some of the so-called lipomata alluded to by Robin and Virchow have, as Kelynack states, been shown by P. Grawitz[3] and others to be small adenomata, arising from aberrant adrenal tissue; the occasional occurrence in the kidney of small genuine lipomata has been admitted by Grawitz himself (in 1884),[4] Rudolf Beneke,[5] and others.[6] Virchow[7] had

[1] 'Die krankhaften Geschwülste,' Berlin, 1863, vol. i, p. 385.

[2] 'Renal Growths,' Edinburgh and London, 1898, p. 62.

[3] "Die sogenannten Lipome der Niere," 'Virchow's Arch.,' 1883, vol. xciii, p 39.

[4] Referred to by Alsberg, 'Arch. f. klin. Chirurgie,' Berlin, 1892, vol. xliv, p. 461.

[5] 'Ziegler's Beiträge zur path. Anata' Jena, 1891, vol. ix, p. 475.

[6] Referred to by Alsberg, loc. cit.

[7] Referred to by Warthin, 'Journal of Pathology,' 1897, vol. iv, p. 410.

Digitized by Google

himself seen but one renal lipoma, which he explained as originating from a fibroma, the connective-tissue cells of the tumour becoming transformed into fat cells.

Dr. A. Alsberg[1] some years ago removed an enlarged right kidney from a woman aged 40, supposing it to be the site of malignant disease. The kidney was found to contain a large number of encapsuled lipomata or fibro-lipomata, varying from the size of a millet seed to that of a walnut. They were tolerably uniformly scattered through the substance of the kidney, some below the capsule, some near the hilum. Some of the tumours were pure lipomata, some contained a good deal of connective tissue. In the very vascular young fibroid tissue found near the lipomatous nodules the microscope revealed the presence of scattered fat cells, and in some parts there were so many fat cells seen, that it seemed as if the fibroid tissue was becoming transformed into fatty tissue.

A large single genuine fibro-lipoma, growing from the left kidney of a woman aged 31, has quite recently been described by Dr. A. S. Warthin.[2] It weighed two pounds, and was successfully removed during life, being perhaps the only instance, excepting Alsberg's case, of surgical interference being required on account of renal lipomata.

The renal lipoma in the present case was from a man aged 70, with granular kidneys, who died in an apoplectiform condition at the German Hospital. At the necropsy some minute nodules and small whitish spots were seen in the renal cortex below the capsule. The small lipoma was one of them. Another of them was apparently merely a minute cyst with inspissated contents.[3] From naked-eye examination I supposed the kidneys contained multiple papillary adenomata, which not very rarely develop in cases of chronic interstitial nephritis, and the present case serves to illustrate the fact that various minute tumours (fibromata, lipomata) of the renal cortex may easily be set down as adenomata if no microscopic examination be made.

[1] "Ueber einen Fall von Lipom der Niere," 'Arch. f. klin. Chirurgie,' Berlin, 1892, vol. xliv, p. 458.

[2] "Fibro-lipoma of the Kidney," 'Journal of Pathology,' Edinburgh and London, 1897, vol. iv, p. 404.

[3] For the microscopic sections I have to thank Dr. Krieg, one of the resident medical officers at the German Hospital.

Digitized by Google

The present case shows, I think, how genuine ("heteroplastic") lipomata may develop in the kidney substance by the multiplication of fibrous or young connective-tissue cells (probably chiefly those connected with the outer walls of blood-vessels), and the subsequent metamorphosis of these newly-formed cells into ordinary fat cells. The present case therefore confirms the views of Virchow, Beneke, Alsberg, and Warthin as to the origin of renal lipomata by the fatty transformation of proliferating fibroblastic cells, or of older connective-tissue cells. *March 21st*, 1899.

---

3. *An undescended left testicle.*

By Arthur Voelcker, M.D.

The left testicle is seen lying in the peritoneal cavity and adherent to the posterior layer of the parietal peritoneum. The right testicle occupied its normal position.

From a man aged 32, who had spina bifida and talipes equino-varus, and had never walked. He developed an epitheliomatous new growth either at the anus or at the seat of a perinæal sinus.

December 7th, 1898.

---

4. *Prostatic myomata and vesical calculus removed from the same patient.* (*Card specimen.*)

By T. Carwardine, M.S.

The patient was a melancholic individual, 64 years of age, who had suffered from retention and from profuse hæmaturia with but little pain. The vesical sound, passed to the hilt, detected a rough calculus in the right retro-prostatic pouch. Supra-pubic cystotomy was performed and an oxalate and phosphate calculus removed. A large soft prostate was felt to project into and occupy almost the

Digitized by Google

whole of the contracted bladder, and corresponding to it in form. A week afterwards, before the wound had closed, the prostate was incised and several spheroidal masses enucleated with the finger. They were about eight in number, varying from the size of a pigeon's egg to that of a hazel nut, and after their removal there appeared to be a direct channel from the bladder into the urethra. The patient got up three weeks afterwards, but eventually uræmia supervened. At the autopsy the ureters were found enormously dilated and the kidneys hydronephrotic.

January 17*th*, 1899.

Digitized by Google

Digitized by Google

DESCRIPTION OF PLATES V AND VI.

PLATE V,

Illustrating Mr. S. G. Shattock's paper upon an Acromegalic Skull and that of a normal giant. (Page 185.)

FIG. 1.—A front view of the skull of the normal giant described, showing the absence of increase in the height of the superior maxillæ, so notable in the acromegalic skull.

FIG. 2.—A lateral view of the same skull.

(Photographed by permission of the Council of the Royal College of Surgeons.)

PLATE VI,

FIG. 1.—A front view of the skull described, showing its massive character, the notable increase in height of the upper jaw and width of the lower jaw between the angles.

FIG. 2.—A lateral view of the same skull, showing the elongation of the lower jaw, leading to notable prominence of the chin, and the increased height of the ramus.

(Photographed by permission of the Council of the Royal College of Surgeons.)

Digitized by Google

Digitized by Google

Fig. 1.

Fig. 2.

Digitized by Google

Fig 1.

Fig 2.

Digitized by Google

Fig. 1.

Fig. 2.

Digitized by Google

Fig. 1.

Fig. 2.

Digitized by Google

Digitized by Google

VI. DISEASES, ETC., OF BONE AND OF THE ORGANS OF LOCOMOTION.

1. *An acromegalic skull and that of a normal giant.*

By Samuel G. Shattock.

[With Plates V and VI.]

The first of these two skulls is from the collection of modern Italian crania, purchased by the Royal College of Surgeons in 1870 from Dr. Giustiniano Nicolucci. Though placed by Sir William Flower amongst the normal European crania, it was noted, at the time when catalogued, as "of great size, massive and rugged." There is no difficulty in recognising it now as one of the acromegalic type. I have thus described it in the Pathological Catalogue, to which part of the collection the specimen has been recently transferred.

The skull is unusually massive in consequence of a diffuse thickening which involves the frontal, the parietal, and all the bones and portions of bones entering into the formation of the roof and sides of the cranial cavity; below the level of the superior curved line, however, the occipital bone is not thicker than natural. Similar changes are recognisable in the malar bones, the zygomatic processes of the temporals, the palatine processes, and adjoining parts of the superior maxillæ. The thickened bones are dense, and for the most part unnaturally porous and slightly roughened, the surface changes being less marked over the area corresponding with the origin of the temporal muscle. The pituitary fossa is considerably enlarged, indicating the existence of a pituitary goitre. The posterior part of the interparietal suture is obliterated. None of the foramina at the base are diminished in size. The lower jaw is markedly enlarged, but without such thickening as could be called massive. The length of the vertical ramus is increased, the

Digitized by Google

chin pointed and unusually prominent. The general enlargement is evident, however, in the divergence of the posterior margins of the vertical rami, and in the increase in the lower dental arch, which everywhere exceeds the upper. Although the circumference of the skull is 570 cm., its capacity is but 1500 c.c.

The parietal bones, where thickest, viz. in the neighbourhood of the interparietal suture, measure 2 cm. ($\frac{4}{5}$ inch), and in section they are closely cancellous or compact, without distinction of tables and diploe. The vascular grooves on the inner surface of the skull are deepened, showing that the bone has been thickened from within as well as from without.

The texture on section is indistinguishable from that of a calvaria thickened and sclerosed in the later stages of osteitis deformans.

Although Marie's differentiation of acromegaly is so comparatively recent as 1886, examples of the condition itself have been put on record at earlier periods; the history of the disease, in this respect, running somewhat parallel with that of osteitis deformans, which had been nine years previously differentiated by Sir James Paget.

The earliest apparent example of acromegaly recorded in this country is to be found in the Society's 'Transactions,' vol. viii, 1857, under the title of "Partial Dislocation of the Lower Jaw from an Enlarged Tongue," by Mr. W. O. Chalk. This has been referred to by various writers upon acromegaly.

In this case the projection of the lower jaw was very conspicuous, and amongst the details in the long but diffuse history given, it is stated that at the age of thirty the surface of the body became greatly swollen, the swelling, however, being eventually confined chiefly to the hands and face; it was at this period that the tongue began to enlarge, and in twelve months afterwards an altered condition of the lower jaw was first observed. The ultimate history of the case is unknown. The enlargement of the jaw serves here to differentiate the condition from that of myxœdema, where the tongue may equally be enlarged.

In 1879 Professor D. J. Cunningham, ('Journal of Anatomy and Physiology,' vol. ix) described an example of "A large Sub-arachnoid Cyst" from a man suffering from diabetes mellitus; "a man of huge frame, with an unpleasing expression and overhanging brows; his hands and feet were enormously large and flat, and his movements clumsy and ungainly." The enlargement of the pituitary body and of the pituitary fossa was noticed by Professor

Digitized by Google

Cunningham, who compared the case with that recorded by Henrot in 1877 ('Union Médicale et Scientifique du Nord-Est').

The skeleton of this subject was afterwards described with great detail by Dr. Alexis Thomson as one of acromegaly ('Journal of Anatomy,' vol. xxiv, p. 483). Of the cranial bones in this instance, Dr. Thomson remarks that, as seen in the section by which the calvaria was removed (at the level of the summit of the frontal sinuses), they show alterations which are of the nature of an hypertrophy of their normal structure, viz. an external and an internal plate of compact bone with intervening diploe, increased in thickness and in density. "Herein," he proceeds, "lies the difference between the hypertrophied bone of acromegaly and the diseased bone of osteitis deformans; for in the latter the outer table becomes porous and spongy as a result of inflammatory changes, and the normal distinction between the outer and inner tables and diploe is lost." This generalisation the specimen under consideration shows to be untenable.

In the case, moreover, recorded by Mr. Percy Furnivall in the Society's 'Transactions' of last year (p. 207), the skull-cap was "thick, dense, and heavy . . . . there is no distinction between the compact and cancellous tissue of the bones forming the skull-cap." We cannot, therefore, name these changes hypertrophic in the strict or academic sense. They are not such as are seen in the form of thickening which is adduced by Sir James Paget as typical of true osseous hypertrophy,[1] and as arising in connection with atrophy and shrinkage of the brain. I have myself seen one instance in which such true hypertrophy was limited to one side of the calvaria, the change being associated with general atrophy of the corresponding cerebral hemisphere. Portions of the calvaria from this case are preserved in the museums of University College and St. Thomas's Hospitals (No. 342). The subject was a man who had suffered when young from epilepsy, and who became afterwards a criminal lunatic.

There is an admirable figure of precisely the same one-sided hypertrophy of calvaria associated with hemiatrophy of the cerebrum in Cruveilhier's 'Anatomie Pathologique,' planche v, viii^e^ livraison. There was in this case excess of fluid beneath the arachnoid, combined with internal hydrocephalus on the atrophied side. The author remarks that the fluid in both positions appeared

[1] 'Surgical Pathology,' 3rd edit., p. 60.

Digitized by Google

to be a result and not the cause of the atrophy, and asks whether the calvarial thickening was not likewise a result, observing that this could not be the cause, since the cerebral atrophy was not proportionate to but exceeded it.

Cruveilhier appears to have been the first to point out the sequence between the two events, Dr. Sims's paper upon this subject having been published in the nineteenth volume of the 'Transactions' of the Royal Medical and Chirurgical Society, May 26th and June 9th, 1835, at which date the particular part of the 'Anatomie Pathologique' relating to this subject was already extant.

One of Dr. Sims's conclusions is that "in cases of atrophy of the brain the place previously occupied by cerebral substance is supplied by serous fluid or by deposition of bone, and this deposit of bone frequently takes place on the inner surface of the cranium."

Another example is that in Van der Kolk's "Case of Atrophy of the Left Hemisphere of the Brain with co-existent Atrophy of the Right Side of the Body" (The New Sydenham Society's translation by W. D. Moore, 1861, vol. ii). This writer also observes that in unilateral atrophy of the brain there may be either an associated corresponding hypertrophy of the calvaria, or that the atrophied side may be filled with serum without the bone being thickened.

Sir George Humphry has discussed the explanation of such osseous overgrowth with his peculiar skill in a paper in the 'Medico-Chirurgical Transactions,' vol. lxxiii, p. 327. Both the serous effusion into the meshes of the pia mater and the thickening of the skull attending shrinkage of the brain, proceed, he remarks, from a dilatation of vessels consequent upon the diminished volume of the cranial contents, and a slowing of the circulation through the dilated vessels; and he aptly compares the condition with that of the parts beneath a cupping-glass or other exhausted receiver.

The following measurements of the acromegalic skull under consideration were made by Sir William Flower, and are those which are systematically carried out upon the crania comprising the extensive collection the College possesses:

C.	525 millimetres.	B.	156 millimetres.
L.	198 ,,	H.	130 ,,
B.i.	788 ,,	H.i.	657 ,,
B.N.	104 ,,	B.A.	102 ,,
A.i.	981 ,,	N.h.	61 ,,
N.w.	25 ,,	N.i.	410 ,,

Digitized by Google

O.w. 44 millimetres. O.h. 41 millimetres.
O.i. 932 „ C.a. 1500 c.cm.

C. Horizontal circumference taken with the tape passing in front round the supra-orbital line (above the glabella), and behind across the most prominent part of the occiput.

L. Length. Taken from the ophryon or centre of the supra-orbital line above the glabella to the most distant part of the occiput.

B. Breadth. The greatest parietal breadth.

Bi. Index of length, $\frac{B \times 100.}{L}$

H. Height. The distance between the basion (middle of the anterior margin of the foramen magnum) to the bregma (point of junction of the coronal and sagittal sutures).

Hi. Index of length, $\frac{H \times 100.}{L}$

BN. Basi-nasal length. Basion to nasion (middle of the anterior margin of the foramen magnum to middle of the naso-frontal suture at the root of the nose).

BA. Basi-alveolar length (basion to alveolar point or the most distant part of the anterior margin of the alveolar arch).

Ai. Alveolar index, $\frac{BA \times 100.}{BN}$

Nh. Nasal height (the distance between the nasion and lower border of the nasal aperture).

Nw. The greatest width of the nasal aperture.

Ni. Nasal index, $\frac{Nw. \times 100.}{Nh}$

Ow. Orbital width. From the spot where the ridge which forms the posterior boundary of the lachrymal groove meets the fronto-lachrymal suture, to the most distant part on the front edge of the outer border of the orbit.

Oh. Orbital height. The distance between the upper and lower margins of the orbit at the middle.

Oi. Orbital index, $\frac{Oh. \times 100.}{Ow.}$

Ca. Capacity in cubic centimetres.

In the acromegalic type of cranium, however, the elongation of the superior maxillæ and increased volume of the lower jaw constitute the salient features; and as these are not indicated by

Digitized by Google

the foregoing measurements (with the exception of the nasal height or distance between the fronto-nasal suture and lower border of the nasal aperture), I may add to Sir William Flower's table those particularly relating to the jaws, adopting for this purpose Sir William Turner's scheme of mensuration ("'Challenger' Report on Human Crania," 'Zool. Chall. Exp.,' vol. x, 1884), especially as this has been employed by Dr. Alexis Thomson in the case already adverted to. The particular craniometer used was that devised by Sir William Flower, and described by him in the Anthropological Catalogue of the College.

Naso-alveolar height.—From the nasion or middle of the naso-frontal suture at the root of the nose to the alveolar point or centre of the anterior margin of the upper alveolar arch, 88 millimetres. (In Dr. Alexis Thomson's acromegalic skull this measurement is 81 millimetres.)

Nasal height.—Between nasion and lower border of the nasal aperture, 61 millimetres. (In Dr. Thomson's skull, 59 millimetres.)

Facial length.—Vertical diameter of the face from the nasion to the lowest point in the mid-line of the lower jaw, 143 millimetres. (In Dr. Thomson's skull this is 148 millimetres; and he adds that he found the average in ten adult Scottish crania in Sir William Turner's collection to be 124·5 millimetres.)

Taking next the measurements of the lower jaw. As in other typical examples of acromegaly, the mandible is abnormally prominent at the symphysis.

Symphysial height.—Extreme vertical measurement at the symphysis, 40 millimetres.

Condyloid height.—Distance from the angle or gonion to the upper surface of the condyle, 93 millimetres. (In Dr. Thomson's skull this is 90 millimetres.)

Breadth of ascending ramus.—At the level of the alveolar border, 38 millimetres. (In Dr. Thomson's skull this is 36 millimetres.)

Intergonial width.—Extreme width between the angles, 111 millimetres. (In Dr. Thomson's skull this is 101 millimetres.)

Dimensions of the enlarged pituitary fossa.—Antero-posterior diameter, 20 millimetres. Transverse diameter, 20 millimetres. Depth, 20 millimetres. (In Dr. Thomson's skull the corresponding diameters are 22·5, 21, 18 millimetres.)

Digitized by Google

The relation of acromegaly to giant growth has been variously stated. Some have maintained that when the disease arises in youth, giant growth results; when in the adult, it assumes the form of simple acromegaly; and further, that all giants are acromegalic.

In the College Museum there are the skeletons of two giants (Nos. 223, 224). That of Charles Byrne or "O'Brian" (7 feet 7 inches) I should view, with Dr. D. J. Cunningham ('Transactions of the Royal Irish Academy,' 1891), as acromegalic. The lower jaw is massive, the chin particularly prominent, the glabella very projecting, and the cranial bones dense and thickened; the pituitary fossa measures antero-posteriorly 22 mm. The capacity of this skull is 1520 c.c.; its circumference, 1500 mm. Byrne died at the age of 22. Neither his father, mother, brother, nor any other member of his family was of unusual size. Though commonly known in London as the Irish giant, this skeleton is not to be confounded with that of Cornelius Magrath, in the Museum of Trinity College, Dublin, which is fully described by Dr. Cunningham (loc. cit.), who showed it to be that of an acromegalic, the pituitary fossa being considerably enlarged and its boundaries deformed.

The Irish giant referred to in Sternberg's monograph is the one in Dublin, Byrne having escaped that author's notice, probably owing to the source of confusion pointed out.

The other giant skeleton in the College collection is 6 feet 8 inches in height (2030 mm.), and is that of a man known as Freeman, the American giant, who died in 1845 in the County Hospital, Winchester, having come to London in 1842 and trained for a prize fight. In the College catalogue he is erroneously stated to have died in 1854. This man was known to and examined by Mr. J. Hutchinson, who has given his respiratory capacity in his classical paper "On the Capacity of the Lungs," 'Medico-Chirurgical Transactions,' vol. xxix (1846). Freeman's death took place from phthisis; this was indicated during life by the expectoration of large quantities of pus and extreme emaciation. After death extensive tuberculosis of the lungs was found. In regard to this skeleton I have come to the conclusion that it is not one of an acromegalic but of a normal giant; and for this reason I append photographs of the skull, together with a series of measurements corresponding with those given under the acromegalic

Digitized by Google

specimen. The exterior of this skull is everywhere smooth, nor is there anywhere anything suggestive of abnormality in the osseous tissue. The thickness of the calvaria at a distance of 20 mm. behind the bregma does not exceed 6 mm., and the trephined surface displays a normal distinction of tables and diploë. A certain degree of prognathism is present, but in itself this is not, of course, a pathological feature. I have given its actual degree further on. The most remarkable difference between this skull and the acromegalic is brought out by the altitudinal measurements of the upper and lower jaws.

The naso-alveolar height is but 76 mm., as contrasted with 88 mm.; the nasal height is 50, as contrasted with 61; the condyloid height of the lower jaw is but 73, as contrasted with 93 in the acromegalic.

The following are the measurements of Freeman's skull determined by Sir William Flower:

C., circumference, 540 mm.
L., length, 191.
B., breadth, 145.
B. i., index of length, 759.
H., height, 149.
H. i., index of height, 780.
Capacity, 1630 c.cm.

To these I may add the following from my own determinations:

Pituitary fossa; antero-posterior diameter 12 mm.
Naso-alveolar height 76.
Nasal height 50.
Facial length 134.
Symphysial height of lower jaw 37.
Condyloid height 73.
Breadth of the ascending ramus 40.
Intergonial width 101.
Alveolar index 1026.

Although Sir William Flower gives (in his preface to the College Anthropological Catalogue) as the formula for determining this index $\frac{B\,a \times 100}{B\,N}$, all the alveolar indices in the catalogue have been taken by multiplying with 1000 instead of 100. By this

Digitized by Google

means a result is obtained in three or four figures, which dispenses with the use of decimals or fractions.

$$\frac{\text{B a} \times 1000}{\text{B N}} = \frac{117 \times 1000}{114} = 1026$$

The alveolar index, as a measure of prognathism, was introduced by Sir William Flower, and it is one of the least open to objection, giving, as it does, the relation of the two distances: (1) from the anterior margin of the foramen magnum to the root of the nose; (2) from the anterior margin of the foramen magnum to the most projecting point of the upper jaw.

Sir William Flower has divided crania, according to their alveolar indices, into—

Orthognathous; index below 980.

Mesognathous; index 980 to 1030.

Prognathous; index above 1030.

Freeman's skull, therefore, with an index of 1026, stands below the prognathous series of this scheme.

The European and English skulls in the college collection come, as a whole, within the orthognathous division.

Nothing being known of Freeman's ancestry, it is impossible to say whether or not the mesognathism indicates a racial mixture.

The American Indians of all tribes in the college collection, 109 in number, give an average alveolar index of 1020; they are mesognathous.

The prognathism of the African negroes (who present this feature in the highest degree) is 1044.

Individuals in all races may considerably exceed the average Among the Australian skulls (which are prognathous) is one with an alveolar index of 1071; another reaches the extreme of 1083. Of the European skulls Sir William Flower determined, moreover, that 73·4 per cent. were orthognathous; 20·1 mesognathous; 6·5 prognathous.

In his 'Elements d'Anthropologie générale' (Paris, 1885), Topinard divides prognathism into three kinds, the most important of which concerns the alveolar portion of the superior maxilla—alveolar prognathism, or the forward projection of the upper jaw below the lower level of the nose. In Topinard's method of estimating prognathism the cranium is placed horizontally, resting upon the condyles and alveolar point, not the teeth; a perpendicular

Digitized by Google

is dropped to this horizontal plane, at the alveolar point, and from this perpendicular horizontal measurements are taken: (1) to the "spinal point" (the lower border of the anterior nares at the virtual centre of the nasal spine); (2) to the nasion; (3) to the ophryon. Indices may be obtained by taking the height of these points and calculating the relation of the horizontal measurements to the perpendicular ones; or the result may be expressed as an angle giving the inclination on the horizontal plane of lines drawn to the alveolar point from the facial extremities of the horizontals noticed.

In Freeman's skull the horizontal projection of the alveolar margin beyond the lower limit of the nose, as measured from the base of the nasal spine, is 15 mm., and the height of this horizontal above that of the base of the skull on the alveolo-condylar plane is 25 mm. (alveolar prognathism of Topinard).

The distance from the perpendicular to the nasion is 24 mm., and the height of this horizontal from the alveolo-condylar plane, 74 mm. (maxillary prognathism of Topinard).

The distance from the perpendicular to the ophryon is 28 mm.; the height of this horizontal from the alveolo-condylar plane is 101 mm. (facial prognathism of Topinard).

Topinard's indices are obtained by multiplying the horizontal distances by 100 and dividing the result by the vertical.

	Vertical.	*Horizontal.*	*Index.*
Alveolar prognathism . .	25 mm. ...	15 mm. ...	60
Maxillary prognathism . .	74 ,, ...	24 ,, ...	32·4
Facial prognathism . .	101 ,, ...	28 ,, ...	27·7

This gives a remarkably high degree of "alveolar prognathism," and I cannot but feel myself that Sir William Flower's alveolar index conveys a more correct idea of the prognathism present in the skull under consideration than Topinard's. The objection thought so weighty by the latter author to Flower's index—viz. that it is open to vitiation arising from flattening of the cranial base, remains unremoved in the system devised by himself. In Topinard's method the cardinal horizontal plane is obtained by resting the skull upon the condyles and alveolar point; and a flattened base, by virtually lowering the posterior part of the skull, would remove the facial extremities of the three horizontals (to the

Digitized by Google

nasal point, the nasion, and ophryon) away from the perpendicular dropped to the alveolar point, with the result of increasing the whole of the indices.

The teeth in Freeman's skull are remarkably perfect, and it is to be particularly noted that although "mesognathous," there is no projection of the lower jaw beyond the upper The skull in acromegaly, on the contrary, is "underhung;" the lower alveolar arch lies without the upper. As Maximilian Sternberg points out, this condition is not to be confused with prognathism; it should be distinguished by some special term, such as L. Mayer's,—cranium progeneum (progenēus, modern Latin transcript of προγένειος).

Freeman's skull is prognathous, not progeneic; and although that of a giant it is not acromegalic. According to the computation of Sternberg, nevertheless ('Specielle Pathologie und Therapie,' Theil 2, Band vii, "Die Akromegalie"), 40 per cent. of giants are acromegalic. There are, in short, normal giants and pathological giants, as there are normal and pathological dwarfs; and the college skeletons of Freeman and Byrne afford examples of each.

October 18*th*, 1898.

---

2. *Symmetrical senile atrophy of parietal bones.* (*Card specimen.*)

By H. Morley Fletcher, M.D.

This condition of the skull-cap of a woman aged 79, who died at St. Bartholomew's Hospital in consequence of a fractured femur, was first discovered at the *post-mortem* examination.

The skull-cap showed a symmetrical thinning of the median and posterior portions of both parietal bones, the osseous tissue having been reduced to a thin transparent sheet of bone, little thicker than ordinary letter paper. There was no thickening of the bone at the edges of the thinned area, though there was some degree of porosity. The rest of the skull-cap appeared normal. The vascular grooves on the inner surface were deeply marked. The brain

Digitized by Google

beneath the thinned areas and the soft tissues above appeared to be normal.[1]

Similar cases have been described in these 'Transactions' by Mr. F. S. Eve,[2] and elsewhere by Sir G. Humphry.[3]

April 18th, 1899.

---

3. *Crushed fracture of cervical spine.*

By H. P. Potter, M.D.

The man from whom this specimen was removed was 82 years of age. In 1879, twenty years ago, he was struck on the occiput by a falling wall and the cervical spine was forcibly flexed. He remained unconscious for two days, but indistinctly remembered some one pulling upon his head and twisting it from side to side. When consciousness returned he noticed loss of power of the right arm and leg, which was only temporary. An immoveable apparatus was applied to the head and neck, and he was kept in bed for four months; made a satisfactory recovery and lived till August, 1898.

When I first saw the man in 1880, there was a hard prominence in the median line at the back of the neck, extending from one inch below the external occipital protuberance to the sixth cervical spinous process, measuring four inches in diameter. The trapezii appeared to be incorporated with the prominence on each side. The manubrium sterni, upper three costal cartilages, and larynx were abnormally prominent, the chin almost touched the sternum, and the posterior boundary of the pharynx could hardly be reached with the tip of the finger. Without the history of injury, the swelling presented a nice case for diagnosis.

The specimen is a vertical antero-posterior section through the cervical spine and cord. Some crushing force has pressed the vertebral bodies into a mass. The intervertebral cartilages have disappeared, but their outlines are still marked and their places

[1] The skull-cap is in St. Bartholomew's Hospital Museum, No. 7A.

[2] Eve, 'Trans. Path. Soc.,' vol. xli, 1890, p. 242.

[3] Humphry, 'Trans. Roy. Med. and Chir. Soc.,' vol. lxxiii, 1890, p. 327.

Digitized by Google

are occupied by bone. The axis or second vertebra is at right angles to the spine; the third body is much deformed, the fourth

FIG. 17.

is a six-sided figure in the section, the fifth has become a perfect triangle; the sixth and seventh are displaced and pressed together, so that the distance between the upper extremity of the axis and the lower border of the seventh cervical is reduced to two inches. The spinal cord is probably not stretched, although it is bent round the prominence of the bodies, nor is the spinal canal encroached upon by displaced vertebræ. There has probably been hæmorrhage external to the sheath, for suggestive organised shreds still remain.

Digitized by Google

The conditions shown in the specimen are somewhat unusual, and I have not been able to find a preparation in the London museums of a similar nature. Great force must have been applied to the spine, but the direction of this force was fortunately such that dislocation and sudden death did not ensue. On the other hand, the man, as I have stated, lived twenty years after the injury, and finally died from senile decay. *January 17th*, 1899.

---

4. *Central sarcoma of os calcis.* (*Card specimen.*)

By P. DE SANTI.

PATIENT aged 22, an out-patient at Westminster Hospital, complained of pain and swelling in outer part of os calcis, and on walking had a sharp shooting sensation in the foot. No history of injury was obtained. He had noticed the swelling about six months. On examination a tender, ill-defined swelling was found over the outer part of os calcis, with some redness of skin and œdema. There was no synovitis of the ankle-joint. There was no history of tubercle or syphilis. No wasting or trouble elsewhere.

An exploratory incision was made, the case being regarded as probably one of tubercle of the os calcis. The swelling turned out to be a spindle-celled endosteal sarcoma infiltrating the surrounding tissues and completely filling the os calcis. The leg was removed just below the knee-joint, and the patient made an excellent recovery. The interest of the case consisted in the diagnosis between tubercle and sarcoma – the pain and tenderness on pressure, the redness, œdema, and absence of any egg-shell crackling pointed to tubercle or chronic abscess of bone. The history of no injury and six months duration were in favour of sarcoma. It was not until an exploratory incision was made that an absolute diagnosis could be made. Another point of interest was the microscopic appearance of the growth; usually endosteal sarcomata were myeloid, in this case it was a spindle-celled sarcoma. *January 3rd*, 1899.

Digitized by Google

5. *A case of apparently aseptic suppuration of the knee-joint following injury, and associated with phagocytosis of extravasated red blood-corpuscles by leucocytes.*

By F. W. Andrewes, M.D.

Non-bacterial suppuration is well known as an experimental fact, but is much rarer clinically. The present case is brought forward as an example of well-marked acute suppurative arthritis coming on a week after injury, in which no micro-organisms were demonstrable either microscopically or by culture on repeated examination, but in which blood appeared to have been originally effused into the joint; the red corpuscles being disposed of by a process of phagocytosis during the inflammatory reaction.

A man aged 25 was injured on April 29th, 1897, by a heavy door falling on him and striking him on the right loin. Profuse hæmaturia followed, apparently due to laceration of the kidney. He was admitted to St. Bartholomew's Hospital under Mr. Willett, and the hæmaturia cleared up in a week or two. There had been some pain in the right knee from the time of the accident, but the knee was at first to all appearances normal. The pain grew worse, and on May 6th, a week after the accident, the temperature rose. Next day there was a little grating in the joint but no effusion.

On May 11th the fever varied from 101° to 103°, and there was much effusion into the joint, with intense pain and tenderness, but no redness. It was decided to aspirate the joint, and this was done on four occasions, on May 11th, 13th, 14th, and 15th, each time with relief, from 3 to 5 oz. of synovia mingled with blood and pus being withdrawn on each occasion. By May 19th the fever had disappeared, and there was no longer any effusion into the joint. The patient eventually recovered without any appreciable loss of mobility of the joint.

Three of the four specimens of fluid removed from the joint were submitted to me for examination,—the first, second, and fourth aspirations—two days interval elapsing between each aspiration.

The fluid from the first aspiration separated on standing into a nearly clear viscid synovia, somewhat bloodstained, with an abundant

Digitized by Google

deposit of red blood-corpuscles and pus cells, the latter preponderating. The pus cells were very large, and contained abundant brightly refractile fat granules; nuclei polymorphous and beginning to undergo fragmentation. Most of the red corpuscles were free, but many were included in the large leucocytes, sometimes two and even four in one leucocyte. The appearance was striking and unmistakable in the fresh state, and could be demonstrated equally well by careful staining. No trace of any micro-organisms could be found in the stained specimens, but I made no cultures from this specimen.

Two days later, at the second aspiration, I made agar-agar cultivations direct from the aspirating needle at the bedside; they remained sterile, and again no micro-organisms were microscopically demonstrable. This time the fluid was clearer, and on standing, perfectly clear synovia separated out above. Much less blood was present, and the red corpuscles were more often included in leucocytes than free. The stained specimens shown were prepared from this specimen.

Two days later still, at the fourth aspiration, the fluid was again more turbid and blood-stained, and the deposit more closely resembled ordinary laudable pus. Hardly any included red corpuscles were now present. Again no micro-organisms could be demonstrated in any way.

Clinically the case was clearly one of acute arthritis with a considerable amount of pus in the joint, and with fever and constitutional symptoms running parallel with, and being obviously dependent upon, the joint inflammation. Failure to demonstrate and cultivate micro-organisms can by no means be held to prove their absence, but my experience has been that it is usually easy to demonstrate micro-organisms in acute suppurative arthritis.

I have met with no similar case, and I bring it forward rather with the view of eliciting the experience of others than with any pretence at offering an explanation myself. But I suggest that as the result of the injury blood was effused into the joint, and subsequently setting up irritation, was removed by a process of clearly demonstrable phagocytosis, the extent and character of which seems to point to the red corpuscles as the irritant agency. I am not by any means an upholder of an exclusively phagocytic theory of inflammation. Yet it is certain that phagocytosis does occur in inflammations of many kinds; and I put this case forward

Digitized by Google

as one in which the phenomenon was marked, and very easily demonstrable.

I may mention in conclusion one or two incomplete observations which I made on the fluid withdrawn from the joint. The different samples being left about in the laboratory for a week or so, showed no tendency to putrefaction. Some of the clear synovia, decanted without special precautions into sterilised test-tubes and plugged with sterile wool, underwent no change for many weeks, though after a month or two slight bacterial growth occurred in most of the tubes. Some of the tubes were inoculated with *B. anthracis*, *Staphylococcus aureus*, *Proteus vulgaris*, and *B. prodigiosus*. These all showed good growth in a day or two. Hence there was nothing actually germicidal in the fluid, though it was evidently a poor soil for bacterial growth. Chemically there was a good deal of nucleo-proteid in the fluid; at least, when digested with HCl and pepsin, it gave a considerable insoluble precipitate, which dissolved in dilute alkali. *May 2nd*, 1899.

Digitized by Google

VII. DISEASES, ETC., OF THE DUCTLESS GLANDS.

1. *Hypertrophy of the pituitary body.*

By J. and T. W. P. Lawrence.

Since the publication of the first descriptions of acromegaly by Marie in 1886, a considerable number of specimens of enlarged pituitary body have been described. Rather more than one half of these have been found associated with acromegaly; whilst the remainder (references to which are appended to this paper) include various new growths and enlargements, of which hypertrophy forms but a small proportion. Two or three cases only of hypertrophy of the gland, apart from acromegaly, have been placed on record, excepting those instances of slight increase in size observed in such conditions as myxœdema and cretinism. Since, however, the terms hypertrophy and adenoma have sometimes been used synonymously in their application to the pituitary body, it is possible that the rarity of recorded examples of hypertrophy may to some extent admit of explanation. The specimen to be described is of interest both as an instance of marked hypertrophy of the gland not associated with acromegaly, and as presenting with some distinctness the characters which distinguish hypertrophy from adenoma.

The patient, a railway inspector by occupation, died at the age of fifty-two, the *post-mortem* examination disclosing enlargement of the pituitary body as the cause of death. Six years before his death the patient sought medical advice on account of dimness of sight, and at that time the field of vision was, on examination, found to be contracted externally on both sides. No history of syphilis, alcoholism, or excessive smoking was obtainable. A trace of albumen was present in the urine, but apart from this and the dimness of sight the general health was good. The history of the case during the succeeding six years is characterised by alterations affecting the speech and the gait, and by progressive general

Digitized by Google

weakness of the body, and, towards the end, of the mind also. The speech gradually became much impaired, slow and drawling in character, and the gait somewhat ataxic. The contraction of the field of vision steadily increased, until ultimately the patient was only able to distinguish objects situated directly in front of him. The patient was confined to bed during the last twelve months of the illness; and latterly a perforating ulcer developed on each foot, and the hair was noticed to have become coarser. There was no enlargement of the jaw, hands, or feet.

At the *post-mortem* examination, which was restricted to the cranial cavity, the bones of the cranium were found to be rather thin, and the dura mater was more adherent to them than normal; the frontal sinuses were not obviously enlarged. The pituitary fossa was expanded by the enlarged pituitary gland, which was, to a great extent, of semi-fluid consistence, and could not be removed entire.

On examination of the base of the brain, the space bounded laterally by the temporal lobes and posteriorly by the pons Varolii is found to be occupied by a tumour (Fig. 18) measuring nearly 3·5 cm. from before back, and about 2·5 cm. transversely; and the greatly thinned optic commissure is stretched over the rounded anterior surface of the growth. The tumour is divided by a shallow transverse groove into an antero-superior and a postero-inferior portion. The anterior portion is hemispherical in shape, is quite smooth on the surface, and measures 2 cm. in diameter. The posterior and larger portion measures nearly 3 cm. at its broadest part, and 2·5 cm. from before back; and its surface is rendered irregular by a large fissure leading into a cavity in the centre of the tumour, the fissure having been produced at the *post-mortem* examination, when a considerable quantity of semi-fluid tumour-substance was lost. The surface of the posterior portion, although uneven, is smooth, except at the ragged aperture mentioned; and the whole tumour is covered by a very delicate fibrous layer. The growth can readily be raised from surrounding structures, being free from adhesions, and it shows no signs of having infiltrated the adjacent tissues. The crura cerebri and the optic tracts are pushed aside and compressed by the rounded antero-superior portion of the tumour, and the optic commissure is less than 1 mm. in thickness.

A median section of the brain exhibits the exact anatomical

Digitized by Google

FIG. 18.

Hypertrophy of the pituitary body.

FIG. 19.

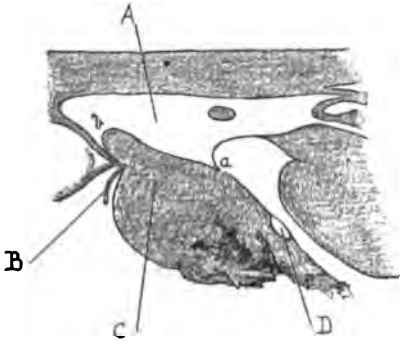

Median section of hypertrophied pituitary body.

Digitized by Google

relations of the tumour (Fig. 19); it will be noted, however, that the form and position of the several structures are considerably altered, owing to some degree of vertical compression of the brain having occurred in the process of hardening. There is present on the postero-superior surface of the tumour a small fragment of bone (D) from the upper margin of the dorsum sellæ; higher up on the same surface the lamina cinerea meets the tumour at the apex of the infundibulum (*a*), and the portion of the tumour which is situated between these two points may be taken to represent the greatly thickened pedicle, whilst the portion below D represents the enlarged and excavated body of the gland. In addition to the increase of the pedicle in thickness, an extension of this part of the growth has taken place in an upward direction, so that the greatly stretched anterior wall of the infundibulum, which lies between the point *a* and the posterior margin of the optic commissure B, is closely applied to the upper part of the tumour; and there is a further extension upwards above the optic commissure in the form of a small nipple-shaped process (*b*), which projects into the cavity of the third ventricle.

FIG. 20.

Microscopic appearances of hypertrophied pituitary body.

The tumour is uniform in texture and of soft consistence, and it presents the same microscopic structure throughout (Fig. 20). In those parts in which degeneration has not occurred it is constituted of a stroma of very delicate fibrous trabeculæ, which separate large,

Digitized by Google

irregular, and intercommunicating spaces filled with epithelial cells. The cells are polygonal in shape and have an average diameter of 10 micromillimetres; they have large, round or oval, and deeply staining nuclei, and they appear to be all of the same kind. Towards the surface of the tumour the cell spaces become narrower and many of them oval in shape, and they resemble more closely the alveoli of the anterior lobe of the normal gland than the deeper spaces of the growth do. The outermost spaces appear in section as narrow clefts, disposed parallel to the surface, in what has previously been mentioned as the fibrous covering of the tumour, and they are mostly occupied by a single or double layer of cells, though from some of them cells are altogether absent. Although the cell spaces thus differ somewhat in form in the central and in the peripheral parts of the tumour, a gradual transition is traceable from the central parts to the peripheral; there is no break in the continuity of the tissue, which is of essentially the same structure from the surface to the centre of the growth. No cysts appear to be present in the tumour, and there is no colloid material in the alveolar spaces. Nothing resembling the posterior lobe is discoverable either on macroscopic or microscopic examination.

The condition described has been called adenoma by some, hypertrophy by others; but that the diagnosis of hypertrophy is the correct one in such cases seems to admit of little doubt. The several parts of the gland are recognisable, and are seen to be affected by a diffuse change—the glandular portion of the pedicle equally with the anterior lobe of the gland—and no encapsuled or circumscribed tumour is present. The clinical history, the absence of infiltration, and the microscopic examination exclude the explanation of the diffuse change as possibly being due to an infiltrating growth, and the microscopic structure of the tumour is not opposed to the diagnosis of hypertrophy. For although the cell spaces of the tumour deviate to some extent from those of the normal gland in size and in the number of their contained cells, it is to be remembered that such deviations are sometimes met with even in true compensatory hypertrophy (as in the thyroid gland after its partial ablation), and that where the hypertrophy has a pathological rather than a physiological origin (as may be presumed to be the case in the present instance) some deviation from the normal structure is almost to be expected.

Digitized by Google

Literature subsequent to 1886.

Anders (*J. M.*) and *Cattell* (*H. W.*).—"Hæmorrhagic Tumour of the Pituitary Body and Infundibulum in a Case of Pernicious Anæmia," 'Journ. Nerv. and Mental Dis.,' 1892, vol. xix, p. 9.

Anderson (*J.*).—"On Sensory Epilepsy: a Case of Basal Cerebral Tumour," 'Brain,' 1886–7, vol. ix, p. 385.

Audry (*M. J.*).—"Cancer de la glande pituitaire observé chez un enfant," 'Lyon Méd.,' 1888, vol. lix, p. 73.

Beadles (*C. F.*).—"Malignant Disease at the Base of the Skull involving the Pituitary Fossa," 'Trans. Path. Soc.,' 1895, vol. xlvi, p. 172.

v. Bonsdorff and *Homén*.—"Sarcoma der Hypophysis cerebri," 'Neurolog. Centralbl.,' 1893, vol. xii, p. 391.

Boyce (*R.*) and *Beadles* (*C. F.*).—"A Further Contribution to the Study of the Pathology of the Hypophysis Cerebri," 'Journ. of Path. and Bact.,' 1893, vol. i, p. 223 (Glandular growth, secondary growth).

Burr (*C. W.*) and *Riesman* (*D.*)—"Report of a Case of Tumour of the Hypophysis without Acromegaly," 'Journ. Nerv. and Mental Dis. N.Y.,' 1899, vol. xxvi, p. 20 (Sarcoma).

Collina (*M.*).—"Sull' origine e considerazioni sul significato della ghiandola pituitaria," 'Rivista Sper. di Fren.,' 1898, vol. xxiv, p. 553.

Cristian.—"Hallucinations persistantes de la vue chez un dément, provoquées et entretenues par une tumeur de la glande pituitaire," 'Ann. médico-psych.,' 1892, vol. xvi, p. 114.

Fraser (*D.*).—"Base of Brain with a Tumour of the Pituitary Body," 'Glasgow Med. Journ.,' 1898, vol. l, p. 212 (Sarcoma).

Gutsche (*P.*).—"Zur Pathogenese der Hypophysis-Tumoren und über den nasalen Abfluss sowie das Verhalten des Liquor cerebro-spinalis bei einer Struma pituitaria," 'Diss. Erlangen.'

Handford (*H.*).—"Large Tumour of the Pituitary Body," 'Brain,' 1892, vol. xv, p. 463 (Sarcoma); 1894 [Struma pituitary].

Heusser (*J.*).—"Ein Beitrag zur Casuistik der Hypophysis-Tumoren," 'Virchow's Arch.,' 1887, vol. cx, 1, p. 1 (Lympho-sarcoma).

v. Hippel (*E.*).—"Ein Beitrag zur Casuistik der Hypophysis-Tumoren," 'Virchow's Arch.,' 1891, vol. cxxvi, p. 124 (Adenoma).

Hlava (*M.*).—"Tumeur de l'hypophyse," 'Rev. neurologique,' 1894, vol. ii, p. 516.

Holsti.—"Fall von Vergrösserung der Hypophysis cerebri," 'Neurolog. Centralbl.,' 1893, vol. xii, p. 424.

Hughes (*W. E.*).—"Two Cases of Tumour of the Base of the Brain," 'Journ. Nerv. and Mental Dis.,' 1898, vol. xxv, p. 207.

Ingermann (*S.*).—'Zur Casuistik der Hypophysis-Tumoren,' Berne, 1889 (Struma Gelatinosa Sarcoma).

Digitized by Google

Kerr.—"Cystic Tumour of the Pituitary Body," 'Brit. Med. Journ.,' 1890, vol. ii, p. 1014.

Kerr (*J.*).—"A Case of Adenoma of the Pituitary Body," 'Lancet,' 1891, vol. i, p. 195.

Körner (*O.*).—"Abfluss von Liquor cerebro-spinalis durch die Nase und Opticus Atrophie verursacht durch eine in die Keilbeinhöhle durchgebrochene Geschwulst der Hypophysis cerebri," 'Zeitschr. f. Orenh.,' Wiesb., 1898, vol. xxxiii, p. 1.

Langer (*F.*).—"Ueber cystische Tumoren im Bereiche des Infundibulum cerebri," 'Zeitschr. f. Heilk.,' 1892.

Leclerc (*F.*)—"Note sur trois cas de tumeurs intracraniennes," 'Revue de Méd.,' 1887, vol. vii, p. 977 (Carcinoma).

Le Noir.—"Tumeur du corps pituitaire," 'Bull. de la Soc. Anat.,' 1888, vol. ii, p. 1016.

Loeb (*M.*).—"Beiträge zur Lehre vom Diabetes mellitus. 1. Hypophysis cerebri und Diabetes mellitus," 'Centr. f. inn. Med.,' 1898, vol. xix, p. 893.

Müller (*O. V.*).—'Zwei Tumoren der Hypophysis cerebri,' Inaug.-Diss., Leipzig, 1897.

Packard (*F. A.*).—"A Case of Acromegaly and Illustrations of Two Allied Conditions," 'Internat. Journ. Med. Sci.,' 1892, vol. ciii (Hypertrophy).

Pechkranz (*S.*).—"Zur Kasuistik der Hypophysis-Tumoren," 'Neurolog. Centralb.,' 1899, vol. xviii, pp. 203, 254 (Sarcoma).

Rath (*W.*).—'Ein Beitrag zur Kasuistik der Hypophysis-Tumoren,' Inaug.-Diss. Göttingen, 1888; and "Beitrag zur Symptomlehre der Geschwülste der Hypophysis cerebri," 'Arch. f. Ophthalmol.,' 1888, vol. xxxiv, 4, p. 81 (Sarcoma).

Reymond (*E.*).—"Tumeur du corps pituitaire," 'Bull. de la Soc. Anat.,' 1893, vol. vii, pp. 539, 687 (Epithelial tumour).

Roscioli (*R.*).—"Tumore della glandula pituitaria," 'Neurolog. Centralbl.,' 1891, vol. x, p. 309 (Adeno-carcinoma).

Saundby.—"Alveolar Sarcoma of the Pituitary Body," 'Brit. Med. Journ.,' 1887, vol. ii, p. 1387.

Shaw (*R. H.*).—"Ptosis produced by an Intra-cranial Lipoma," 'Brit. Med. Journ.,' 1896, vol. ii, p. 1828.

Sibley (*W. K.*). Abscess of Brain with Tumour of the Pituitary Body and Abscesses in the Lungs in a Ewe," 'Trans. Path. Soc.,' 1887–8, vol. xxxix, p. 459 (Adenoma).

Smith (*F. J.*).—"Tumour of the Pituitary Body," 'Hunterian Journ.,' 1897–8, p. 77.

Sutherland (*L. R.*).—"Sarcoma of Pituitary Body occupying Sella Turcica and impinging on Brain," 'Glasgow Med. Journ.,' 1898, vol. l, p. 215.

Targett (*J. H.*).—"A Tumour of the Pituitary Fossa," 'Trans. Path. Soc.,' 1895, vol. xlvi, p. 170 (Endothelioma).

Waddell (*W.*).—"Some Clinical Notes on a Case of Tumour of the Pituitary Body," 'Lancet,' 1893, vol. i, p. 921; and *Thorburn* (*W.*).—"Tumour of

Digitized by Google

the Pituitary Body," 'Trans. Path. Soc. Manchester,' 1891–2, vol. i, p. 70 (Hypertrophy ?).

Whitwell (*J. B.*).—"Tumour of the Pituitary Body," 'Journ. of Ment. Sci.,' 1889, vol. xxxv, p. 199 (Myxo-sarcoma).

Wills (*E.*).—"Tumour of the Pituitary Body without Acromegaly," 'Brain,' 1892, vol. xv, p. 465 (Goitre of pituitary body).

Wolf (*K.*).—"Ein Beitrag zur Pathologie der Hypophysis," 'Beitr. z. path. Anat. u. Allgem. Pathol.,' 1893, vol. xiii, p. 629 (Secondary malignant growth).

Wood.—"Tumour of the Pituitary Body," 'Lancet,' 1895, vol. i, p. 993 (Adenoma).

Woolcombe (*W. L.*).—"A Case of Virchow's Psammoma of the Pituitary Body, with Remarks as to the Function of that Structure," 'Brit. Med. Journ.,' 1894, vol. i, p. 1351.

April 4th, 1899.

---

2. *Two cases of splenic anæmia with internal hæmorrhages in infants.*

By G. Bertram Hunt, M.D.

Cases of enlargement of the spleen with severe anæmia in infants who are usually rickety are, of course, common; but it is very doubtful whether such cases should be termed splenic anæmia, and it has been doubted whether this disease ever really occurs in infants. For this reason the occurrence of marked internal hæmorrhages is of interest.

The first case was a child of eight months, one of twins. During life the spleen reached below the umbilicus and across the middle line Red corpuscles 70 per cent.; hæmoglobin 28 per cent. No excess of leucocytes. There were no signs of rickets. During the disease, which lasted three and a half months, there was irregular fever. Severe diarrhœa was present during the last month of life.

Post-mortem.—The spleen was much smaller than during life. It measured 6 × 3 inches. Weight 7½ oz. Capsule thickened. Surface granular. On section it appeared too uniform, the normal pulp being replaced by a firm, structureless substance. Microscopically there was increase of fibrous tissue, not affecting so much the

Digitized by Google

trabeculæ, though these were somewhat thickened, as the splenic pulp, the cells of which were much diminished in number and surrounded by new fibrous tissue. The Malpighian corpuscles were almost entirely replaced by freshly formed, structureless connective tissue. The mesenteric glands were enlarged and of a deep red colour. Throughout the whole length of the large gut the mucous membrane was thickly studded with small hæmorrhagic patches, varying from one sixteenth to one half inch in diameter. Many of these had become ulcerated on the surface, and over others there was still an adherent slough.

Case 2 was a child of sixteen months, one of triplets. It differed from the other in presenting marked rickety bone changes. The spleen occupied the whole of the left half of the abdomen, reaching from the costal margin to the pubes. The liver was slightly enlarged. Frequent blood estimations gave on an average 30 per cent. of red corpuscles and 25 per cent. hæmoglobin; white to red 1 to 100. The red corpuscles were individually of fairly good colour, but varied much in shape and size. On staining, some of them were seen to be enucleated. There were occasional attacks of diarrhœa, and some irregular pyrexia. The child died with severe dyspnœa.

Post mortem the spleen weighed 4½ ounces, and measured 4½ × 3 inches. The surface was smooth. Capsule not thickened; cut section dense, pale, and mottled. Microscopically there is seen the same connective-tissue overgrowth in the splenic pulp and fibrosis of the Malpighian corpuscles as in the first case. Bones showed marked rickets, with red gelatinous marrow. Between the dura and arachnoid there was a layer of extravasated blood, in parts one third of an inch thick. On the right side it extended from base to vertex, and completely covered the cerebral hemisphere; on the left side it was less extensive. The blood-clot could be peeled off the dura in the form of a thick laminated layer. There were no false membranes or other signs of inflammation of the dura. The only symptom which could be ascribed to this hæmatoma was the terminal dyspnœa, which was not accounted for by any pulmonary condition.

The chief point to be considered is whether these are two genuine cases of splenic anæmia or not. One great difficulty in dealing with these cases in young children is to decide whether they may not be simply examples of rickets with anæmia and enlarged spleen. There is nothing in the blood examination which in my opinion is

Digitized by Google

sufficient to distinguish between the anæmia of rickets and splenic anæmia; and, indeed, in the later disease the blood condition is by no means constant. The blood in splenic anæmia may on the one hand be of the chlorotic type, as described by Banti, and which occurred in the first of these two cases; or it may resemble the blood of pernicious anæmia, in the great reduction of red corpuscles, poikilocytosis, and presence of nucleated red corpuscles. This condition of blood was described in cases of splenic anæmia by Bruhl, and was present in the second of these cases.

However, I think that rickety anæmia can be satisfactorily excluded here. In Case 1 there were no signs of rickets; and in Case 2, although there was severe rickets, yet the size of the spleen was far greater than that seen in this disease alone. The internal hæmorrhages, in one case into the mucous membrane of the large bowel, and in the other into the cerebral meninges, also form no part of rickets. Such visceral hæmorrhages have been occasionally seen in infantile scurvy, but in the present cases there were neither the determining causes nor other signs of scurvy. Lastly, I believe that there is considerable difference in the microscopical section of the enlarged spleen in the two diseases. In the spleen of splenic anæmia there is extensive fibrosis of the splenic pulp and Malpighian corpuscles; while in the enlarged spleen of rickets, as far as I have had the opportunity of seeing, the fibrous increase is chiefly in the trabeculæ, very little in the splenic pulp, and the Malpighian corpuscles remain unaltered, or are even hypertrophied.

Again, it has been considered that congenital syphilis plays a very prominent part in the production of these cases of infantile anæmia with enlarged spleen. Not only was there no trace of syphilis in these two children, but the other children of the same pregnancy remained quite healthy, the first case being one of twins and the second one of triplets.

The disease to which these cases of splenic anæmia seem most closely allied is anæmia infantum, pseudo-leuchæmia, and doubtless some of them have been described under this name; but in this condition, as described by von Jaksch, there is enormous increase of nucleated red corpuscles and marked excess of leucocytes, neither of which changes was found here.

In cases of splenic anæmia hæmorrhages are common. Epistaxis is the most frequent. West describes retinal hæmorrhage and fatal bleeding from a tracheotomy wound; hæmatemesis and spongy

Digitized by Google

gums are mentioned by Bruhl. Williamson and Müller both describe a single deep ulcer of the intestine which was probably due to a primary hæmorrhage into the mucous membrane, such as was evidently the cause of the multiple ulcers in my first case. These cases of hæmorrhages due to splenic anæmia all occurred in adults, and I can find no other recorded case of hæmorrhage of the dura mater due to this disease. *April 18th*, 1899.

---

3. *Cystic disease of the supra-renal gland.*

By Raymond Crawfurd, M.D.

This specimen, the left supra-renal, was removed from a patient under my own care, who died in the Royal Free Hospital. She was an elderly woman with chronic valvular disease, general arterial degeneration, and renal cirrhosis—the combined products of rheumatic fever in adolescence and drink in the later years of her life. There were no symptoms in life to indicate any lesion of the supra-renal capsules. *Post mortem*, over and above the conditions already mentioned, there were several cysts of varying sizes on the surface of each kidney; these cysts were those commonly seen in renal cirrhosis. The right supra-renal appeared quite normal. In the upper end of the left supra-renal was a two-lobed tumour, almost completely replacing that portion of the gland. The lower lobe of this tumour was about the size of a small walnut, quite spherical, and also cystic; the cyst wall was tense, elastic, and for the most part translucent, but here and there on its inner surface could be seen patches of solid residue, some of which were more or less cretaceous. The cyst was full of a turbid, colourless fluid, which under the microscope showed some amorphous *débris*, but no hooklets and no other foreign elements. The cyst was marked off by a clear capsule both from the healthy supra-renal tissue and from the contiguous solid tumour. This solid tumour, which was about the size of a hazel-nut, showed to the naked eye the ordinary appearance of supra-renal cortical tissue at its periphery, but in its centre was soft and looked very fatty.

Digitized by Google

Under the microscope the cyst is seen to have a definite wall of fibrous tissue; this wall separates the cyst also from the solid tumour. On the inner surface of the cyst wall are thin patches of solid tissue; these patches show from without inwards every gradation from the normal tissue of the supra-renal cortex to simple fat, in which no trace of specialised cells is to be seen. The solid tumour shows just the same replacement of normal supra-renal tissue by fat, and only at the extreme verge of the tumour can one make out a few polyhedral cells in groups and columns. These appearances make it pretty obvious that the cyst was originally a solid tumour that has undergone fatty degeneration with liquefaction and formation of a cyst. This confirms Virchow's suggestion that cysts of the supra-renal may be derived from degeneration of adenomata. The existing solid tumour is presumably an adenoma, if that term may be expanded to cover a localised hyperplasia of gland tissue. The presence of so well-marked a fibrous envelope around both cyst and solid tumour seems to me to present a difficulty that requires explanation. At the outer surface of each tumour this envelope is clearly the fibrous investment of the supra-renal capsule; perhaps the tumours have grown in accessory supra-renal bodies, which lay in the fibrous capsule of the supra-renal gland. As these accessory bodies have enlarged they will have expanded the fibrous capsule around them. The examination of a few normal supra-renal glands will show that this is a very common site of accessory gland tissue, and adenomata are well known to originate frequently in these accessory bodies.

Cysts of any kind in the supra-renal capsules are very rare, Hydatids and blood-cysts have both occasionally been noted. I can, however, only find a single record in the literature of morbid anatomy of a cyst of the kind I have described. That was exhibited by Dr. John Ogle at the Pathological Society of London; and in the volume of 'Transactions' for 1865 is recorded "A Cyst in the Left Supra-renal Capsule, about the Size of a Boy's Marble, having almost Transparent Parietes, and containing Turbid Serum." Dr. Rolleston, in 'Allbutt's System of Medicine,' alludes to "a cyst, the size of a cherry, containing tenacious fluid."

This specimen is now in the museum of the Royal Free Hospital.

January 17*th*, 1899.

Digitized by Google

4. *Cyst of the supra-renal body.*

By H. D. Rolleston, M.D.

There was a cyst in the right supra-renal body as large as a cherry, the contents of which were somewhat gelatinous, and free from any sign of past extravasation of blood.

Microscopically the cyst wall is composed of firm fibrous tissue, with a few epithelial cells on its inner surface; the substance of the supra-renal body appeared healthy.

As to the origin of the cyst, it is probable that it was due to softening down of an adenoma. Adenomata composed of supra-renal cells in a state of marked fatty change are by no means rare, and are sometimes found in a somewhat softened state. They are surrounded by a fibrous capsule, and the few cells attached to its inner surface in this specimen may be regarded as the remains of the diffluent adenoma.

It was found on the *post-mortem* examination of a man aged 66 years, who died with pneumonia and hemiplegia supervening after colotomy for a carcinomatous stricture of the upper part of the rectum. There were no secondary growths; there was no evidence of the cyst in the supra-renal body being a softened second growth.

January 17th, 1899.

5. *Some lesions of the supra-renal in the insane.*

By Cecil F. Beadles.

This, the right supra-renal body, is the seat of extensive hæmorrhage, which infiltrates the whole organ, and in parts forms clots of some size. The adrenal is thus increased in weight to 22·4 grammes, and its thickness is mostly affected. It is from a female lunatic, 13,421, who died February, 1899, aged 47, after acute melancholia of two and a half years. She had no symptoms

Digitized by Google

suggesting a lesion of this body. Having become greatly impaired in health, a few days before death she passed into a collapsed state, weak and slow pulse, shallow breathing, cold extremities, and expression of great illness, and she gradually sank. There were no other morbid changes in the body ; blood-vessels were healthy. The left adrenal was normal.

The supra-renal bodies have not been examined in the asylum with any regularity, but I have several times seen slight hæmorrhage in the organ, though nothing like so extensive as in the present instance. There are several other cases recorded in the autopsy books, of which the following may be mentioned.

Female, 9497, died in 1886, aged 25. The subject of acute melancholia of three months' duration, wishing to die, constantly crying, and had to be forcibly fed. There was emaciation, which rapidly increased with great prostration, seized with faintness, and died soon after. The right capsule was much enlarged with blood extravasation, the left to a less extent. All organs much congested, pneumonic consolidation of lower lobe of right lung, with recent lymph on pleura.

Male, 10,411, died in 1888, aged 23, having mania of six weeks' duration, confused, rambling, hallucinations of sight and hearing, destructive to clothing. He was pale, thin, and admitted in a collapsed state, and died within two hours. Breathing slow, heart's action feeble, and extremities cold. Face of a pale yellow tint. Eyes directed towards the left, limbs helpless, temperature subnormal; Cheyne-Stokes respiration lasted for two minutes. Both supra-renals enlarged with blood extravasation. Decolourised blood clot almost filling right ventricle of heart, similar small clot in left; granulations on ventricular surface of aortic cusps.

Male, 11,026, died in 1890, aged 63. The subject of acute mania of three months' duration, having wandering, extravagant delusions, noisy and restless. He had a dissipated appearance, and was fairly nourished. Died from exhaustion. Both supra-renals enlarged with blood-clot.

Male, 11,106, died in 1890, aged 44. The subject of mania of ten months' duration, the cause of which was assigned to drink and overwork. Expression vacant, noisy, singing incoherently, making grimaces and gesticulations, faulty habits, knee-jerks exaggerated. He was thought to be a case of general paralysis, and had had a fit some months before, followed by numbness on the right side,

Digitized by Google

and great pain in the top of his head. Fairly nourished, eyes prominent, but pupils equal. A fading papular eruption on trunk. Died from exhaustive diarrhœa. Hæmorrhage into one supra-renal capsule was found.

Neither of the preceding cases had any signs of Addison's disease, but there were some symptoms which might suggest internal hæmorrhage in an ordinary individual, though in the insane little importance can be attached to those, for almost identical symptoms may be present without any hæmorrhage being found after death.

It has often appeared to me that the supra-renal body is particularly liable to undergo atrophy, with, it may be, inflammatory changes in the insane, but my observations have been few. I regret to acknowledge that the condition of these glands has received but scant attention on my part. Now and again, however, I have found them markedly atrophied. They are then usually small and unnaturally soft, and it seems as though slight blood extravasation has taken place. Sometimes there is an early inflammatory condition present. In a few of these organs that I have submitted to microscopical examination small collections of round inflammatory cells were present amongst the epithelial cells. There has been nothing to point to such a lesion during life. The specimen of which a section is shown under the microscope is such an instance.

Male, 11,710, died with general paralysis of two and a half years' duration in 1894, aged 48. He had delusions of wealth and position, speech blurred, tongue tremulous, gait ataxic, knee-jerks exaggerated. After a severe seizure became feeble and paralysed. To the naked eye the gland had a soft, dark, atrophied appearance. In microscopical sections there are seen small collections of round inflammatory cells between the columns of epithelial cells of the cortex, and also around vascular spaces in the medullary portion. In places are extravasated red blood-discs.

One case of cyst of the supra-renal is recorded, but no details are given of the lesion. Male, 9228, who died in 1885, aged 38, from general paralysis of three and a half years' duration. Of vacant expression and eccentric behaviour, delusions that his flesh was dropping off, his heart had ceased to beat, and his bowels occluded. Hesitating speech, ataxic gait, exaggerated knee-jerks. Died demented. Of unhealthy complexion, and looked more than

Digitized by Google

his years; had sore on his foot for five years, developed necrosis of several toes, and passed into a very feeble state.

The number of instances of Addison's disease in Colney Hatch Asylum have been few. I have only found four instances in the autopsy books, though possibly others occurred. The majority of the symptoms as a rule are more or less masked in the insane, but the characteristic change of colour in the skin is usually well marked.

Male, 6167, who died in 1875, aged 58, with mental symptoms of dementia of three and a half months' duration, brought on, it was supposed, by alcoholic indulgence. Complete loss of memory, incapable of giving an intelligent answer, died after epileptiform convulsions. Haggard and looking prematurely old; surface of body bronzed, more especially the chest. Supra-renals found fibrotic and partly calcified. Lungs healthy.

Female, 7365, died in 1879, aged 22, after puerperal mania of two and a half months' duration following confinement four months previously. At first noisy and restless, then vacant and refusing to speak; became listless and sat in a sleepy condition, incapable of attending to personal wants or cleanliness. Died after an epileptiform attack. Though on admission she was well nourished, she rapidly emaciated and became pale and feeble. Skin assumed a dark and bronzed colour. Both supra-renals of large size and tough, but otherwise of "normal appearance." Lungs riddled with tubercular abscesses from a nut to a walnut in size, and much pigmented fibrous tissue.

Female, 9412, died in 1887, aged 35. A Jewess, with recurrent melancholia of three years' total duration, depressed and despondding, talked to herself and to imaginary persons, and wished to die. It was difficult to get her to eat anything but dry bread. At first in fair health, but purpuric patches appeared on the legs. Had attacks of melæna, began to lose weight and become feeble. Died from phthisis, the lungs being filled with abscesses and disseminated yellow tubercles. Left iliac vein thrombosed. Supra-renals large and gritty on section.

Female, 12,147, died 1894, aged 57. Acute melancholia of three months' duration. In great terror with optical delusions and aural hallucinations. In a feeble condition on admission, and rapidly emaciated; pigmentation of skin, especially around eyes and nipples, and other symptoms of Addison's disease present.

Digitized by Google

Supra-renals enlarged and caseous. Lungs and other organs said to be normal.

Whether in years gone by cases have passed unrecorded I cannot say, but this is doubtful, seeing that the last-mentioned one is the only case of Addison's that has occurred amongst the patients during the eight years that have immediately passed. In 1893, however, a nurse died in the asylum with all the typical symptoms of Addison's disease. Both supra-renals were affected. They were much enlarged, fibrous and caseous in places, and containing calcareous particles. A section under the microscope shows the usual condition of the gland in that disease. The normal cells are replaced by fibrous tissue in a state of hyaline degeneration, and patches of caseous matter seen as granular and structureless areas. In parts where the degeneration is less advanced there may be seen giant-cells having the character of those of tuberculosis embedded in a round-celled inflammatory tissue. The neighbouring fat is in the condition usual to chronic inflammation of adipose tissue. There was no tubercle elsewhere in the body.

A small benign tumour of the adrenal was published in 'Path. Trans.,' vol. xlix. Few cases of malignant disease involving the organ, whether primary or secondary, are on record. None of these presented the pigmentation of the skin peculiar to Addison's disease. In addition to the case recorded on p. 239 of the present volume, in which the supra-renals are affected by round-celled sarcoma, there are the following:

Female, 4971, died in 1885, aged 35, being of Jewish birth, and the subject of epileptic imbecility for over twenty-six years, during which time, however, she had been out of asylum for some twelve years earning her living as a charwoman. Hands small and undeveloped, of weak intelligence, violent at times and had occasional fits. She was well nourished and in good health until the last year of life, when she became thin and developed signs of phthisis, having cough and hectic temperature, but no expectoration, the latter symptom being frequently absent in the insane. Her complexion assumed a sallow tint, the face slightly brownish. The liver was full of round, globular swellings, soft on section, with depressed peritoneal surface. Abdominal glands large and hard. Right supra-renal, the size of a small orange but preserving its original shape, was full of the same masses as the liver. The

Digitized by Google

left lung is said to have contained tubercle; pleura thickened and covered by lymph. Right lung congested, œdematous; bronchi dilated.

Male, 11,182, died in 1896, aged 67. Recurrent mania with attacks extending over forty-seven years, assigned to alcoholism. Final attack lasting five and three-quarter years, during which he was incoherent, despondent, fancied he was rotting and full of poison. A dissipated, broken-down looking man, became very feeble, and suffered from chronic bronchitis and asthma. A few weeks before death indications of mediastinal malignant disease developed, with growth extending above the right clavicle, and enlarged glands above the left. Attached to the right kidney was a malignant growth as big as an orange, involving the supra-renal body, in parts very hard, in others soft and disintegrating. The whole of lower lobe of right lung was breaking down and purulent, pleural cavity filled with fluid. Enlarged glands at root of lung pressing on right bronchus and superior vena cava.

In neither of the above cases were the growths examined microscopically. They bear a great resemblance to the case I show to-day, and it is very possible they are of the same nature. It seems more probable that the lung of the first case was infiltrated with malignant growth, and not affected by tubercle.

April 4th, 1899.

Digitized by Google

VIII. DISEASES, ETC., OF THE SKIN.

Epithelial tumours, probably of congenital origin.

By H. Radcliffe Crocker, M.D.

(With Plate VII.)

Miss G—, aged 10, was sent to me by Sir John Williams for some growths on the forehead, and I saw her for the first time on November 16th, 1897. The parents stated that there was nothing present at birth, nor up to the age of three or four years. She had had a fall on the forehead, but the parents could not remember when the growths began in relation to the fall, or whether there was any connection at all. The first lesion was a pin's-head spot, which increased very slowly up to two years before she came, when it became more active, and again they cannot remember how large it was two years ago. Eighteen months ago she struck it with a pump handle, and it has been more active since. When I saw her there was a congeries of growths extending from a quarter of an inch above the middle of the right eyebrow up to and about an inch beyond the hair margin. The lowest, which was the oldest, was about an inch square, but with irregular outline and nodular surface, as it was evidently composed of an aggregation of tumours from a hemp-seed to a pea in size, projecting as a whole from a quarter to a third of an inch above the surrounding skin. It was soft to the touch, pale red in colour, with a few vessels over it, not tender or painful, but there was slight itching sometimes. Above this main growth, smaller single tumours from a pin's head to a hemp-seed in size went in vertical lines up to the hair. Just within the hair border was a large tumour about the size of a large bean. This one the parents said was growing actively; there was a pea-sized one above that. The tumours as a whole formed a vertical band about an inch wide between the brow and the hair. There was nothing abnormal in

Digitized by Google

Digitized by Google

DESCRIPTION OF PLATE VII,

Illustrating Dr. Radcliffe Crocker's case of Epithelial Tumours, probably of Congenital Origin. (Page 220.)

FIG. 1.—Showing tumour substance continuous with sweat duct. (Obj. 1 in., oc. 1.)

FIG. 2.—Showing the hair-follicle merging into the tumour substance in the deep part of the corium.

FIG. 3.—Section of blood-vessel in the midst of tumour substance. The section also shows the structure of a lobule of the tumour.

FIG. 4.—Cavities in the tumour substance with fragments of hair in them.

FIG. 5.—Rudimentary hair-follicle and ? sebaceous gland showing early change in the hair-follicle into tumour structure.

Digitized by Google

Digitized by Google

Digitized by Google

Digitized by Google

Digitized by Google

the general health, nor noteworthy in the family history. I was unable to form any opinion as to the nature of the tumours, but as they were obvious neoplasms, and not likely to yield to external or internal medication, excision of the two largest was recommended and carried out on the 18th, and on the 29th the wounds had healed by primary union with linear scars. The remaining small tumours had also flattened down considerably.

I have to-day heard from the family doctor that there has been no recurrence at the site of the lower tumour, but that close to the hair there is a nodule the size of two split peas, which is increasing in size.

Microscopical examination with a low power showed that the new growth was almost entirely situated in the deep portion of the corium, and that it consisted of a congeries of gland-like lobules more or less completely separated by fibro-nucleated septa. There were also solitary nodules, sometimes above, but more often below the main masses of neoplasm, but never below the level of the sweat coils (Plate VII), fig. 1. With a higher power the individual lobules were seen to be made up of small epithelial cells, an outer row of elongated cells, and within roundish or irregular smaller cells, not very densely crowded; in short, just the type of structure one sees in a rodent ulcer (fig. 3). The epidermis was unaltered.

In the papillary layer also the changes were insignificant, viz. slight mitotic infiltration rather more marked near the main growth, and round the vessels; changes could also be sometimes seen in the portions of hair-follicles and sweat ducts which traversed this portion of the cutis, of the same character as those deeper down.

The sweat coils were doubtfully involved. It was common to find the new growth going close up to the sweat coils, the latter appearing to be quite normal. At the same time there were isolated portions of the neoplasm of which the general conformation and position suggested their origin in a sweat coil, but intermediate conditions I was unable to discover. As regards the sweat ducts the matter was on a different footing. There a transition from the normal duct into the tumour transformation structure could be clearly traced, the duct widening out, its boundary cells forming those of the lobule boundary, and the interior being filled with the small epithelial cells already described (fig. 1).

Digitized by Google

The hair-follicles were largely involved, and different stages could be traced in different sections; in fact, the largest masses of the growth were round the hair-follicles, and in many places could be shown to be from the hair-follicle itself (figs. 2 and 5). There were also cyst-like cavities in the midst of the tumour substance, which cavities contained portions of hairs (fig. 4). The part played by the sebaceous glands I was unable to determine. There were only rudimentary sebaceous glands, and those few and far between. What there were appeared healthy, except that there was no fatty degeneration. Their absence perhaps suggests that they may have metamorphosed into the neoplastic structure, but there was no anatomical proof of it as there was in the hair-follicles and sweat ducts. In one section I found a rudimentary hair-follicle undergoing the neoplastic change at the root end, and two processes in the position of sebaceous glands, but not exhibiting sebaceous structure (fig. 5).

Blood-vessels.—Transverse sections of blood-vessels could be seen in many of the lobules, the new growth involving the outer coat, but not the muscular, which was only thickened, nor the intima. These vessels often formed the centre of a system of lobules (fig. 3).

Looking at the malignant microscopical appearance and the clinically benign nature of the tumours, and the imperfect development of the hair-follicles and sebaceous glands, it seems most probable that the tumours owe their origin to some embryonic defect in the development of the appendages of the skin, and probably a slight injury determined their growth in this unusual direction.

I am not aware of the record of tumours with these clinical and microscopical characters, but shall be very glad if any members of the Society can give me references to any such case. This one illustrates well the fact that while the microscope is often necessary to elucidate the clinical appearances, the interpretation of the minute anatomical features is very likely to be erroneous unless the clinical history is known.

March 21st, 1899.

Digitized by Google

IX. MORBID GROWTHS.

1. *Fibroma (congenital) from the neck of a child aged one year and eight months.* (*Card specimen.*)

By H. A. Lediard, M.D.

The mother stated that the tumour at birth was the size of a pea, and continued to grow slowly until January or February of this year, when it began to increase rapidly in size, and caused cough, hoarseness, and difficulty in swallowing.

In the course of removal the tumour was found to lie high up on the right side of the neck and somewhat beneath the right ear, and behind but superficial to the sterno-mastoid muscle. The portion of the sterno-mastoid muscle subjacent to the tumour was somewhat wasted from pressure.

The tumour is about the size of a Tangerine orange, and is five inches in circumference. In structure it presents the characters of a pure fibroma, that is dense, fully formed fibrous tissue. No indication was present of any relation to muscle or nerve, and the tumour probably originated in fascia. The child made an easy recovery. *May 16th*, 1899.

---

2. *Adenoma of breast associated with cyst and calcareous degeneration.* (*Card specimen.*)

By Cecil F. Beadles.

Left breast removed from a woman aged 60, under the impression she was suffering from malignant disease.

Thirty years ago the patient had milk abscesses in both breasts

Digitized by Google

after her first child, followed by scarlet fever fourteen days after her confinement. Both breasts were lanced, the left one both to the right and left of the nipple. She had a second child two years later. A lump was first observed six years ago, projecting above the level of the skin to the right of the left nipple; this disappeared three years later, and then seemed to come and go until twelve months ago, since which it has remained and gradually increased in size. There was occasional lancinating pain, but no further discomfort. She was of a gouty nature, and subject to eczema.

The tumour while under observation varied in size and consistency, and when softer marked induration was felt around. It was diagnosed as a cyst, but was believed to be undergoing malignant development on account of the induration, attachment to the skin and tension on the nipple, and from the presence of a hard nodule to the inner side of the breast, which appeared during the last four months. No glands were felt in the axilla either before or during the operation.

The presence of a cyst was confirmed on incision into the parts removed, and this is associated with a small solid growth having some unusual characters. The cyst has a thick wall, and contained clear watery fluid of a slightly brownish-yellow tint. It is situated in the lower part of the breast, resting on the pectoral muscle, and is the size of a small hen's egg. Situated immediately behind the nipple is a small, roundish, distinctly limited tumour, about three quarters of an inch in its longest diameter; it is solid, fairly firm, white on section, and is surrounded by a distinct capsule that has become separated in parts by a blood-clot. More than half of the growth protrudes into the upper part of the cyst cavity, where it forms a white nodulated mass. It has attachments to the nipple by fibrous bands, which have caused retraction of that structure. The naked-eye appearance is that of a soft adenoma in which glandular elements are mainly represented.

The hard nodule to the inner side of the nipple, already referred to, is found to be an irregular calcareous mass the size of an almond, that lies embedded in the superficial part of atrophied breast tissue close beneath the skin. Very little mammary tissue exists; it is atrophied and replaced by fat.

Embedded amongst the fat in the outer region of the breast and that extending towards the axilla are several enlarged lymphatic

Digitized by Google

glands. They are soft, and section does not show cancerous infection, but a condition of fatty degeneration. The fat immediately around these glands is firmer than that elsewhere, and on one side protrudes into the gland; one of these glands was found beneath the edge of the pectoral muscle midway between the nipple and axilla. Examined microscopically the glands are in a condition of chronic inflammation, with partial replacement of the lymphoid tissue by fat cells; the surrounding fat is indurated by fibrous tissue. No trace of malignant cells can be detected. This condition of fatty degeneration of lymphatic glands is not uncommon in chronic inflammatory diseases and wasting of the breast. I have also found it in some cases of malignant disease, and have described it elsewhere. It has also been referred to by Mr. Stiles.

The microscopical structure of the tumour projecting into the cyst is that of certain forms of adenoma of the mammary gland, viz. one of the rarer forms of true adenoma. There is a fine stroma of connective tissue forming roundish spaces and clefts, which are mostly lined by a single layer of cubical or columnar epithelial cells. A few have much elongated cells, and some are filled with epithelium. In parts the alveolar spaces are crammed with the remains of degenerated epithelium. A thick capsule of fibrous tissue surrounds the growth.

I am indebted to Dr. Charles Heaton, of Westgate, for the specimen, which is placed in University College Museum.

May 2nd, 1899.

---

3. *Cystic disease of the breast in a boy aged three years.*

By D'Arcy Power.

I do not know how rare cystic disease of the breast may be in children, but I have never seen one before, and I think therefore it is worth while to exhibit this specimen this evening, and the more so as it is the breast of a boy.

The breast with the surrounding tissue weighs just over an ounce after it has been hardened in formalin and alcohol, and it

Digitized by Google

measures two and a half inches in length and breadth. The skin and nipple are absolutely healthy, the bulk of the swelling lying just below the nipple in the lower half of the organ. The section of the breast shows that a thick layer of fat is interposed between the skin and the pectoral fascia. The superficial portion of the fat is natural and of the usual consistency; the deeper portion is more loose, and contains numerous thin-walled cysts. The largest cyst is multilocular and roughly oval in shape. It measures after hardening an inch and a half in its long diameter, and one inch in depth. It has a definite but thin wall, bounded superficially by the subcutaneous fat, which is dimpled in every direction in its neighbourhood; the deep surface of the cyst lay upon the pectoral fascia. The inner side of the breast is free from cysts, but on the outer side there are many cysts, each with a thin but definite capsule. The smaller cysts are less loculated than the larger ones; all are filled with a clear yellow fluid.

The patient was a healthy-looking boy aged 3 years, who was brought to the Victoria Hospital for Children on December 22nd, 1898. He had always enjoyed good health, but eighteen months ago his mother noticed that the left breast was fuller than the right, and it had since slowly increased in size. The swelling had not been painful, nor had there been any discharge from the nipple.

On examination a soft rounded tumour could be felt in the left breast. It was about the size of half a Tangerine orange; it was cystic and adherent to the skin. The nipple was normal; there was no definite edge to the tumour, and it was not tender. The axillary glands were not enlarged.

The breast was removed by an elliptical incision made so obliquely across the tumour as to include the nipple, and extending to the anterior border of the axilla. The tissues were then dissected away down to and including the pectoral fascia. There was very little bleeding, but even when the incisions were carried widely upon each side of the tumour many small cysts were cut into as they lay in the surrounding connective tissue. The wound had healed by first intention upon the tenth day.

I suppose that this tumour would be classified as a case of sero-cystic disease of the breast, though there can be but little doubt that it is not a cystic tumour in the sense in which the term is applied to tumours of the adult female breast. It must be looked

Digitized by Google

upon rather as a cystic lymphangioma occurring in the connective tissue lying between the breast and the pectoral fascia, and it is thus comparable with the congenital cystic tumours found in other parts of the body in children, especially in the neck, where they have long been known as hygromata. Recognising this fact, I should have been content to leave the tumour alone if the patient had been a girl, trusting in the hope that the functional changes taking place in her life might lead to its disappearance. But in this boy I had no hesitation in removing the breast, because the gland is functionless throughout life, and because its spontaneous disappearance, if it occurred at all, would necessarily be slow, whilst the mutilation performed at so early an age would become almost imperceptible as the patient grew older.

The specimen is preserved in the museum of St. Bartholomew's Hospital, No. 3142. *April 4th*, 1899.

---

4. *"Butter" cyst of the breast.*

By H. Betham Robinson, M.S.

Mary P—, married, aged 25, came under my care in St. Thomas's Hospital in October, 1897, giving the following history.

Fifteen months before, three weeks after her first confinement, she suffered from an abscess of the right breast in almost the same situation as the present swelling. The breast became large, painful, and tender, especially at the upper and outer part. The inflammatory mass was punctured twice, not incised, and a considerable quantity of pus (?) was drawn off.

Soon after the abscess had apparently healed she began to notice a small lump about the centre of the right breast. This quickly reached its present size, about that of a Tangerine orange, and has remained so since, having shown no sign of enlargement. There has been very rarely any pain in connection with it, and no discharge from the nipple.

On admission the lump, which was circular in outline and about

Digitized by Google

two inches in diameter, was situated above the nipple, and showed at its inner part the scars of the two punctures. It was very elastic, and moved with the breast over the subjacent pectoral. The skin was free over it without any puckering; there was no retraction of the nipple and no tenderness on pressure. One gland on the inner wall of the axilla was distinctly enlarged.

The lump, with a margin of healthy gland structure round, was removed, as well as the enlarged gland.

The swelling proved to be a cyst with smooth walls, filled with a yellowish-brown semi-solid substance of the consistence of butter. On histological examination of the cyst wall there were gland lobules to be seen embedded in some excess of fibrous tissue; the lining membrane was epithelial, flattened, and chiefly in a single layer, and not granulation tissue.

The cyst contents hardened on exposure to the air. With ether the main part, fatty, was soluble; the undissolved part showed microscopically protoplasmic masses, fatty epithelial cells without leucocytes, and also sheaves of circular crystals, probably stearine.

The cyst, which arose after acute inflammation of a physiologically active gland, was evidently due to one of two causes, a chronic abscess or the retention of secretion. The microscopical appearance of the cyst wall and the analysis of the contained fluid quite dispose of the former view. The cyst was a galactocele, but modified to this extent, that the watery constituents had become absorbed, leaving only the more solid parts behind.

Modifications of galactoceles, although rare, have been duly recorded. Velpeau [1] says their contents may be partially coagulated, the watery part being absorbed, giving rise to a cream-like fluid. Billroth speaks of changes in the contents like those shown under the name of oily, buttery, or cheesy cysts. Such retained products might become quite hard, dry, and friable, resembling old cheese. Such a specimen was shown by Mr. Watkins Pitchford at this Society.[2] In his case the milk had been retained in dilatations associated with fibroid changes in the breast, and had gradually lost all its watery elements. The "cheesy" material was proved to be almost entirely fatty. *October 18th*, 1898.

[1] 'Diseases of Breast,' New Sydenham Society, p. 241.

[2] Vol. xlvii, p. 250.

Digitized by Google

5. *A peculiar lipoma of the groin.* (*Card specimen.*)

By Cecil F. Beadles.

A photograph was shown of a lipoma of the right groin, peculiar both in form and situation. It hangs as a loose pendulous tumour, not quite as large as one's closed fist, at the upper and inner part of the thigh, having a wide base extending from the femoral ring to the root of the penis.

It bears a singular resemblance to the scrotum; it is but little larger in size, the skin is of the same loose puckered form, of a similar tint, and pubic hairs are continued over the base of the tumour. The likeness is increased by the feeling through the skin of a hard cord-like body running through the centre, and ending below in a small mass rather firmer than the remaining contents of the tumour. There is no dimpling of the skin obtainable, as is usual in lipomata. The scrotum is natural, and contains two testes.

An incision made into the tumour reveals only loosely lobulated fat, of a paler tint than that on the parietes. The hard cord referred to above is found to be a band of connective tissue, and the swelling below evidently a lobule of fat. There is no cavity within, and no hernial protrusion into the tumour; dissection proves the connections of the lipoma to be superficial to and entirely unconnected with the inguinal canal.

It occurred in a man aged 78, who lately died in Colney Hatch Asylum with senile dementia of a few years' duration. So far as could be found out, he had had the tumour all his life, and it had only enlarged with the gradual growth of the body.

April 4th, 1899.

---

6. *Large myxoma from the thigh.* (*Card specimen.*)

By H. D. Rolleston, M.D.

This tumour was removed from a woman 60 years of age by Mr. Bennett in St. George's Hospital. It had been growing for about six years and burrowed between the muscles in the upper

Digitized by Google

part of the thigh, but did not infiltrate the surrounding tissues; it came away in many pieces, which were all encapsuled. The deeper part appeared to be connected with the linea aspera of the femur. The tumour probably arose from the intermuscular fascia. When collected and weighed it was 10 lbs. 15 oz., but it was heavier than this, for a good deal of fluid had by this time escaped from it. On section the tumour was glistening, and contained a number of cystic spaces with fluid in them.

Microscopically it was a myxoma; no cartilage or sarcomatous tissue was found in sections taken from various parts of the tumour. In its size and diffuseness it resembled a large but innocent cartilaginous tumour arising from the pelvis removed by my colleague, Mr. G. R. Turner, six years ago in St. George's Hospital. *March 7th*, 1899.

---

7. *Cysts in relation with an inguinal hernial sac in a woman.*

By H. Betham Robinson, M.S.

Annie P—, aged 23, single, was operated on by me in St. Thomas's Hospital on June 16th, 1897. She had been admitted in May with a strangulated left inguinal hernia, which was operated on and radically treated with complete success; it was then noticed that she had also a right inguinal hernia. This hernia was small and easily reducible, extending as far as the pubic spine, but after reduction there remained a fulness suggesting thickening of the sac wall.

At the operation an incision was made from internal ring to pubic spine, and on opening the sac gut was present and reduced. The lower end of the inner wall of the sac bulged into the cavity, and a prominent cyst was opened containing a brownish fluid; into the wall of this one other smaller cyst projected. The sac was dissected up to the internal ring with the round ligament and the cystic swelling, and the radical cure completed.

The cystic swelling proved to be made up of a number of varying sized cysts containing a dirty brownish fluid; these were entirely retro-peritoneal, surrounding the round ligament.

Digitized by Google

Now as to the nature of these cysts, there is very little information to be gained from surgical or pathological writings. Erichsen speaks of "cystic tumours not unfrequently met with in the labia resembling inguinal hernia, but incompressible and irreducible, without impulse or coughing, and containing a dark turbid sanguineous fluid." There is no mention, however, of any associated hernia. I would suspect that possibly these cysts, which rather resemble my case clinically, have the same pathological explanation.

To explain the nature of these cysts I think we can give a developmental reason, which is that we have here an homologous condition to what has been described by Lockwood in the male in vol. xlvii of the 'Transactions,' only in his case the cysts projecting into the sac were pedunculated. In his paper he suggests that the origin of the cysts was from remnants of the Wolffian body situated in the cord retro-peritoneally. It does not seem extravagant to suppose that some of the cellular columns of the Wolffian body may in the female be displaced and be dragged down into the canal with the descent of the canal of Nuck, for the frequent presence of the ovary in the hernial sac shows that in the female these retro-peritoneal structures can without difficulty pass into the inguinal region.

Other views as to its nature would be that it is analogous to certain cysts that may be met with in relation with herniæ, especially femoral, and possibly due to pathological adhesion of the serous layers, but the numbers and variation in size of the cysts are against this view. Then, again, we might consider whether it bears any relationship to cystic hygromata, which, although not uncommon in the groin below Poupart's ligament, have never, as far as I know, been described in the inguinal canal; but a weighty argument against this view is that the cystic swelling was a cord-structure pure and simple, and dissected away easily in its entirety with the round ligament and its peritoneal process. Lastly, there was no evidence and no history of any preceding nævoid formation to give rise to this by cystic degenerative change. To conclude, then, I would urge that there is no explanation more feasible than the first one I propounded. *January 17th*, 1899.

Digitized by Google

8. *Multiple abdominal dermoids.*

By A. C. LATHAM, M.B.

Two specimens of multiple abdominal dermoids are shown, one a dermoid of the right ovary, the other a dermoid in connection with the stomach. Both these specimens were removed from the body of a woman who had died from acute general peritonitis, set up by suppuration and perforation of the ovarian dermoid. There were also numerous other small dermoids in connection with the stomach, the descending colon, and the supra-renals. Nothing abnormal was found in the structure of the walls of these cysts, and no nerve-cells were observed. This condition is very rare, and extremely few cases of multiple dermoids had been recorded. Kolaczek, Fraenkel, and Hulke have each described a somewhat similar case.

In discussing the nature of the above case, and considering whether such a condition should be regarded as being of a malignant character, reference may appropriately be made to a case recorded by Montgomery of a teratoma in which the author considered that the recurrence of the growth showed a malignant nature. But in the case shown to-night the weight of evidence points to the generalisation of the abdominal dermoid cysts as being due to cell transplantation, and not to malignancy as generally understood.

November 15*th*, 1898.

---

9. *Myeloid tumour of neck.*

By H. J. WARING, M.S.

This tumour was removed from a man aged 60, one who came under observation on account of a swelling in the left side of the neck. For at least forty-five years previously he had had a small tumour over the anterior border of the left sterno-mastoid muscle, and about one inch above the sternal extremity of the

Digitized by Google

clavicle. This remained about the same size until about one month before admission to the hospital, when it became painful and commenced to grow rapidly.

When first seen there was a swelling, the size of a large walnut, in the lower part of the left side of the neck and over the anterior border of the sterno-mastoid muscle. The tumour was quite superficial, and appeared to be situated in the superficial fascia. It could be moved freely over the underlying deep fascia and muscle. The skin over it was bluish in colour, somewhat pigmented, and contained a number of dilated veins. The swelling could be lifted up, and the fingers made to almost meet behind it. It appeared to be quite solid and of uniform consistence. The lymphatic glands in the neighbourhood were not enlarged.

The tumour was removed, when it seemed to be closely connected with the platysma. On section it proved to be of firm white consistence, and encapsuled as regards the posterior portion. Anteriorly it was attached to the deep aspect of the skin. There was no attachment of the tumour to the underlying deep fascia or muscles. On microscopical examination, the main portion of the tumour is seen to consist of a basis of fibrous tissue which contains numerous very large myeloid cells, each having in its interior numerous nuclei, and also a number of oval-celled sarcomatous elements. In a few places islands of hyaline cartilage are visible. The tumour evidently is a fibro-sarcoma containing cartilage and myeloid cells.

Myeloid sarcomata are very unusual in the superficial tissues; they occur most commonly in connection with bones.

As regards the origin of this tumour there appear to be three possible explanations:

1. The small tumour which had preceded the larger one may have been the remains of a branchial cleft, and in this there may have been bone and cartilage from which the tumour took its origin. This is the most probable explanation of the myeloid character of the tumour.

2. A small portion of the sternal extremity of the clavicle may have been separated from the rest and displaced upwards. It then remained quiescent until from some cause active growth commenced, and gave rise to the formation of the tumour which was removed. In favour of this explanation is the fact that the tumour was situated entirely in the superficial fascia, and that it had no connection with the deeper tissues.

Digitized by Google

3. The small tumour which had existed for so long in the neck might conceivably have been a small dermoid cyst, and in the walls of this the myeloid growth commenced. Against this, however, is the fact that the tumour is quite solid, shows no trace of a cavity in its interior, and it does not contain any traces of bone or hairs in any part of it.

As regards the malignancy of the tumour, this appears to be more marked than is usually the case with myeloid tumours. The tumour was removed with the surrounding tissues four months ago by Mr. Willett in St. Bartholomew's Hospital. Last week the patient returned with a distinct local recurrence of the growth.

May 2nd, 1899.

---

10. *A case of multiple fibro-sarcomata of the scalp of nineteen years' duration; removal of growths; subsequent recurrence in lungs.*

By PHILIP R. W. DE SANTI, F.R.C.S.Eng.

LYDIA L—, aged 20, single, was admitted under me at Westminster Hospital in August, 1897, with multiple tumours of the right scalp.

History of case.—The patient stated she had had swellings on the right side of the head as long as she could remember. Her mother informed me she first noticed the tumours when the girl was one year old. They came gradually, caused occasional neuralgic pain, and some of them slowly increased in size whilst others remained stationary. At no time was any spontaneous disappearance ("withering sarcoma") noticed. The mother of the patient was an out-patient of mine with a gumma of the upper eyelid and other tertiary manifestations, but the daughter presented no signs, past or present, of congenital syphilis.

The girl had been an in-patient in 1891, when one of several tumours of the scalp was removed: microscopically it was a fibro-sarcoma. She was again admitted in 1896. The note made then was "A large fluctuating swelling and several smaller ones on the right side of the head; two of the growths were removed and said

Digitized by Google

to be fibrous lymphomata; there was much hæmorrhage, which was stopped with Paquelin's cautery. Microscopically the growth was a fibro-sarcoma.

Just prior to her third admission under me she had noticed an increase in the size and number of the tumours and more pain.

Her state was as follows:—a very loose condition of all the skin of the scalp on the right side, extending from the occiput to the external angle of the right eye, and from the sagittal suture to the lobule of the ear. Under this loose skin could be felt a very large number of hard nodular masses, some large, others quite small. They were freely moveable over the subjacent parts and under the skin. At places between the hard masses were soft, almost fluctuating areas. These areas were painful to the touch. There were no enlarged glands, and the patient's general health was good. There was nothing discoverable in the lungs, liver, or other organs.

She had had prolonged treatment at various times with arsenic, iodide of potassium, &c., but with no benefit.

I determined to make an attempt to remove all the tumours; my one trouble was likely to be hæmorrhage.

On September 8th I made two incisions: one in front of the ear, extending vertically from close to the sagittal suture to about one inch below the zygoma; another about the same length posterior to the ear, with a slight concavity forwards. The skin was then raised off the nodular masses, which were removed in all directions as far as they could be reached, the part below the zygoma especially being cleared out. The greater part of the temporal muscle had to be removed to do this thoroughly. A third incision was then made, connected at either end with the second, so as to remove an oval piece of skin which was redundant (*vide* specimen). The wound was then closed with horsehair sutures. There was, during the operation, considerable hæmorrhage, and as the patient became very faint I had to leave three or four nodules at the upper and under part of the sterno-mastoid muscle.

She made an uninterrupted recovery, and was sent to a convalescent home September 24th.

In the specimen handed round can be seen a large number of the tumours removed.

I subsequently heard from the medical superintendent of the Camberwell Infirmary that the girl was an in-patient there, with

Digitized by Google

obscure lung mischief suggestive of either phthisis or new growths in the lungs.

She died about six months after the operation, and at the autopsy there was very extensive secondary infection of the lungs. The left lung weighed 8¼ lbs., was almost entirely solid, and had fungated through the diaphragm.

The right lung was the seat of one large growth, and generally dotted with small growths. The pleuræ were also affected, the right principally, the surfaces of the ribs and diaphragm being studded with growths. There were no growths in the other viscera or bones.

I have to thank Miss Webb, the curator of the Royal Free Hospital Museum, for the loan of the specimens of the lungs.

I have here to-night, therefore, the following specimens:

Macroscopic.—(*a*) A number of the tumours as they were removed at the time of operation; these will be seen to be definite encapsuled growths of varying sizes and density. (*b*) A piece of scalp excised, showing some of the growths loosely attached. (*c*) The left lung. (*d*) The right lung.

Microscopic.—(1) Section of a piece of the growth removed in 1891 (Dr. Hebb). It shows masses of round-cells enclosed in dense fibrous-tissue bands.

(2 and 3) Sections of tough and soft parts of one of the growths removed in 1897. In both these sections fibrous tissue predominates, and the general appearances are more those of fibroma than sarcoma.

I think the case is interesting from many points of view:

First, the rarity of the scalp as a primary seat of the growths. Primary sarcoma of the scalp is uncommon, and I have been unable to find records of quite a similar case to mine. The only one at all like it is recorded by Dr. Conner, of Cincinnati, in the 'Annals of Surgery,' 1888.

His patient was a woman of twenty-five, who, fifteen years before consulting him, discovered at the back of her head a small hard lump the size of a bean. It remained stationary for about thirteen years, then enlarged coincidently with a pregnancy. After delivery there was rapid enlargement, and when seen by Dr. Conner the tumour was the size of a second head. It was removed, and weighed almost 5 lbs., and microscopically was a spindle-celled sarcoma. There was eighteen months' immunity, then coincidently

Digitized by Google

with another pregnancy there was a local recurrence. After confinement the growth was removed, and weighed 7 lbs., and proved to be a mixed spindle- and round-celled sarcoma.

Secondly, the very definite history of the duration and gradual increase of the tumours, namely, nineteen years.

At no time whilst under observation by the surgeons who saw her during six years was there any disappearance of the tumours, as in the "withering sarcoma" case of the late Mr. Morrant Baker and Dr. Morgan Dockrell.

Thirdly, the death of the patient after extensive removal of the growth from secondary involvement of the lungs.

Fourthly, the varying microscopic appearances of the growths.

The deduction in my opinion to be drawn from such cases is that no hard indolent lump or lumps should be allowed to remain, though even for years in an unchanging and unchanged condition, but should be freely removed; for though probably benign to start with, in the future they become malignant, and finally kill by secondary infection and exhaustion. *October 18th*, 1898.

---

11. *A case of melanotic sarcoma with secondary growths of unusual size in the small intestine.* (*Card specimen.*)

By H. CAMPBELL THOMSON, M.D.

THE patient in this case was a man aged 49. He was a painter, had suffered from lead colic, and seventeen years ago he had a severe illness, which was said to have been called "inflammation of the kidneys."

Three years ago he noticed a sore forming under the big toe on the right side, which gradually got larger, and he went to the London Hospital, where he was told that he had a melanotic sarcoma. There the big toe was amputated, and at the same time some glands were removed from the groin.

He remained free from symptoms for six months, and then began to rapidly lose flesh and complain of pains in the abdomen. He was admitted into the Middlesex Hospital early in 1899, under

Digitized by Google

the care of Sir Richard Douglas Powell. The chief symptoms were constant nausea, constipation, and anæmia, with pain and tenderness all over the abdomen; there was no actual vomiting, and the constipation never amounted to complete obstruction. There was a large rounded mass to be felt in the left hypochondriac region, and an examination of the blood showed a considerable degree of leucocytosis.

The patient eventually died, and the result of the *post-mortem* examination was as follows:—There was no local recurrence at the primary seat of the growth. On opening the abdomen the left lobe of the liver, together with the intestines of that neighbourhood, were much bulged forward, but no definite growth was visible. I explored this region with my hand, and felt a huge tense swelling, which, however, immediately ruptured. This proved to be a cyst situated between the folds of the small omentum, with its walls closely adherent to the under surface of the left lobe of the liver, the under surface of the diaphragm, and the anterior wall of the stomach, the adhesions to the last named being very strong. This cyst contained about two pints of very dark brown fluid; its walls were deeply pigmented, and in some parts were very thin and easily torn.

There were twenty large secondary growths in the small intestine; the smallest was about the size of a marble, while the largest was about as big as a pigeon's egg. All these were growing into the lumen of the bowel, and only showed externally as small dark depressions which gave no idea whatever of their actual appearance or size. These were entirely confined to the small intestine; the uppermost one was situated at the end of the duodenum, and the lowest one was at the ileo-cæcal valve, while they were most numerous in the upper part of the jejunum. There was a varying amount of pigmentation present, and some hæmorrhage had occurred into the substance of some of them.

There was a large deeply pigmented gland in the right groin, which on section showed cystic degeneration, and contained a dark, thick, semi-solid substance.

Another similar gland was situated at the bifurcation of the trachea, which also contained a similar substance to the last. There were no other secondary growths elsewhere.

The chief interest in the case lies in the distribution of the growths, the tendency to formation of large cysts, and the great

Digitized by Google

size which the growths attained in the small intestine. The cyst, as the specimen shows, was of great size, and had the patient lived a little longer it would undoubtedly very soon have ruptured.

With regard to the intestines, it is interesting to note, firstly, that all the nodules grew into the lumen; and secondly that, considering their number and size, they gave rise to very few symptoms.

Lastly, the general distribution of the secondary growths in this case is somewhat peculiar, for, considering the advanced stages which they have attained in the small intestine, it might have been expected that there would also be some in the liver and other organs. This, however, was not the case, and with the exception of some slight enlargement and hardening of the glands in the lumbar region there were no other signs of growth besides those mentioned above. *March 21st*, 1899.

---

12. *Round-celled sarcoma involving the region of the pancreas, the supra-renals, liver, and left lung.* (*Card specimen.*)

By Cecil F. Beadles.

Male, 12954, aged 64, was admitted into Colney Hatch Asylum on October 21st, 1898, with melancholia of seven months' duration, the cause of which was unknown. He is described as a labourer, but had been an inmate of the workhouse for some months, and while there had accused other inmates of attempting to poison him. He was admitted in impaired health, with physical signs suggesting bronchitis and emphysema of both lungs. Being very deaf, and mental faculties much impaired, it was difficult to get anything from him beyond the above delusion.

In the early part of December he went to bed with cough and general feebleness. Except for hæmorrhoids he was not known to be suffering from any disease beyond the condition of his chest. There was no rise of temperature, and he complained of no pain. There was nothing to suggest a thorough examination of the abdomen. He was fairly nourished and took food pretty well, but

Digitized by Google

he continued to get weaker, breathing more troublesome, and towards the latter part of January his feet began to swell. Urine was found to contain a trace of albumen. Mentally he grew more demented, and died January 25th.

Autopsy.—Brain somewhat wasted, pia-arachnoid membrane slightly thickened over both cerebral hemispheres, and excess of fluid in the skull. Heart a little hypertrophied, but the valves healthy; a very slight degree of atheroma of the aorta; some fluid in the pericardial cavity.

Both lungs firmly adhered to the chest wall. The right lung weighed 27 oz., and contained frothy fluid. The left lung was covered by thickened pleura; it weighed 33 oz., and was consolidated throughout. It was pervaded by dense fibrous bands and infiltrated by new growth of a whitish colour, and in parts was much pigmented. The lung was seemingly invaded from the region of the root and base, and the bronchi and vessels as they emerged were embedded in growth. From this neighbourhood a deposit protruded into the upper part of the pericardial cavity, and there were deposits in the diaphragm beneath the lung.

On opening the abdomen an entirely unsuspected condition met the eye. The anterior part of the cavity was occupied by the liver, enormously enlarged, the anterior edge reaching to the brim of the pelvis, and the organ completely covering the bowel. Its surface was a deep purple colour, scattered over with small round deposits of malignant growth, for the most part less than an inch in diameter, of pale yellowish-white tint, only slightly raised on the surface of the organ. On raising the liver there were no adhesions to the intestines, but it was firmly attached at the hinder part of the under surface of the right lobe to a mass of new growth which extended to the right kidney and over the front of the spine behind the duodenum, occupying the site of the pancreas. It was removed by cutting through the growth beneath, and was found to weigh just over 100 oz., measuring 12 inches across and a little over that length from posterior to anterior edge. The enlargement was mostly of the right lobe; posteriorly this was greatly thickened, and section revealed a malignant deposit having a diameter of over 6 inches, the central portion of which was soft and breaking down. The organ tapered away to a thin anterior margin and left edge. Throughout were various-sized deposits, both superficial and deep, varying in size from a pea to a large

Digitized by Google

horse-chestnut; the centres of the larger deposits were softening, and in some there was a cavity with a ring of firm white growth around. The gall-bladder contained bile but no gall-stones.

The kidneys, pancreas, stomach, and duodenum with the growth were removed entire, and afterwards more carefully dissected, and these are exhibited together with the left lung and portions of the liver.

The stomach is much contracted and its walls thickened, but free from growth. The duodenum, as was likewise the remainder of the intestine, is natural, and there were no deposits in the lower part of the peritoneal cavity. The spleen has been detached; it is small, weighs 4 oz., and contains no new growth. Both kidneys are diseased; there are numerous superficial cysts beneath the capsules, filled with straw-coloured fluid, and there are a number of small round infarcts in the cortical region, varying from a pin's point to the size of a pea, probably of a malignant character. The left supra-renal body is of normal size and shape, but section reveals a number of small, pale, wedge-shaped infarcts in the superficial portion. The right supra-renal body appears to be replaced by an enormous deposit of new growth partly embedded in the kidney; it is of circular form, with a diameter of 2 inches, firm and white on section, and connected anteriorly with the growth beneath the liver.

Stretching across between the kidneys and occupying the site of the pancreas is an irregular mass of new growth. It is connected on the right side with that of the liver and adrenal, and has an outlying large mass of growth, which presumably originated in lymphatic glands around the pancreas and small curvature of the stomach. Everywhere it is white and somewhat soft on section. A small portion of growth protrudes into the inferior vena cava from the right renal branch.

As for the pancreatic gland, at first it seemed probable that this was entirely replaced by new growth, and it was thought possible that the malignant disease had started in that organ. But this is evidently not the case. The pancreas has become displaced in a most remarkable manner, presumably by the growth pushing it over to the left; it has there come to lie between the stomach and the left kidney, with its long axis from above downwards. The upper portion, which is compact and firm, is in contact with and reaches above the level of the left supra-renal; the lower part is

Digitized by Google

thinned and spread out. There is no sign of new growth in this organ.

Microscopically the growth is a round-celled sarcoma. Everywhere the minute structure is the same with but slight modifications, a mass of small round cells with a fine branching reticulum without any true alveolar arrangements. Blood-vessels are practically absent.

Sections from what was at first believed to be the head of the pancreas reveal no trace of that gland, there is nothing but deeply staining small round cells; small blood extravasations occur in places. There are a few narrow connective-tissue bands, but the branching reticulum is very fine. Small growths in the liver are the same; in the larger ones the cells are necrosed. A section of the large deposit in the right supra-renal shows a more necrosed growth. There is more fibrinous stroma, but the intervening cells are all spherical in outline. A few small thin-walled blood-vessels are seen amongst the cells. The small infarcts in the left supra-renal are composed of round cells. The lung is pervaded by bands of fibrous tissue in which is much pigmentary deposit. The walls of what few air-cells remain are greatly thickened, and the cavities are filled with a pneumonic deposit; others are occupied by round cells similar to those of the new growth elsewhere in the body, and these cells infiltrate the fibrous tissue almost throughout.

As to the site of origin of the growth, this would seem to have occurred either in the right supra-renal body or in the lymphatic glands, about the base of the liver and head of the pancreas.

April 4th, 1899.

Digitized by Google

13. *A case of umbilical papilloma which showed some activity of growth in a patient fifty years of age, and which was due apparently to the inclusion of a portion of Meckel's diverticulum.*

By Charles D. Green.

The specimen consists of the umbilicus from a woman aged 50 years, which was removed by operation. Instead of the normal depressed cicatrix there is seen a solid slightly projecting growth with a warty-looking surface, and about the size of an ordinary marble.

The patient had complained of irritation about the umbilicus for about two years and a half before the operation, with an occasional discharge of a brown colour. I first saw her on account of this about fourteen months before the growth was removed; there was then some eczematous irritation of the skin in the neighbourhood of the umbilicus, but no projecting growth was at that time observed; the bottom of the umbilical depression had an irregular warty appearance, which I thought was the result of irritation; the surrounding eczema soon yielded to treatment, but there was from time to time an irritating discharge from the umbilicus, which the patient declared was always worse during her menstrual periods. Having in mind the possibility of the development of an epithelioma I suggested removal of the umbilicus. Owing, however, to the illness and subsequent death of the patient's husband the matter was postponed. In August, 1898, I was again asked to see her on account of the umbilical condition, and there was then a projecting growth. No enlarged glands could be found. I asked Mr. Ballance to see her, and he agreed with me that the growth should be removed, notwithstanding the fact that there were some grounds for anxiety as to the administration of an anæsthetic.

On September 2nd I removed the umbilicus with the growth and a portion of the surrounding skin; the abdominal walls had about 1½ inches of subcutaneous fat, the omentum was not adherent to the umbilicus, and no intestine was seen at the operation; the peritoneal surface of the abdominal wall presented nothing abnormal. The wound healed by first intention, and there has been no trouble since.

Digitized by Google

Examination of microscopical sections taken at right angles to the free surface showed that the skin surrounding the growth was normal; the free surface of the growth presented a thick covering of stratified epithelium, the superficial layers of which had undergone keratinisation; this epithelium sent down-growing processes, and in places presented the appearance of flat-topped papilla formation. No cutaneous glands could be seen.

The stroma of the growth was made up of fibrous tissue and unstriped muscle, among which, without any definite arrangement, were numerous glandular elements; some of these were very near the free surface, others more deeply placed: they were for the most part tubular glands lined by long columnar epithelium with large deeply staining nuclei situated quite close to the basement membrane; these glands were considered to be reproductions of Lieberkühn's crypts, but differed from them in their exaggerated dimensions, some of them indeed being so large that they might almost have been described as cysts. Some of the glandular elements bore some resemblance to the mouths of pyloric glands. There were also found, but in much fewer numbers, glandular elements which were lined with a very short almost flattened epithelium, and which in a few instances contained colloid material, and looked not unlike the vesicles found in the thyroid body.

I think there can be no doubt that the growth was developed from a remnant of the vitello-intestinal tract.

Umbilical polypi of minor clinical importance, but which prevent the umbilicus from healing, are by no means uncommon in infants, and are familiar to all who have seen any considerable amount of midwifery practice. The application of a ligature or the section of the pedicle by the galvano-cautery in most instances readily effects a complete cure. A considerable number of them have been histologically examined and reported on, and they have been described under more than twelve different names; they fall, however, into two divisions, those which are merely granulation tissue more or less developed into fibrous tissue, and those which show a mucous surface and the development of intestinal glands, and are derived from remnants of the vitello-intestinal tract. The literature of the subject shows that almost every degree of persistence of the vitello-intestinal tract has been known to occur from these small umbilical polypi causing no serious symptoms to the grave cases in which most of the intestinal contents are

Digitized by Google

discharged through an umbilical fistula due to a fully patent duct, or to the prolapse of the small intestine through a patent duct.

Specimens illustrating the histology of these minor intestinal polypi are described in the 'Transactions' of this Society by Mr. Pearce Gould in vol. xxxii, and by W. S. Colman in vol. xxxix.

In 'Pedriatics' for 1897 there is a paper by Dr. J. H. de Villiers on this subject, and in vol. ii of the same journal Mr. Charles Morton, of Bristol, describes the histology of two cases. In the same journal there is also a paper by Dr. Leonard Guthrie on a case of prolapse of intestine through a patent Meckel's diverticulum.

In the 'Illustrated Medical News' for 1889, Makins and Carpenter describe in considerable detail the histology of an umbilical polypus showing intestinal gland structure.

Dr. Francis Villar, in a work entitled 'Tumeurs de l'ombilic,' published in Paris in 1886, gives a full account of all cases of these polypi published up to that date, but does not include as within the scope of his work intestinal prolapse and fæcal fistula due to the persistence of Meckel's diverticulum.

In 'Archiv für Gynäkologie,' Bd. lii, there is a description by Arndt of a most interesting case in which there was not only prolapse of intestine through a patent duct, but also a separate pedunculated tumour which he describes as an entero-teratoma.

In 'Langenbeck's Archiv' for 1895 Löwenstein gives an account of a case on which he operated with a successful result, the tumour having been cut into under the idea that it was merely a granulation tumour; prolapse of intestine took place, and it was then referred to Löwenstein. Abstracts of several other cases are given in the paper. The most important of the other papers to which I have referred are by Kolaczeck in 'Archiv für klinische Chirurgie,' 1875 (the first published paper on the subject); by Künster in 'Virchow's Archiv,' Bd. lxix; Siegfried van Heukelom in same periodical, Bd. cxi; and by Tillmans in 'Deutsche Zeitschrift für Chirurgie,' 1883; by Lannelongue and Frémont in 'Archiv générales de médecine,' 1884; a paper by W. Ophüls entitled 'Beiträge zur Kenntniss der Divertikelbildungen am Darmkanal,' published in Göttingen in 1895.

My case differs from those, the accounts of which I have read, in that the free surface of the growth was covered with stratified

Digitized by Google

epithelium, the superficial layers of which had to some extent undergone keratinisation, and was not like the mucous surface of any portion of the abdominal intestinal tract, the glandular structures being chiefly in the deeper portions of the sections, and also in the history of the case and the age of the patient, all the other cases of umbilical papillomata having presented a history dating from infancy, and the patients being quite young, the oldest being thirteen years old (Tillmans' case), and the majority being only a few months old.

I have not succeeded in finding a case quite like my own in which a growth of this nature first began to give trouble in late adult life, but Dr. Rufenacht Walters, in the 'British Medical Journal' for 1893, vol. i, gives an account of a case which, though probably of sebaceous origin, may possibly have been a case of this nature. He says, "A man aged thirty-four years consulted me on account of periodical attacks of slight stomach-ache followed by a little discharge from the navel; he had consulted another medical man, who had told him that he had a slight rupture at the navel. On examination I found a patent umbilicus leading to a skin pocket containing a yellow mass which the patient stated had been there for years; the mass was readily detached by a little careful probing, and proved to be composed of hairs and sebaceous material. The pocket was about 2 inches in diameter and ¼ inch deep, with an opening of ½ inch. There was no hernia." It is expressly stated that the hairs were derived from a flannel belt he was wearing; no further details are given, and it is not stated whether any re-accumulation took place.

Villar, in the work to which I have already referred, gives details of eighty-eight cases of umbilical tumour of various kinds, but there is not among them one resembling my case in its histological details occurring in a patient of advanced years; several cases of fibrous papillomata are mentioned in this series, one of which contained a small serous cyst, but in none of them are intestinal gland structure or muscular fibres described as having been found. The patients were from thirty to fifty years old.

In the Clinical Society's 'Transactions' for 1893 there is an account by Mr. Battle of a case in which he removed an umbilical polypus which proved to have been an everted Meckel's diverticulum, and which was still connected with the intestine, from a child 1½ years old; the child died from scarlet fever shortly after the

Digitized by Google

operation, and the condition was verified by *post-mortem* examination.

In the paper by W. Ophüls, previously referred to, references are given to most, if not all, of the cases bearing on the subject published up to 1895, among which are three cases of special interest, viz. that of Arndt, that of Löwenstein, and that of Tillmans, the references to all of which have been previously cited; in the case of Tillmans the secretion from the tumour was carefully examined, and was found to have an acid reaction and to have the power of digesting fibrin, and Tillmans considered that it was derived from a stomach diverticulum. Ophüls, however, in his interesting paper, which will well repay perusal, gives another explanation of the acid reaction of the secretion, attributing it to the influence of bacterial action on the exposed mucous membrane. *February 7th*, 1899.

Report of the Morbid Growths Committee upon Dr. Charles Green's case of umbilical papilloma in a patient aged fifty years.—We do not consider that this tumour is a papilloma. We agree in the main with the author's histological description, and we regard the growth as a columnar-celled carcinoma. Whether this is primary or secondary we are at present unable to decide. Should the absence of further symptoms show that the tumour was not secondary to an intra-abdominal carcinoma, we agree with the author's suggestion that it arose in Meckel's diverticulum.

(Signed) D'Arcy Power,
March 23rd, 1899. H. D. Rolleston.

Some members of the Committee present who examined the specimen are not inclined to regard it as malignant.

R. G. Hebb, *Chairman*.

April 29th, 1899.

Digitized by Google

14. *A case of substernal carcinoma.*

By W. S. LAZARUS-BARLOW, M.D.

THIS specimen was removed from the body of a man aged 56 years, who died in St. George's Hospital under the care of Dr. Penrose. For three months previous to admission he had complained of "tightness in the chest," and on admission there were great dyspnœa and urgent cough. Examination of the heart showed some œdema of the cords and also of the tonsils and posterior pillars of the fauces, with some inflammation of the soft palate. The patient had occasional attacks of dyspnœa while in the hospital, one of which was so severe that tracheotomy was performed. The operation, however, did not greatly relieve the distress, and the patient died seventeen days after admission.

The cause of the dyspnœa was not discovered until the sternum had been removed at the autopsy. It was then found that a growth about the size of a Tangerine orange lay obliquely in front of and pressed upon the trachea. The growth was not exactly placed in the mesial line, for though the upper portion lay on the right side of the middle line, the lower and more considerable portion lay on the left side. It occupied a space between the lower margin of the thyroid body and the upper margin of the fatty remains of the thymus, and was not connected anatomically with either of these structures. The growth had perforated into the trachea at a point in the middle line of the trachea one and a quarter inches above the bifurcation, and here a fungating mass the size of a hazel-nut presented itself. This mass was situated one and a half inches *below* the tracheotomy wound. There was enlargement of cervical lymphatic glands, especially on the right side. Microscopically the growth was a squamous-celled carcinoma.

Remarks.—The point of interest in this case has reference to the seat of origin of the growth. It is possible (1) that it arose in some embryonic remnant of epithelium included in the deeper structures during the closure of the branchial clefts; (2) that there might have been a primary undiscovered mass of growth connected, for example, with the pharynx or other part of the upper alimentary tract; (3) that it had arisen in an accessory thyroid body; (4) that

Digitized by Google

it had arisen in connection with the thymus body; (5) that it had arisen in connection with the trachea. Of these alternatives the first is regarded as the most reasonable, partly because it is probable that the main growth was here primary, and partly because of the difficulties in the way of the other explanations. Against the view that it was of thymic origin is that the remains of the thymus persist, and are in no way abnormal; against the view that it originated in the trachea is the histological character of the growth, while there is really little beyond its situation in favour of its origin from an accessory thyroid body. Nevertheless the possibility that a primary small growth may have been overlooked cannot be gainsaid, and it is of course quite impossible to prove definitely the view that has been adopted. It is interesting to note that on staining by Gram's method there is a complete absence of granules in the cells constituting the "cell-nests." Shattock has shown that "dermoid" must be distinguished from "mucosal" cysts, and that the method of distinguishing between them is greatly aided by the fact that mucosal epithelium has no stratum granulosum, the eleidin granules in which are readily recognisable on staining by Gram's method. The absence of eleidin granules in the cell-nests of the present specimen would argue that the embryonic remnant from which the carcinoma is supposed to have arisen was one derived from the pharyngeal mucous membrane during closure of the branchial clefts, and not one derived from the superficial skin.

The specimen is preserved in the St. George's Hospital Museum, No. 7075. *October 18th*, 1898.

---

15. *Vacuolated carcinoma of the antrum.*

By H. D. Rolleston, M.A., M.D.

The patient was a man aged 32 years, who first experienced pain on the right side of the face and lachrymations fifteen months ago. These symptoms were followed by swelling of the right cheek, which gradually increased. Ten months ago a tooth was extracted from the upper jaw on the right side and the antrum bored, with the result that half a teacupful of thick red fluid came away.

Digitized by Google

The tumour displaced the eye upwards, the palate downwards, encroached on the nose, and produced swelling of the face. Mr. Allingham, to whose kindness I am indebted for the specimen, removed the right superior maxilla. The antrum was filled by a soft white growth which has eaten its way through its bony boundaries.

Microscopically the growth is indistinctly divided up into lobules by delicate connective-tissue septa, which in places contain blood-vessels. In one or two places there are hæmorrhages. The general appearance of the growth composing the lobules is that of an anastomosing network of delicate trabeculæ enclosing round spaces. The trabeculæ are composed of rather small round cells, arranged in two or more layers; no fibrous tissue or vessels can be seen in these trabeculæ. The character of the cells is not, generally speaking, definitely epithelial, though some of the cells lining the spaces appear cubical. Inside the spaces there is a homogeneous material which is presumably produced by the cells. In some of the spaces detached cells can be seen lying loose.

The cells forming the trabeculæ are in a good state of preservation, and do not, except in a few sections, show vacuolation or manifest degeneration; in some of the sections small spaces may be seen beginning to form inside large trabeculæ of cells.

Towards the margin of the growth solid clumps and columns of cells can be seen, and in some of these the gradual formation of a lumen can be traced. This part of the growth strongly suggests carcinoma.

In some sections the epithelial-clad wall of the nasal cavity, with its ciliated cells in a good state of preservation, can be seen on the margin of the growth; while sections through the outer wall of the antrum show the invasion and absorption of the bone. The appearances are those of a small spheroidal-celled carcinoma of rapid growth, in which a peculiar change has taken place, leading to vacuolation of the epithelial columns and alveoli. A very similar appearance is sometimes presented in rather rapidly growing spheroidal-celled carcinoma of the breast, and may then imitate duct carcinoma.

Tumours of this kind are described by Ziegler[1] under the name of cylindroma carcinomatodes, who refers to a growth of this nature

[1] Ziegler, 'Text-book of Pathology,' translated by D. MacAlister, vol. i, p. 244.

Digitized by Google

in the lachrymal gland. Thoma[1] figures a growth exactly like this, and describes it as hyaline degeneration of a round-celled carcinoma of the mucous membrane of the antrum. This tumour, then, appears to be an atypical carcinoma in which a peculiar change of a presumably degenerative nature has taken place inside the alveoli. It probably arose from glands and not from the ciliated columnar epithelium lining the antrum, inasmuch as it is a spheroidal and not a columnar-celled growth. The degeneration might perhaps be more suitably regarded as allied to mucoid or colloid change than to hyaline, which is more associated with changes in connective tissue. The term vacuolated carcinoma is suggested as being preferable to cylindroma carcinomatodes, inasmuch as it is not ambiguous, and describes the characteristic appearances.

April 4th, 1899.

---

16. *The final sequel to a case already reported of recurrent cystic disease of a supposed accessory thyroid.*

By Arthur E. Barker.

It appears to be highly desirable that cases presenting very unusual pathological features should be followed up to the end clinically; and for this reason I desire to place on record a very short note of a case already reported to this Society in January, 1896, and which has since terminated in death. With this final note we shall have a tolerably accurate record of the life history of a growth which appears to be comparatively rare, and which, though undoubtedly malignant, as the issue shows, had nevertheless existed for at least eighteen years. As to the rarity of the condition I may take a statement of Mr. Edmunds in the 1896 volume of our 'Transactions,' p. 224. Referring to a case then reported by himself he says, "The only similar specimen to be found in the 'Transactions' of the Society is one of 'intra-cystic papilloma of an accessory thyroid gland,' described by Mr. Bilton

[1] Thoma.,' Pathology,' translated by Bruce, vol. i, p. 607.

Digitized by Google

Pollard in vol. xxxvii (1886), p. 507." This happens also to have been a case of my own in which I operated at University College Hospital, and upon which Mr. Pollard, our then surgical registrar, made the necessary microscopical examination, and reported it to this Society at my request.

Besides these three cases I believe Mr. Bryant has somewhere put another on record, and the Morbid Growths Committee, in considering my own case in 1896, refer to others alluded to by Woelfler in his treatise "Ueber die Entwickelung und den Bau des Kropes," Langenbeck's 'Archiv f. klin Chirurgie,' Bd. xxxix, 1883.

In reference to the malignancy of the case it is interesting to note that the structure and life history of this growth lend support to the axiom laid down many years ago by Virchow, *i. e.* that the more highly differentiated a neoplasm is, the less tendency has it to exhibit the characteristics of malignancy. Here we have a very complex structure of cysts and papillomata of the most highly developed form, and with this very slow growth and very moderate tendency to generalisation, and no cachexia. We know of its existence for at least eighteen years, and that at last it appears to have cut short the patient's life by what might be called an accidental extravasation of blood and pressure on the air-passages rather than by producing any particular dyscrasia.

A very interesting report of the Morbid Growths Committee, signed by Messrs. Berry, Bowlby, and Shattock, following my description of the tumour in 1896, leaves very little to be said as to its structure, but it is possible that the Society may think it desirable that this should now be supported by a further examination of the recurrent masses since removed, and which I now present for supplemental research.

The history of the case from the time of my report in 1896 is as follows:—The gentleman remained in good health from October, 1895, to January, 1897. He then became uneasy about a recurrence above the episternal notch, which more or less pressed upon the trachea and larynx. On January 27th, 1897, I set about removing this by excision, and found it as before, cystic. The cyst was about the size of a large walnut, and could not, unlike the previous recurrences, have been thoroughly excised unless I had with it removed part of the larynx with which it appeared to be incorporated, and this I decided not to do. I was obliged, therefore, to plug the deep wound and allow it to close from the bottom.

Digitized by Google

This, to my surprise, it did readily though slowly and without much fungation, which I had expected from the part left behind. From this on until October, 1897, he was quite well. He then came to me for the removal of another nodule in the posterior triangle of the neck. This was easily excised, being freely moveable, and the wound healed *per primam*. From this time I have not seen him, but he has written more than once saying he was well. At the beginning of last August (1898) he appears to have suddenly developed a large hæmatoma in the left side of the neck, presumably from rupture of some of the delicate vessels of the intra-cystic papillomata. A letter from his doctor (appended) is my only source of information in regard to the extent of the swelling and cause of death, which appears to have been from apnœa. Dr. A. E. Norburn wrote, "The large tumour appeared suddenly on the left side of neck (extending to the shoulder) after a fit of sneezing. It was doubtless due to hæmorrhage, subsided under treatment to a small mass the size of half a walnut, which was freely moveable, and was situated just above the subclavian artery. There were other small nodules in the neck, which, from their position, were of no immediate consequence.

"There was nothing in the neck within our reach to account for his dyspnœa; the larynx was depressed, and the trachea could not be certainly distinguished. On one occasion while examining him he gave two or three sharp coughs, and then, for an instant, the upper part of a mass which appeared to be enveloping the trachea, rose to the level of the episternal notch. His health had been failing for some time past."

I believe no *post-mortem* examination was made. He had had a similar attack of breathlessness associated with the sudden appearance of a tumour over the larynx some years before, and was only saved from death by tracheotomy performed in the country. The swelling then noticed disappeared, and he seemed, when I next saw him, none the worse for it. It probably was due to a sudden effusion of blood, as in the last instance.

I have no doubt that if we had all the published cases of this affection marked out carefully from beginning to end we should have important light thrown upon some of the questions of malignancy, not only of similar neoplasms, but perhaps of others as well.

The clinical history of the earlier years of the growth until it

Digitized by Google

assumed the enormous proportions it presented when I first operated on it in October, 1889, together with an account of what was found at the operation, will be found in the 'British Medical Journal,' June 21st, 1890. *January 17th*, 1899.

Report of the Morbid Growths Committee upon Mr. Arthur Barker's specimen of cystic disease of a supposed accessory thyroid.—The tissue selected for examination was a circumscribed ovoidal tumour, which was removed on January 27th, 1897. In October, 1897, a further series of tumours was removed, which have, on section, precisely the same macroscopic characters as the above.

The growth is furnished with a fibrous capsule, in many places of considerable thickness, and consisting in such largely of fibrifying spindle-celled tissue. The capsule is the seat of considerable hæmorrhage, both past and recent, and there is, moreover, wide-spread recent extravasation into the substance of the growth, possibly a result of the manipulation entailed by the operation. The tumour presents a complex system of narrow clefts holding a small amount of colloid and lined with exquisite columnar epithelium supported upon delicate septa of vascular connective tissue.

That the growth (like those already described in the Committee's Report upon the previous specimens shown by Mr. Barker in 1896) is formed on the papillary type is evident from a study of its periphery. Here there occur considerable intervals where the substance of the tumour is altogether unattached to the capsule, which has all the characters of a cyst wall, being regular in contour and lined with a single layer of somewhat flattened epithelium, whilst the epithelium on the contiguous or the separated ingrowths is highly columnar.

In certain situations the actual origin of the ingrowing system of processes is traceable from the wall of the cyst. The cells of the new growth retain their physiological property of producing colloid, a small amount of which occupies the narrow winding spaces between the complex system of papillary processes. In many spots the connective tissue forming the trabeculæ also contains colloid in which there occur the spherical vacuoles commonly seen in the normal secretion.

Although the growth is bounded by a capsule, it is to be observed that in certain places the latter is in process of invasion,

Digitized by Google

and for this reason we class it as malignant, although, as the clinical history of the case proves, its malignancy is of an extremely low grade, as in the other recorded examples of this class of neoplasm. This invasion appears in the presence of minute epithelial extensions beyond the general contour of the tumour; the youngest of these are yet solid, whilst others have acquired a lumen, precisely as described in the preceding Report, already referred to. No lymphatic tissue was encountered in the sections, so that the origin of the growth in a lymphatic gland, though probable, is not demonstrated. In the case of the specimens examined on the previous occasion the lymphatic origin was clear.

(Signed) JAMES BERRY,
A. A. BOWLBY,
SAMUEL G. SHATTOCK.

R. G. HEBB, *Chairman.*

April 29th, 1899.

Digitized by Google

X. BACTERIOLOGY AND PATHOLOGICAL CHEMISTRY.

1. *The relations of chemical composition to germicidal action.*

By James Ritchie, M.D.

The important relations which within recent years have been shown to exist between chemical composition and pharmacological action suggested that similar relations might exist when the toxic action of chemical substances towards bacteria was concerned. The following paper gives the results of a few preliminary inquiries undertaken with the view of investigating this point. In these, only the power of substances actually to kill the organisms used was taken account of.

The investigation involved the comparison of the members of groups of substances of allied chemical structure. In such a comparison it is necessary to ask how the action of a molecule of one body compares with the action of that of another, and the circumstances of the action of both must be as nearly as possible exactly similar. To meet the former condition solutions containing the substances in molecular proportions must be prepared. Such "normal" solutions are of course constantly employed by the chemist, and were used all throughout this research. In the case of a salt they are obtained by dissolving an "equivalent" (*i. e.* the molecular weight in grammes if the metal be monovalent, half that amount if it be bivalent, and so on) in one litre of distilled water. In the case of organic bodies such as alcohols, aldehydes, phenols, &c., I have applied the term normal solution to one where the molecular weight in grammes has been dissolved in one litre of water. In fulfilling the second condition, namely, that the circumstances surrounding the actions of the bodies compared should be similar, many precautions had to be adopted. The first

Digitized by Google

requisite here is to have bacteria of nearly constant vitality. In the many investigations which have been made on various antiseptics the familiar anthrax-spore thread method introduced by Koch has been much used. I adopted it in some of my experiments, but as many of the bodies investigated by me were very weak germicides, no results could be obtained with an organism in such a resistent form. In one or two cases, however, as will be seen, when this method was used the results were identical with those obtained when weaker organisms were employed. The typhoid bacillus is one of such weaker organisms, and has the advantage of not sporing. Old laboratory cultures grown at room temperature are of extremely constant vitality, and sub-cultures made from these and inoculated for twenty-four hours are similarly constant. Hence these were used for nearly all my experiments. The germicides must act on the bacilli in water, for if a substance such as bouillon, which contains organic matter, be used, a chemical union is apt to take place between the germicide and such organic matter, the result being that a certain amount of the former is as it were thrown out of court, and the amount of germicide available is diminished. This can easily be shown by making up solutions of the same body in bouillon and in water, and introducing bacteria. It will be found that it takes a much longer time for death to be effected in the case of the bacteria in the bouillon than with those in the water. Further, in comparing the action of such similar bodies as calcium and barium on bouillon, I found evidence that, per unit of time, combination with the organic bodies present did not occur in molecular proportions. This indicates how results may be vitiated if the precaution of using only such cultures of bacteria in water be not taken. Another point to be observed is that as nearly as possible the same number of bacteria be exposed to the same number of molecules of the body to be tested. In my experiments in any particular case the amount of germicide present was very great compared with the mass of bacteria to be dealt with, and though careful investigations were made no quantitative relations could be detected between the number of bacteria and the amount of germicide requisite to kill them; but the vitality of individual bacteria in a culture varies between very wide limits, and it was found that if a very large number of bacteria were present, more time required to be allowed for all the very vital individuals to be killed. It is, therefore, expedient in all experiments to have as

Digitized by Google

nearly as possible equal numbers of bacteria subjected to given amounts of the substances to be tested. This was effected as follows:—An agar plate was infected with typhoid bacilli by smearing with a platinum loop, and was incubated for twenty-four hours at 37° C. The resulting growth was scraped off with the loop and shaken up in sterile distilled water. As numerous flocculi exist in such an emulsion, these were removed by filtering through a plug of sterile glass-wool held in a sterile glass tube. Equal moieties of the filtrate contained approximately equal numbers of typhoid bacilli. The general technique of the experiments was this:—A series of graduated dilutions of normal solutions or of fractions of normal solutions of each agent to be compared was made up, and about 1 c.c. of every solution placed in a test-tube. A minute drop (each drop being of the same size) of the typhoid emulsion described was placed in each tube; at the end of the period of observation an eyelet from each tube was placed in 10 c.c. of melted agar, and the latter plated and incubated for twenty-four hours. The dilution in the case of each agent with which no growth took place was noted. Seeing that only comparative observations were aimed at, in the results which follow no account is taken of the slight additional dilution effected by the water of the minute drop of typhoid emulsion added. The error thus introduced would evidently be the same for the same dilutions of the different agents, and therefore may be neglected.

In some cases the technique was varied, in that instead of the dilutions of different agents requisite to kill a given number of bacteria being observed, the times needed for one given dilution to kill the bacteria were compared. In cases where both methods were tried with the same agents the results corresponded. The reason of this correspondence requires, however, further investigation. It may be said that, while the experiment was in progress, in nearly every case the tubes were kept at the room temperature. In only a few cases was the action of the germicides aided by warmth.

The general results of the experiments may now be indicated.

1. *The metals as germicides.*—The only basis on which these can be really compared is by taking advantage of the groups which are formed under the periodic law of Mendeléeff, and even here we are somewhat hampered by the insolubility of many metallic salts.

Digitized by Google

(*a*) *Calcium, Strontium, Barium.*—The chlorides of these were used. Example:

	2 hours.	3 hours.	4 hours.	7 hours.
1 c.c. 2N $CaCl_2$ + $\frac{1}{10}$ c.c. typhoid emulsion .	+ ...	+ ...	+ ...	0
1 c.c. „ $SrCl_2$ + $\frac{1}{10}$ c.c. typhoid emulsion .	+ ...	+ ...	0 ...	0
1 c.c. „ $BaCl_2$ + $\frac{1}{10}$ c.c. typhoid emulsion .	+ ...	0 ...	0 ...	0
1 c.c. ·75 % NaCl + $\frac{1}{10}$ c.c. typhoid emulsion (control)	+ ...	+ ...	+ ...	+

(The sign + indicates that growth took place; 0 that no growth occurred.)

(*b*) *Magnesium, Cadmium, Zinc, Mercury.*

(*a*) The chlorides of these metals were used. Example:

$MgCl_2$ ceased to be efficient to kill a given number of organisms at $\frac{1}{400}$ normal strength, $ZnCl_2$ at $\frac{30}{400}$, $CdCl_2$ at $\frac{4}{400}$, while $HgCl_2$ retained its potency to $\frac{1}{400}$ normal strength.

(*β*) Nitrates. Here $Hg(NO_3)_2$ required to be excluded, as it cannot be got in neutral solution in water without decomposing. Example:

$Mg(NO_3)_2$ in normal strength equalled in action a $\frac{3}{10}$ normal solution of $Zn(NO_3)_2$, and a $\frac{5}{100}$ normal solution of $Cd(NO_3)_2$

As far as the comparative action of the metals was concerned the chlorides and nitrates gave similar results.

Thus both in the calcium group and the magnesium group a rise in germicidal power takes place with rise in atomic weight.

(*c*) *Lithium, Sodium, Potassium.*—The nitrates were here used. Example:

$LiNO_3$ in normal solution equalled in action $NaNO_3$ in 1·2 normal solution, and KNO_3 in $\frac{1}{2}$ normal solution.

This looks like an exception to the above statement regarding the relation of germicidal action to atomic weight. It is interesting, however, to note that there are several other characteristics, *e. g.* the insolubility of its carbonate, in which lithium differs from the other members of the group.

2. *The acids as germicides.*—The action of an acid atom in a group *quâ* acid is well known. To prove its activity one need only say that whereas an $\frac{N}{10}$ solution of Na_2SO_4 has no germicidal effect whatever, an $\frac{N}{100}$ solution of H_2SO_4 is a potent germicide.

Interesting light is thrown on the cause of this activity when the group of fatty acids is considered. It is best to omit formic acid, as its reducing action introduces a new factor. Example:

The following solutions were found of equal potency: acetic acid

Digitized by Google

$\frac{1}{100}$ normal, propionic acid $\frac{7}{100}$, butyric acid $\frac{5}{100}$, valeric acid $\frac{4}{100}$, caproic acid $\frac{3}{100}$. Comparing hydrochloric acid and acetic acid we find a $\frac{1}{100}$ normal solution of the former equal in action to $\frac{1}{20}$ normal solution of the latter.

It is to be noted that in all these acids there is one atom of hydrogen acting as an acid, and the irregularity of its action is thus somewhat puzzling.

Now if we compare the neutral salts of these acids we find that there is a regular increase of germicidal action with increase of molecular weight, the acetates being the least active. Example:

The following solutions were found equal in action: potassium propionate 2·7 normal, potassium butyrate 1·5 normal, potassium valerianate ·3 normal.

The key to the apparent want of order among the acids is found in the fact *that the germicidal action of the acids varies with the avidity of the acid.* The results of physical chemistry show that the order of germicidal potency given above for the fatty acids is precisely the order of their chemical avidity. If we take the powerful mineral acids HCl, HNO_3, H_2SO_4, we find that they are nearly equal in activity, and also very nearly equal in germicidal potency.

3. *The halogens and halogen compounds as germicides.*

(*a*) Chlorine, bromine, iodine. (The solutions of these were carefully standardised against sodium thiosulphate immediately before use.) Example:

The following solutions were found to have equal potency: Cl $\frac{3}{40000}$ normal, Br $\frac{1}{40000}$ normal, I $\frac{2}{400000}$ normal. (The potency of the last was probably increased by the KI added to cause solution.)

(*β*) Hydrochloric acid, hydrobromic acid, hydriodic acid.

Example (1).—(Anthrax threads:)

Normal solutions.	1 hour.	2 hours.	3 hours.	7 hours.
HCl	+	+	+	0
HBr	+	+	0	0
HI	+	0	0	0
H_2O (control)	+	+	+	+

Example (2).—(Typhoid emulsion:)

Normal solution.	1 min.	5 min.	15 min.	30 min.
HCl	+	+	+	0
HBr	+	+	0	0
HI	+	0	0	0
H_2O	+	+	+	+

Digitized by Google

These two experiments are interesting as showing that two different organisms under different circumstances give the same comparative results with the same agents.

The general result is that *with the halogens and the halogen derivatives increase of germicidal action is associated with increase of atomic weight.*

In connection with the acids mentioned it may be said that their avidity as acids rather decreases with the atomic weight of the associated halogen.

4. *Comparison of the germicidal actions of methyl, ethyl, propyl, and butyl alcohols with each other, and with that of the corresponding aldehydes and fatty acids.*

The following examples may be given:

(*a*) *Alcohols.*—(1) Methyl alcohol 10 normal = ethyl 4 normal; (2) ethyl alcohol 2 normal = propyl normal; (3) propyl alcohol normal = butyl $\frac{1}{2}$ normal.

(*b*) *Alcohol, aldehyde, acid.*—(1) Ethyl alcohol 5 normal = ethyl aldehyde $\frac{1}{10}$ normal = acetic acid $\frac{1}{50}$ normal; (2) propyl alcohol normal = propyl aldehyde $\frac{2}{10}$ normal = propionic acid $\frac{1}{14}$ normal.

Thus *among the alcohols*, as among the neutral salts of the fatty acids, *there is an increase of germicidal action with increase in molecular weight.*

5. *The germicidal action of the cresols and diatomic phenols.*—Only a few points were investigated here.

(*a*) The cresols—ortho-, meta-, para-. The solutions having equal potency here were orthocresol $\frac{18}{6000}$ normal, paracresol $\frac{15}{6000}$ normal, metacresol $\frac{4}{6000}$ normal.

It is interesting to note that in other chemical properties, such as melting-point, specific gravity, heat of formation, &c., the ortho-body resembles the para- body, both standing slightly apart from the meta-.

(*b*) The diatomic phenols—pyrocatechin (ortho-), resorcin (meta-), hydroquinone (para-). Here also it was found that *the ortho- and para- bodies are about equal in potency, and stand somewhat apart from the meta- body.*

From these very scanty and elementary observations it will be seen that there is some ground for belief that an important relationship exists between chemical composition and germicidal action. The latter is apparently very complex, sometimes one part of a molecule playing a part, sometimes another.

May 16*th*, 1899.

Digitized by Google

2. *On infections by unsound meat, more especially with regard to the* Bacillus enteritidis (*Gärtner*).

By HERBERT E. DURHAM.

THOUGH it is possible that cases of illness caused by eating unsound meat may sometimes be due simply to the sterile chemical products of bacterial activity in the absence of living germs, yet hitherto no bacteriological evidence is available in most of such cases as have occurred. A majority of the recorded outbreaks with bacteriological evidence have been shown to be due to the *Bacillus enteritidis*.[1]

Serum diagnosis (*Gruber's reaction*) *as applied to cases of "meat infection."*—The results of the examination of two outbreaks have already been recorded by the author (one occurred at Hatton,[2] in which the *B. enteritidis* was isolated, the other at Chadderton, Oldham).[3] Two further outbreaks have been examined, one at Surbiton, thanks to the assistance of Dr. Cooper; the other at Salford, for which the author's thanks are due to Dr. Tattersall.

In the appended tables are shown the results obtained by testing the serum of the patients about eight weeks after their illness upon a variety of cultures of the *B. enteritidis*. It will be seen that many of these serums give positive reactions of diagnostic importance, in that they clump the bacillus in comparatively high dilutions. More than fifty control observations show that "normal"

[1] The following short abstract of the outbreak investigated by Gärtner may be added. An ox was killed on account of diarrhœa, &c.; ninety-three persons ate of the meat; of these fifty-eight became ill in consequence, and one of them died. The person who died ate a considerable quantity of the meat in an uncooked condition, and not long afterwards was taken with vomiting, &c.; however, he did not die until thirty-six hours after the meal. The incubation period in this case is masked by the effects of surfeit. In the other cases the incubation periods were from twenty-four to thirty hours; the illness lasted three to five days in mild, and about four weeks in severe cases. The symptoms were nausea, vomiting, diarrhœa, weakness and prostration, fever, pains in the joints. In several instances the illness was followed by desquamation on the hands and feet. Microscopical examination showed that the capillary blood-vessels in the meat were crammed with bacilli. By means of cultivation these bacilli were isolated, and found to be identical with a kind of bacillus which was present in large numbers in the organs of the deceased man. This bacillus was named the *Bacillus enteritidis* by Gärtner.

[2] 'Brit. Med. Journ.,' 1898, vol. ii, p. 600.

[3] Ibid., p. 1797.

Digitized by Google

human serum does not clump these bacilli at dilutions of 1 in 100. On the whole the strongest reactions are given by the tests upon the varieties "Hatton" and "Günther;" less strongly upon "Psittacosis" and "S. P. 2" (kindly sent by Prof. Lorrain Smith, from Belfast); and not sufficiently strongly for diagnostic purposes with "Gärtner" and "Morbificans Bovis (of Basenau)." It is to be concluded that the fever from which the patients suffered was caused by a variety of the bacillus closely resembling "Hatton" and "Günther." It will be seen in the table that the reactions given with typhoid bacilli are negative; it is to be noted, however, that when the test was performed in the slipshod manner of mixing one drop of serum with nine drops of typhoid culture,

Surbiton outbreak, August 19th, 1898.

Note.—† means strong reaction; * = slight reaction; tr. and ? = doubtful; — = no observation.

	Cultures.							
Date of serum.	Hatt.	Gärt.	Günth.	Morb.	Psitt.	Sp. 2.	Typh. H.S.	Typh. W. Gwyn.
B. 16/10/98.								
1:20	†	—	†	*	*	†	—	0 0
1:50	*	—	?	0	0	0	—	— —
1:100	0	0	0	0	0	0	0	0 0
M. B. 16/10/98.								
1:100	†	?	†	0	*	†	0	0 0
1:200	†	—	†	0	*	†	—	— —
1:500	tr.	—	0	0	0	0	0	0 0
L. 10/11/98.								
1:20	†	*	†	tr.	†	†	—	— —
1:50	†	tr.	†	0	†	†	—	— —
1:100	*	0	0	0	0	tr.	0	0 0
C. 16/10/98.								
1:100	†	0	†	0	*	—	0	0 —
1:200	†	—	†	0	*	*	—	—
1:500	tr.	—	?	0	0	0	—	— —
W. 16/10/98.								
1:100	†	0	†	0	tr.	—	0	0
1:200	?	—	†	0	0	0	—	—
R. 27/10/98.								
1:100	†	tr.	†	0	†	—	—	— —
1:200	tr.	—	0	0	0	0		
D. 23/10/98.								
1:100	†	*	†	0	†	—	—	— —
1:200	†	0	†	0	0	0		
1:500	0	0	0	0	0	0		

Total—10 cases. 2 deaths. All survivors but one examined.

Digitized by Google

For the following clinical notes I am indebted to Dr. Cooper:

M.B. Incubation period 12 hours; duration 19 days; slow convalescence.
B. „ „ 16 „ „ 6 „ mild attack.
L. „ „ 8 „ „ 15 „
M. H., æt. 16 years. Incubation period 20 hours; duration 12 days.
W. 19 „ „ „ 24 „ „ 8 „
D. 12 „ „ „ 15–17 „ „ 5 „
R. 50 „ „ „ 26 „ „ 7 „
C. Became ill 34 hours after performing post-mortem on one of the fatal cases (H.N.).

H. N., æt. 67 years. Incubation period probably 44 hours; severe attack; died on 8th day.
E. C. 67 „ Incubation period probably 8 „ „ „ died on 4th day.

Unfortunately no bacteriological examination of the fatal cases was made. The incubation and duration of the illness both point to something more than a mere intoxication with formed products, especially when taken with the serum reactions of the survivors.

and observing the effect after half an hour, considerable clumping occurred; a lantern slide from a preparation of the serum of M. B. (Table I) in which the reaction is almost complete (dilution 1: 10; time, half an hour) is shown. If this had been the only test performed the case would in all probability have been returned as "enteric fever." The varieties Hatton and Günther are not very susceptible mutually to typhoid when tested by experimental or "natural" sera.

The tables also show how much less differentiation is to be seen in the serums which were tested in low dilutions. A case may be quoted which clinically appeared to be a case of enteric fever acquired by the consumption of oysters. Gruber's reaction proved negative at each of the five times during the course of the fever and during convalescence that serum was taken. The first was taken towards the end of the first week; my observations harmonise with the recently published results of Kasel and Mann,[1] in that I have never yet seen a diagnostic positive reaction at so early a stage.

One of the later samples when tested by the "slipshod method" gave very considerable amount of clumping with typhoid bacillus, but also with the variety Günther; since these bacilli do not react readily mutually the result was of no diagnostic importance, and,

[1] 'Münchener med. Wochenschrift,' 1899, p. 581.

Digitized by Google

Mary Street, Salford outbreak, July 1st, 1898.

Blood collected September 26th, 1898.

	Culture.								
Mrs. B.	Hatt.	Gärt.	Günth.	Morb.	Psitt.	Sp.2.	Typh.H.S.	Typh.W.	Gwyn.
1 : 100 . .	† ...	? ...	† ...	? ...	— ...	— ...	— ...	0 ...	0
1 : 200 . .	0 ...	0 ...	0 ...	0 ...	0 ...	0			
Henry, æt. 9.									
1 : 20 . .	† ...	† ...	† ...	— ...	— ...	— ...	0 ...	tr.	
1 : 50 . .	0 ...	0 ...	tr. ...	0 ...	0 ...	0 ...	0 ...	0	
George, æt. 7.									
1 : 20 . .	† ...	0 ...	† ...	— ...	— ...	— ...	0 ...	0	
1 : 50 . .	0 ...	0 ...	?						
Gertie, æt. 5.									
1 : 100 . .	† ...	0 ...	† ...	* ...	— ...	— ...	— ...	0 ...	0
1 : 200 . .	0 ...	0 ...	0 ...	0 ...	0 ...	0			

Total—5 cases. 1 death. All survivors examined.

Note.—Some beef was bought on June 25th; it was hashed and eaten without ill effect on the following day. The remains were eaten cold before 9 a.m. on the 28th by the mother and four children (the father and babe of three months did not have any and were not ill). The mother was taken with hiccough about 2 p.m. on the same day, and later diarrhœa and vomiting set in; exact onset not known (incubation not less than about six hours). She was in bed four days. Albert, æt. 3 years, began vomiting in the night of 28th (incubation about twelve hours or more). Next morning diarrhœa; great collapse; died about thirty-six hours after the meal. The other children were taken ill about the same time, but they all recovered, one being in danger for some time. The illness was ascribed to the thundery hot weather having affected the meat.

as would be expected, trials with these and several other cultures in higher dilutions all gave a negative result.

An outbreak of illness through eating pickled tongues occurred last summer at Atherton. Dr. Neech very kindly succeeded in obtaining two blood samples for me; both of these failed to give any reaction, though tested upon a large number of varieties. Another negative result was afforded by "M," who had eaten veal pie with "X" at lunch on one day without ill effect, but when the pie was finished the next day by "M" and "Y," both had slight diarrhœa lasting only twenty-four hours. "M's" serum was tested on the second and ninth days: it was, perhaps, too soon after the onset of the illness for reaction to have developed if really the illness was due to *B. enteritidis;* laboratory experience shows that the acquisition of reaction may be much delayed after very slight doses of bacilli.

It may be noted that the researches of de Nobele[1] completely

[1] De Nobele, "Du séro-diagnostic dans les affections gastro-intestinales d'origine alimentaire," 'Ann. Soc. de Méd. de Gand,' 1899, p. 5.

Digitized by Google

confirm my observations upon the relative strength of reaction towards different varieties of *B. enteritidis* as well as the fact that in insufficient dilution an erroneous diagnosis of enterica may be given.

Distribution of the B. enteritidis.—The identification of a given microbe as the cause of a disease is really only the beginning of the knowledge requisite for the proper control of the disease; we must also know its economy in nature. This is extremely difficult to work out in the case of bacteria.

Apart from disease in man or animals we do not yet know very much about the ultimate or outside life of the *B. enteritidis*. In connection with illness in man we know from the researches of Gärtner, van Ermengem, Gaffky, Günther, Holst, Basenau, and many others, that the animals from which the meat was obtained were suffering from infections with *B. enteritidis* at the time when they were slaughtered. In many of the cases there was either puerperal trouble of cows, or septicæmic diarrhœa of calves. Bacilli have been recorded under various names which agree in their morphology and their cultural characteristics (especially their powers of acid and alkali formation, fermentation and serum susceptibility), and these we must regard as members of a well-defined group; this may be called the group of the *B. enteritidis*. The following examples may be named hog-cholera bacillus of Salmon and Smith, *B. typhi murium* of Loeffler, *B. psittacosis* of Nocard, and the so-called pseudo-tuberculosis bacillus of several authors. All of these cause spontaneous epizootics amongst the different animals. There is reason to think that the hog-cholera bacillus has been communicated to man (*e. g.* the Middlesbrough epidemic), as also the so-called psittacosis bacillus. The *B. typhi murium* is of interest from the fact that cultures of it are sold to be scattered about for the purpose of killing mice (especially field mice); according to Schmidt (Baumgarten's 'Jahresbericht,' xii, p. 513) 3063 cultures were sent out from the Dresden laboratory between October, 1895, and April, 1896.

It remains to be seen whether these doings will have disastrous results for man. The fact that the so-called mouse typhoid and pseudo-tubercle in guinea-pigs arise spontaneously in laboratories is suggestive that the bacilli may be conveyed to them from without by means of the food; in so far as some form of corn may be the vehicle, it may be mentioned that Wolffin has described an

Digitized by Google

organism (*B. levans*) in fermenting dough which is somewhat similar in its cultural reactions to the *B. enteritidis*, but the account is hardly complete enough for justifying any certain conclusion. For the present we must leave the question as to how the cows, calves, pigs, &c., obtain their infections unanswered, but we should keep the fact that they do become infected before us, because we may be secondarily infected through their means.

We must not rest satisfied in the knowledge that these infections occur amongst our sources of meat, but must go further and determine whence the infection arose. In the case of an outbreak of swine plague Voges was able to determine deaths previously amongst the poultry, and also to find the microbe of swine plague in the skimmed milk with which the young pigs were fed; still the question how the bacilli got into the milk remained unanswered.

Lantern slides showing the morphology and agglutinating reactions of the *B. enteritidis* were demonstrated.

Morphology.

Characters of B. enteritidis.—1. Young agar cultures; polymorphous; threads, bacilli of various lengths, and round coccus-like bodies (similar to typhoid bacillus).

2. Gelatine streak cultures a few days old may show the characteristic forms whose ends do not stain (this was noted by Gärtner); in recently divided individuals the stained material is all at one end. This appearance is not always obtained unless the culture is of the right age.

3. Flagella maximum ten or more (similar to typhoid bacillus).

Cultural characteristics.

1. Agar, gelatine, coagulated serum, Elsner's gelatine, potato and milk show nothing of diagnostic importance except the non-liquefaction of gelatine, and the non-coagulation of milk.

2. Broth soon becomes turbid, and a pellicle and considerable deposit form.

3. Litmus-whey becomes slightly acid (2·5—4 per cent. one tenth N NaOH) in the first two days at 37° C.; about fourth day alkalinity begins (distinguishes from typhoid and colon bacilli).

4. Peptone 2 per cent. with glucose or mannite, 0·1 per cent.

Digitized by Google

becomes alkaline after a passing slight acidity (distinguishes from typhoid bacilli).

5. Fermentation tests with 1 per cent. peptone and 1 per cent. various sugars; dextrose, levulose, maltose, dextrine, and mannite lead to acid and gas formation; gas formation distinguishes from typhoid. Lactose, cane sugar, glycerine, starch, and inulin are not fermented. (All colon bacilli ferment lactose and glycerine, *Lactis aërogenes.* Friedländer, &c., also ferment starch or inulin.)

6. Milk with dextrose (2 per cent.) becomes highly acid, but is not clotted.

7. Indigo carmine and litmus are readily reduced (like typhoid bacillus) when added to suitable media.

Colonies on gelatine in the neighbourhood of colonies of *B. coli communis* are much inhibited; they may appear like colonies of streptococci.

Growth on old agar upon which the bacillus or *B. typhi abd.* or *coli* has been grown have not afforded me satisfactory results.

The following cultures have been examined: "Gärtner," "Günther," "Hatton," Psittacosis (Nocard), *Bovis morbificans* (Basenau), S.P. 2 (Lorrain Smith), Morseele, Gand, Calmpthoult (van Ermengem), Sirault (Herman), Aerteÿcke (de Nobele), Vienna, *Typhi murium* (Loeffler), hog cholera.

I must express my gratitude to Prof. Gruber, Prof. van Ermengem, Prof. Flexner, Dr. Nicolle, Dr. Basenau, Dr. Günther, and Prof. Lorrain Smith for kindly sending me cultures.

May 16th, 1899.

3. *Congenital tuberculosis in calves.*

By J. McFadyean, M.B., B.Sc.

Until within the last few years the opinion that tuberculosis is frequently transmitted from the parent to the unborn fœtus was almost universally held by breeders of cattle and by veterinary surgeons. Nevertheless this belief was never justified by the evidence bearing upon the question. Needless to say, the only evidence warranting a belief in the frequency of congenital tuberculosis would be the common occurrence of demonstrable tuber-

Digitized by Google

culous lesions in the bodies of animals newly born or so young as to preclude the possibility of the lesions having been *post-partum* in their origin. Search for such evidence has shown that with comparatively rare exceptions calves born of a tuberculous parent are free from any sign of tuberculous disease. That this apparent freedom from the disease is real has within recent years been abundantly proved by the application of the tuberculin test to the young progeny of tuberculous cows.

The proportion of calves born tuberculous has been variously estimated at from 1 in 10,000 to 3 per 1000. The former estimate was based on the results of the slaughterhouse inspection of calves under one month old in the Munich slaughterhouse, where from 20 to 30 per cent. of the adult cattle are tuberculous in some degree. The estimate was probably too low, owing to a considerable number of slight cases being overlooked. The higher estimate has been given by Bang for Denmark, where from 30 to 40 per cent. of the cows are, or until recently were, tuberculous. So far as I am aware only one instance of indubitably congenital tuberculosis in the calf had been put on record in this country prior to 1897, and that case was described by myself in the 'Journal of Comparative Pathology and Therapeutics' in the year 1891.[1]

In the latter part of 1896, in consequence of a discussion which was carried on in the columns of the 'Veterinary Record,' I offered to pay the sum of one guinea for each new-born tuberculous calf forwarded to the Royal Veterinary College. Up to the present time that offer has brought me three undoubted cases of congenital tuberculosis in the calf. One of these I received in 1897, and it has already been referred to in the 'Journal of the Royal Agricultural Society of England' (vol. ix, p. 125). The remaining two cases were received during the last seven months. Before describing these it may be of interest to note regarding the case already recorded that the cow which gave birth to the calf was the subject of very extensive tuberculous disease, including tuberculous metritis.

Case I.—In this case I had not an opportunity to make a complete *post-mortem* examination, as only portions of the diseased organs were sent to me. A piece of skin and umbilical cord was also sent to

[1] Vol. iv, p. 149.

Digitized by Google

show that the calf was only a day or two old. No history of the mother was obtainable. The following were the lesions noted:

Liver.—This organ contained numerous tubercles rather smaller than barley grains. The hepatic lymphatic glands were enlarged to the size of a horse-bean, and on section they showed some streaks of caseation.

Spleen.—The tubercles here were larger than those in the liver, but only about half as numerous.

Lungs.—Tubercles about the same size as those in the spleen, but scarcely so numerous.

Heart.—A piece of this organ comprising 2 inches at the apex and a portion of the outer wall of the right ventricle was sent, and it contained one tubercle as large as a pea.

Histology.—All the tubercles had yellow caseous and partially calcified centres, around which they were composed of epithelioid and giant cells. Tubercle bacilli were sparingly present.

CASE II.—This calf was exactly a week old when killed. The mother was killed about the same time. The lungs of the cow were tuberculous, but no other lesions were observed. The uterus was not examined. The *post-mortem* examination of the calf showed the following lesions:

Liver.—This organ had scattered through its substance some hundreds of yellow tubercles, somewhat smaller than barley grains.

Hepatic lymphatic glands.—These were enlarged to form a mass about the size of a small hen's egg. Their substance was mottled with white caseo-necrotic streaks.

Spleen.—Normal in size, but its pulp contained upwards of thirty yellow tubercles, mostly about the size of barley grains.

Kidneys.—Each organ contained a few yellow tubercles, rather smaller than those in the liver and spleen.

Lungs.—About ten yellow tubercles as large as barley grains were present in the two lungs.

Bronchial and mediastinal lymphatic glands.—These were all distinctly enlarged, and on section showed white opaque spots (necrotic tubercles).

Other lymphatic glands.—Visible tubercles were present in a renal lymphatic gland, in two of the mesenteric glands, in the right and left popliteal glands, and in one of the pre-pectoral group.

Digitized by Google

The following parts appeared healthy: heart, pleura, peritoneum, and the axillary, pharyngeal, and pre-crural lymphatic glands.

Histology of the lesions.—Here, again, the tubercles had the usual histology of such lesions in the ox. They were all undergoing central necrosis and caseation. Giant-cells were present in most of them, but sparing in number. No calcification. Tubercle bacilli sparing in number.

A most interesting feature of these cases is the contrast which they present to the generality of cases of tuberculosis in adult cattle. The most characteristic features of tuberculosis of the adult ox are (1) the frequency with which the pleura and peritoneum are involved when the disease is at all extensive, and (2) the rarity of splenic lesions. As in other species, tubercles in the heart muscle are exceedingly rare, as are also lesions in the popliteal lymphatic glands. In both these congenital cases, however, the tubercles were most numerous in the liver, and both cases had lesions in the spleen.

The differences are partly explained by the fact that congenital tuberculosis is probably always generalised in the sense that it is due to blood infection, whereas generalised tuberculosis in this sense is relatively rare in the adult ox or cow. Furthermore, when the disease does become generalised in the adult animal the distribution of the lesions is entirely different from that seen in congenital cases. The tubercles which result from a blood infection in the adult are always vastly more numerous in the lungs than in any other part, and the liver, spleen, kidneys, and body lymphatic glands may develop few or no tubercles. It is therefore quite erroneous to regard the presence of tubercles in the spleen as the most reliable evidence of generalisation in adult cattle, although this has actually been done in the official regulations regarding the condemnation of tuberculous carcases in France.

May 2nd, 1899.

Digitized by Google

4. *Section showing a mycosis (? aspergillar) of lung of horse.* (*Card specimen.*)

By Alexander G. R. Foulerton.

[With Plate VIII.]

The specimens show sections through the lung of a horse referred to by Prof. J. McFadyean in the discussion on pseudo-tuberculosis. The lungs presented macroscopically a number of small grey miliary nodules scattered throughout their substance. Each nodule contains a reniform mass of mycelium, surrounded by smaller round-celled infiltration. The mycelium in some places has grown through the walls of the air-vesicles. In other places it appears to fill the lumen of small bronchioles.

The mycelial filaments are closely packed in the central portion of the fungus mass, and separate somewhat towards the periphery in a radial fashion. The filaments are unevenly contoured, showing varicose swellings here and there; they divide dichotomously in the peripheral portion of the mass, and some of their terminal branches are slightly bulbous at the extremity. No absolute indication of fructification can be seen, but the bulbous terminal extremities recall the appearance of the abortive attempts at the formation of a spore-bearing head, devoid of sterigmata or spores, observed when *Aspergillus fumigatus* is grown under certain conditions in an atmosphere free from oxygen. The mycelium is stained by the ordinary basic aniline dyes, the peripheral portion of which takes the dye more deeply than does the closely packed central portion. Treated with Ehrlich's tri-acid solution the filaments stain a faint bluish-green colour. The whole mass of mycelium stains deeply with Ehrlich's hæmatoxylin solution, and retains the gentian violet stain when treated according to Gram's method.

Microscopically the appearance of the fungus closely resembles that seen in known cases of natural aspergillar infection, and also that resulting in guinea-pigs and rabbits after experimental intravenous inoculation with spore-bearing cultures of *Aspergillus fumigatus*.

February 21st, 1899.

Digitized by Google

Digitized by Google

DESCRIPTION OF PLATE VIII,

Illustrating Mr. Alexander G. R. Foulerton's paper on Mycosis (? Aspergillar) of Lung of Horse. (Page 272.)

FIG. 1.—Stained with hæmatoxylin. × 40.

FIG. 2.—Stained with hæmatoxylin. × 75.

(Photographs by Mr. Barnard.)

Digitized by Google

Digitized by Google

EXPLANATION OF PLATE VIII.

Illustrating Mr Alexander G. R. Foulerton's paper on Mycosis [illegible] of Lungs of Horse. (P. [illegible] 272.)

Fig. 1.—Stained with haematoxylin. × 60.

Fig. 2.—Stained with haematoxylin. × 60.

Photomicrographs by Mr Burrard.

Digitized by Google

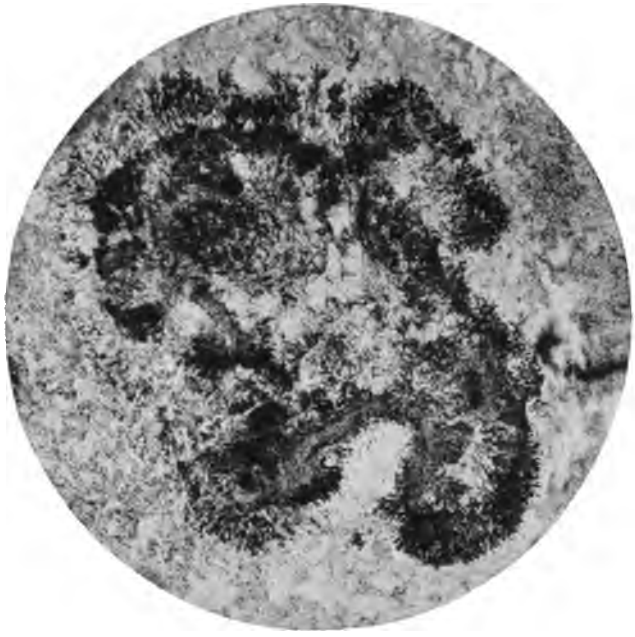

Fig. 1.

Fig. 2.

Digitized by Google

Digitized by Google

5. *Blackwater or hæmoglobinuric fever.*

By W. H. Crosse and W. C. C. Pakes.

Considerable attention has recently been called to blackwater fever, particularly by the assertion of Koch that it is really a form of quinism, or is produced by that drug.

The account of a case which has occurred in England and which we have had the opportunity of investigating is, therefore, we venture to think, not without interest.

Before referring to the case we should like to give a brief account of the disease in general.

The fever occurs chiefly in tropical Africa among young Europeans. Its incidence among the natives is usually very small; there is said to have been, however, an epidemic among them recently in the Cameroons. F. Plehn distinctly states that the fever does attack negroes in the Cameroons, but it has never occurred on the lower Niger, at least to our knowledge.

It attacks only those who have suffered previously from malarial fevers, and who have, from various causes, become debilitated and run down. It usually comes on during the course of what appears to be an ordinary malarious attack, and some special exciting cause such as exposure to a chill or to the sun is generally to be noted. Plehn says that it may replace an ordinary attack of malaria.

The mortality is usually great for reasons which will be explained later.

An account of this disease is given in 'Notes on Malarial Fevers,' by one of us, and also in an introductory address read before the Physical Society at Guy's Hospital on October 3rd, 1898. The leading symptoms are:—(1) fever, (2) jaundice, (3) hæmoglobinuria, (4) nausea and vomiting (often green vomit).

In November of this year one of us (W. H. C.) was called in consultation with Dr. Wooldridge, of Camberley, to whom we are indebted for notes of the case, and Brigade-Surgeon Lieut.-Col. A. Clarke, to see a young officer who had recently returned to England after having served in Nigeria for fourteen months: the patient had had many attacks of malaria, dysentery three times, and was suffering from chronic dysentery on his arrival in England about the middle of November; his last attack of malaria occurred at Grand Canary nine days previously. He arrived in England in a

Digitized by Google

somewhat debilitated condition. Six days later, though feeling somewhat unwell, he joined his brother officers at mess. During mess he felt decidedly chilly, on the following day he had a rigor and went to bed. The next day, November 27th, he was noticed to be jaundiced, he had a severe rigor (the temperature rising to 105°), his urine about noon became porter-like, and he began to vomit.

The urine was examined by Dr. Wooldridge, who found a quantity of albumen, but was unable to detect more than one or two red discs in it.

When seen by one of us the patient was lying in bed, pinched, jaundiced, and very debilitated; his tongue was broad and flabby; he suffered from constant nausea and vomited occasionally, the vomited matter being of a bright green colour; the urine, which had been porter-like, had already (the third day of hæmoglobinuria and the fifth day of fever) begun to clear.

Sulphate of quinine and bicarbonate of soda were given by the mouth, and retained; the patient began to feel better almost at once.

A specimen of urine and some blood films were obtained. The urine (collected on the third day of the hæmoglobinuria) had the appearance which is commonly described as "smoky." Albumen was present to the extent of rather more than one part per thousand.

Sugar and bile pigment were both absent. There was a faint band of hæmoglobin, but none of urobilin. The microscopic examination showed a few red blood-discs, a very distinct increase in the leucocytes, a large number of granular casts and renal epithelial cells. Many of the casts contained brownish granules as of hæmatin.

No crystals of any kind could be found. As it was impossible under the circumstances to examine the fresh blood, blood films were made. We stained and examined three. There was, we thought, no increase in the number of leucocytes after allowing for the anæmia. On the three slides nine parasites were found. The hæmatozoa were about a quarter the size of the red discs containing them. None of them contained any pigment. One was definitely ring-shaped. The red discs were not enlarged. No crescents could be found.

The size of the parasites and the absence of pigment eliminated

Digitized by Google

the quartan parasite, and the absence of any increase in size of the discs almost eliminates the tertian one. On the whole, we thought the hæmatozoa resembled those described as the malignant parasites, but, as we have only been fortunate enough to examine the blood of one such case, our knowledge is nearly limited to descriptions.

After five days' improvement the patient had a slight relapse, a return of high temperature, and a single recurrence of smoky urine; quinine was continued.

The urine was examined and was found to contain albumen, though in smaller quantities than on the previous occasion. Sugar and bile pigment were both again absent. Hæmoglobin was present, but again there was no urobilin band.

The microscope revealed a very few red discs, a slight increase in leucocytes, and a few granular casts and renal epithelium. This was a marked improvement on the previous specimen.

Three days after the relapse blood films were again examined. No parasites could be found in any of the films, either intracorpuscular or crescents. There was a marked decrease of the red discs, and in addition a definite leucocytosis; several nucleated red discs were found. Since the relapse the patient has improved, quinine having been administered all the time.

The important feature about this case is that the patient had several attacks of malaria in Africa, but his first attack of blackwater fever occurred in England.

As to the causation of this case of fever there appear to be three possibilities, each of which has been suggested as a cause for the disease.

Firstly, the disease may be unconnected with either malaria or quinine.

Secondly, it may have been produced by quinine.

Thirdly, it may be directly connected with the malaria.

If the first contingency is correct it must follow that the latent period may extend to upwards of a month—the interval which elapsed between the patient leaving Africa and his illness, or that the disease may be acquired in England. These alternatives are, we think, both untenable.

That the disease was caused by quinine we think most unlikely, for the patient only took, and did not retain, five grains of quinine before the hæmoglobinuria developed. During the subsidence of the

Digitized by Google

hæmoglobinuria quinine was given freely, much to the benefit of the patient. It is true that during the administration of quinine a slight relapse occurred, but in consequence of the relapse the quinine was materially increased. Since then the patient has continued to improve, and there has been no recurrence of the hæmoglobinuria.

Plehn says that he thinks that quinine, if given during the convalescence from malaria of blackwater fever, causes, or is likely to cause, a destruction of the red discs and consequent hæmoglobinuria. Koch has gone further, and said that the treatment of blackwater fever by quinine must cease. On the Niger, where one of us (W. H. C.) was stationed for nine years, we are convinced that in the majority of fatal cases of this disease, either the patient does not get sufficient quinine, or if he gets it does not retain it owing to the persistent vomiting, or the patient when first seen has uræmic coma or is actually dying.

Dr. Moffatt, P.M.O. of the Uganda Protectorate, has publicly stated that most of his cases of blackwater fever which recovered were treated with heroic doses of quinine.

We think the evidence against the quinine theory shown by our case is absolute. The attack came on when the patient had not had any quinine, the patient improved when quinine was given, and after the slight relapse he was much benefited by a considerable increase in the amount of this drug given hypodermically. We think that the third alternative, that it is directly connected with malaria, is the correct one.

As far as we know, blackwater fever occurs only in patients resident in, or who have resided in, the malarious tropical countries. A patient has always suffered from malaria, generally many times, before he acquires his first attack of blackwater fever. Those who from any cause do not get malaria do not get blackwater fever.

The usual incidence of blackwater fever is during the second and third years of residence in the malarious districts of tropical Africa, that is, we should suggest, when the patient is run down from several attacks of malaria, and before he is partially acclimatised.

As we have already pointed out, the fever almost, if not quite, invariably supervenes upon an attack of malaria during which the patient has either not been able to lie up or has been exposed to cold or the sun. Plehn says that an attack of blackwater fever may

Digitized by Google

replace an ordinary attack of malaria, and he makes the very significant statement, "Whether in any individual case an attack of blackwater fever occurs instead of a simple malaria (infection with the African malaria being presupposed) depends upon the time of the year, the situation of the residence, and the disposition of the patient." In our case we have found hæmatozoa, and they have been also found by other observers.

Plehn states that hæmatozoa are constantly present in the peripheral blood during the first day or two, but that they disappear from it after the second day. He also points out that the hæmatozoon, while probably being a distinct African species, resembles rather that described as malignant by the Italians than the ordinary quartan or tertian varieties, and he goes on to say that the parasite found in blackwater fever differs in no way from that found in the ordinary malaria endemic in the Cameroons.

We think, therefore, that there can be no doubt that the disease has some definite and close connection with a hæmatozoon.

There appear to be two alternatives left. The first is that there is a special hæmatozoon which causes this disease. This is not impossible, because we know that there are other hæmatozoa than those which cause the ordinary European malaria, of which there are three well-differentiated species. Texas cattle fever and tsetse fly disease are both hæmatozoic, the parasite of the former being singularly like the malignant malarial parasite; this disease, as has been pointed out by Celli and Santori, is cured by large doses of quinine, and hæmoglobinuria is a not uncommon symptom of severe attacks.[1]

The second, that the disease is really a symptom in ordinary tropical African malaria, bearing a similar relationship to that disease that hyperpyrexia does to rheumatic fever. The analogy to this symptom is made still closer when one remembers that the hyperpyrexia of rheumatic fever is not influenced by salicylates or alkalies, but must be treated separately. It seems to us that it is as justifiable to say that salicylates cause the hyperpyrexia, and therefore should not be administered during the continuance of that symptom, as that blackwater fever is caused by quinine.

What we maintain, therefore, is that blackwater fever is to malaria what hyperpyrexia is to rheumatic fever. That quinine

[1] The evidence of Plehn, however, as to the identity of the parasite with that of ordinary African fever is against this supposition.

Digitized by Google

should be administered for the malaria, but that the hæmoglobinuric fever should be treated as a special and extra symptom in a manner analogous to the treatment of hyperpyrexia occurring during the course of rheumatic fever. We are not altogether satisfied that heroic doses of quinine need be administered, but we think that the drug should be administered subcutaneously in order to make certain that the patient retains it.

While this paper was in progress, Dr. F. P. Mackie published in the 'Lancet' of December 3rd, "Notes on a Case of Blackwater Fever."

We note that, having found the parasites in the stained films, he was unable to find them in the fresh specimens; he does not even mention that the extra-corpuscular bodies which were so numerous in the stained preparations were seen. All who have worked at the subject of malaria say how much easier it is to find the parasites in the fresh specimens.

The "considerable number of faded or phantom-like red cells" of which he speaks, may easily be seen in normal blood if the film has not been properly fixed.

He was certainly fortunate to see "a rosette shaped organism which had evidently just broken up" in the peripheral blood twenty-four hours after the last rigor, and we would suggest that "the faintly stained extra-corpuscular bodies, mostly in groups of two and three" were merely blood platelets, which can be easily demonstrated in anæmic, or even normal blood.

Notwithstanding the assertion that the actively motile organisms found after two days in the blood diluted with normal saline were not bacilli because they were spherical, we think that they might have been small oval bacilli. If they were really flagellated forms, the growth of the hæmatozoon outside the body has been demonstrated. We fail to see why the addition of normal saline to the blood should have prevented him from obtaining permanent specimens; it is quite a common practice when examining for bacteria to dilute blood with sterile normal saline solution, in order that it may be spread in a more even film.

We observe that torulæ were found in the urine, but it is quite a usual thing to find them in urine which has been exposed to the air; in fact, it is more usual to find torulæ than the common yeast plant or any other true saccharomyces.

Digitized by Google

Digitized by Google

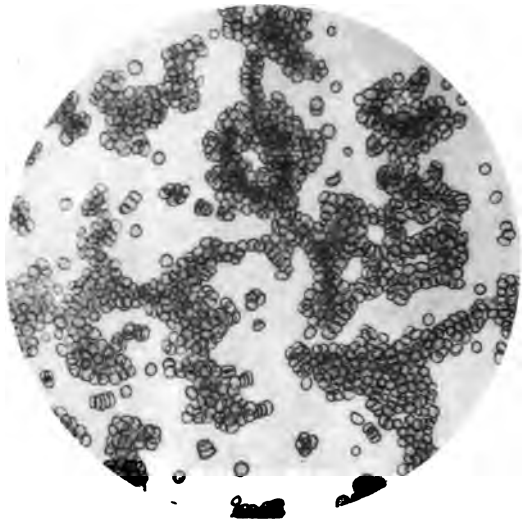

Fig. 1.

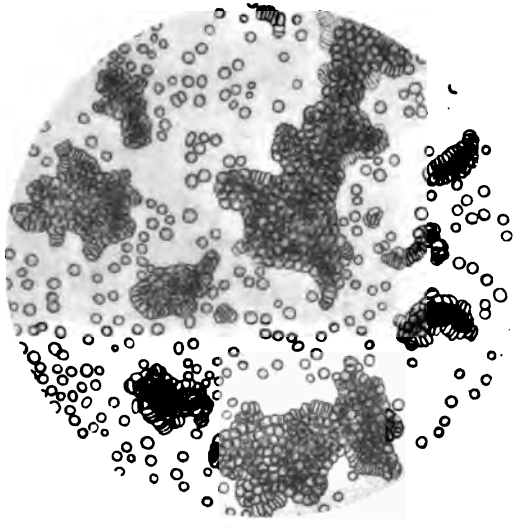

Fig. 2.

Digitized by Google

DESCRIPTION OF PLATE

Illustrating Mr. S. G. Shattock's [illegible] Clumping. (Page 279.)

FIG. 1.—Showing the action of [illegible] blood [illegible] blood. Hanging drop made by [illegible] of [illegible] normal human blood. The [illegible] and [illegible] naked eye in the coarse granularity [illegible] gated into long irregular [illegible] eaux and [illegible] points of which they are massed in irreg[illegible]

FIG. 2.—Showing the action of the [illegible] the blood of a leukaemic patient. The [illegible] into islands of various sizes and irreg[illegible] [illegible]cyte clumps are all leucocytes [illegible] corpuscles held nearly fifteen [illegible]

(Photographs from [illegible]

Digitized by Google

Fig. [illegible]

Fig. [illegible]

Digitized by Google

DESCRIPTION OF PLATE IX,

Illustrating Mr. S. G. Shattock's paper on Chromocyte Clumping. (Page 279.)

FIG. 1.—Showing the action of pneumonic blood-serum upon normal human blood. Hanging drop made by admixing one loop of the serum with one loop of normal human blood. The effect was immediate, and was denoted to the naked eye in the coarse granularity of the drop. The chromocytes are aggregated into long irregular rouleaux and produce a very coarse mesh, at the nodal points of which they are massed in irregular clusters or clumps.

FIG. 2.—Showing the action of the blood-serum in acute rheumatism upon the blood of a leukæmic patient. The chromocytes at once became aggregated into islands of various sizes and irregular form. The elements between the chromocyte clumps are all leucocytes; these remained quite unaffected. The white corpuscles held nearly fifteen times the normal proportion to the red.

(Photographs from drawings by Mr. G. T. Gwilliam.)

Digitized by Google

Digitized by Google

Lastly, we feel convinced that the case is unique in that the presence of granular casts is demonstrated in a urine which contained no albumen. *December 20th*, 1898.

---

6. *Chromocyte clumping in acute pneumonia and certain other diseases, and the significance of the buffy coat in the shed blood.*

By Samuel G. Shattock.

[With Plate IX.]

As a factor in the production of the buffy coat in the coagulation of normal blood, the rouleaux-formation of the red discs or chromocytes has come, at the present time, to be almost completely ignored, the phenomenon being ascribed solely to retardation in the coagulation rate. The coagulating time of cat's blood varies between three and eight minutes, the former being that at which it takes place at the body temperature, the latter at a room temperature of 18° C. (Gregor Brodie); that of horse's blood is stated (after Nasse) to be from five to thirteen minutes. No buffy coat is formed in the first, a thick one is formed in the second. Coagulation, as is well known, may be delayed by cold. What results if the coagulation of the two is retarded for an equal period? The observation can be carried out simply enough by receiving the blood directly from the cat's carotid (from a transverse hemisection made with scissors) into a narrow flat-bottomed tube, say half an inch in diameter, and at once immersing the tube into a vessel of iced water. At the expiration of fifteen minutes there will be above the red mass a thin layer of perfectly clear plasma, which will attain a depth of 2 mm. in a column of blood measuring 35 mm., *i. e.* 5·7 per cent.

The blood is full of surprises. I had imagined that the influence of rouleaux-formation in the production of the buffy coat might be tested in this simple manner. To my astonishment, I found that if horse blood is similarly iced, although coagulation may be retarded, the subsidence of the red mass and the consequent appearance of supernatant plasma instead of being increased is almost completely inhibited; under such circumstances no more plasma appears than in the case of the cat, the amount in either being quite insignificant.

July 10th, 1899.—From a healthy horse (previously tested by

Digitized by Google

Dr. Cartwright Wood with mallein and tuberculin, and about to be used for procuring serum for the preparation of culture media) blood was received from a cannula in the jugular vein into a flat-bottomed tube, half an inch in diameter, the tube being immediately placed in iced water. After twenty minutes (no clotting having ensued) there were but 3 mm. of supernatant plasma in a column of blood 36 mm. in height, *i. e.* 8·3 per cent. (In other instances still less has appeared in the same period.)

I now removed the tube from the iced water: subsidence of the red mass quickly progressed; within eight minutes the upper half of the whole column consisted of clear plasma, and the amount increased before coagulation took place, until it stood at twenty parts in thirty-six, *i. e.* 55·5 per cent.

The striking effect of cold in inhibiting the subsidence of the red corpuscles (a fact which has apparently escaped the notice of physiologists) will best appear from the graphic representations of another observation.

August 1st, 1899.—A horse, which had been three weeks an in-patient at the Brown Institution for a sprain of the shoulder, in the treatment of which a large blister had been applied nineteen days previously over the part, no remains of the therapeutic lesion now persisting. Into a narrow test-tube 5 mm. in diameter, I received directly from the jugular vein without intervening cannula or tube, blood to a height of 46 mm.

At the expiration of five minutes there was a supernatant layer of clear plasma 2 mm. in depth.

10	minutes	. . . .	12 mm. in depth.
15	,,	. . . .	23 ,,
20	,,	. . . .	24 ,,
25	,,	. . . .	25 ,,

By this time clotting had ensued. This gives a proportion of plasma equal to 54 per cent. After cleansing the same tube I at once received from the same jugular of the same horse a column of 50 mm., the tube in this case being kept in iced water before, during, and after the receipt of the blood. At the end of five minutes the clear plasma measured 1 mm. in depth.

10	minutes	. . . .	1 mm. in depth.
15	,,	. . . .	2 ,,
20	,,	. . . .	2 ,,
25	,,	. . . .	2 ,,

Digitized by Google

No clotting had ensued, as seen by tilting the tube in the glass of iced water, when not only the highest limit of the column correspondingly altered its level to maintain the horizontal, but the upper limit of the red mass did precisely the same. On removing the tube from the iced water after thirty minutes subsidence of the red corpuscles rapidly commenced, but coagulation occurred after an ill-defined 7 mm. of plasma had appeared.

The percentage of clear plasma in the uncoagulated iced blood was but 4 as contrasted with 54·3.

FIG. 21.

The figures show the effect of cold in preventing the subsidence of the red corpuscles in horse blood. In each tube the blood was allowed to stand twenty-five minutes, and was still fluid. A. At the room temperature. B. In iced water. The black represents the red mass; the upper line, the higher level of the clear plasma. The actual amount of blood differed slightly in the two observations, but for comparison the proportions have been calculated in equal heights. The level of the fluid is represented, for simplicity, not concave but straight. (Natural size.)

In cat's blood a similar observation made in such an iced tube showed at the end of twenty minutes (no coagulation having

Digitized by Google

occurred) 2·75 mm. of plasma in a column of 55 mm., *i. e.* a proportion of 5 per cent., or practically the same as in the preceding observation on the blood of the horse.

This method of retarding coagulation being therefore unavailable for testing the part taken by rouleaux-formation in the production of the buffy coat, I had recourse to the use of sodium citrate, which, like potassium oxalate, inhibits coagulation by combining with and rendering inert the lime, the presence of which in normal blood is one of the essential factors concerned in coagulation.

Into a 10 c.c. measure containing ·25 c.c. of a 10 per cent. solution of sodium citrate blood was received from the carotid artery of a cat, rolled to ensure mixture, and allowed to stand. For the first ten minutes no subsidence of red corpuscles was discernible; in fifteen minutes a layer of plasma 3 mm. in depth had appeared in a column of 57 mm.; in thirty minutes the layer was 7 mm., *i. e.* 12·2 per cent. Coagulation was completely inhibited.

A similar experiment made with normal horse blood showed within fifteen minutes a layer of plasma 37 mm. in depth in a column of 56 mm.; and in thirty minutes the layer was 39 mm.; *i. e.* 69·6 per cent. as contrasted with 12·2 per cent. in the cat. Better still, as introducing less of what is unnatural, is the observation of Lord Lister's that in "whipped" blood from the horse the amount of subsidence of the red corpuscles in the serum is notably greater than, *e. g.*, in the cow.

The highly pronounced rouleaux-formation in the blood of the horse has long been known, and to this has been ascribed in past times the production of the buffy coat, the element of time having been put into the background as completely as that of rouleaux-formation has now come to be. If one examine blood in the hanging drop (the best method, since fallacies arising from concentration of the serum are obviated, and the rouleaux may be studied just as they form, unmodified by compression) a notable difference appears between that of the cat, *e. g.*, and that of the horse.

The hanging drop of blood from a healthy horse shows on immediate microscopic examination a highly pronounced rouleaux-formation, associated with a widely meshed and knotted field in which there are vacant spaces traversing, it may be, the entire thickness of the drop; the appearance holds throughout the preparation, both, *i. e.*, at the thinner periphery and in the central

Digitized by Google

parts. If one loop of horse blood is mixed with one loop of salt solution, the picture presents the same features; the rouleaux retain conspicuous length and form a coarse knotty mesh, the spaces of which are more vacant owing to the increased volume of the fluid due to the dilution.

The hanging drop of normal cat's or of human blood presents a more closely meshed field, with rouleaux correspondingly shorter; and in either case the effect of dilution is different from that in the horse. If one loop of cat's blood be mixed with one loop of salt solution, the rouleaux-formation is largely inhibited, the piles of chromocytes being quite short, and the mesh very imperfect or discontinuous, whilst at the same time it is finer in correspondence with the shortness of the rouleaux.

When untreated human blood is examined in the hanging drop, and compared with the mixture of an equal proportion of salt solution, the action of the latter is seen to almost completely inhibit the formation of rouleaux; the field is uniformly covered, without lacunæ, the rouleaux being very short and the mesh they produce very close, so close in places as to be quite wanting.

This result may hypothetically be attributed to the dilution of an agglutinating substance normally present in the blood; and it may, moreover, be assumed that in the horse the amount of this substance considerably exceeds that in the human subject, seeing that it will withstand dilution to a notably larger extent before losing its action upon the chromocytes.

I may now pass on to a further observation which I was induced to make for the purpose of seeing whether the serum of horse blood would exaggerate the rouleaux-formation in other blood than that of the horse. Its influence in this respect upon human blood is readily tested in the hanging drop, by placing a loop of serum on a cover-glass and mixing with this a loop of blood freshly drawn from a puncture of the finger made near the root of the nail.

The microscopic examination (best carried out in all cases with $\frac{1}{6}$ obj.) shows an increased rouleaux-formation with the production of a coarsely meshed field, and nodal masses or clumps of chromocytes in the course of the net, the chromocytes appearing as if arranged in knotted strings; not only are the rouleaux longer, but they construct a wider net with vacant intervals, the whole picture contrasting with a preparation of normal human

Digitized by Google

blood admixed with an equal proportion of normal human blood-serum. If the latter control is made, viz. that of mixing one loop of normal human serum (from blood collected in a pipette) with one loop of normal human blood, no such result follows; the hanging drop of such a mixture is not appreciably different from a hanging drop of normal human blood; the rouleaux maintain the same moderate length and produce a uniform and comparatively close net, but markedly less close than that seen in the drop prepared with one loop of normal human blood and one loop of salt solution.

This observation shows that the rouleaux-formation in the blood of the horse is not to be ascribed solely to qualities in the red corpuscles, but that it is due, also, to some property of the serum. And, adopting the terminology in use with regard to the bacterial clumping which ensues under the action of specifically immunised sera, it may be formulated that rouleaux-formation is a phenomenon of agglutination arising from the same cause as that which obtains in the case of bacterial infections, and that the amount of agglutinating substance normally present varies in different animals. As confirming this hypothesis, if we add one loop of normal horse serum to one loop of a twenty-four hours' incubated broth culture of living typhoid bacilli (from which any clumps present have been first removed by filtration through a double cone of Schleicher's paper, and the examination of which, so filtered, shows active mobility and no clumps), notable agglutination or clumping immediately ensues, and within the half-hour limit is so complete that every field is full of bacillary islands. What dilution will the serum withstand? This varies somewhat with different samples: 1 in 20 may or may not abolish the reaction; 1 in 50 will. In the study of such hanging drops there is a possible source of fallacy worth pointing out; the clumps may subside in the drop so as to be discoverable only when its lowest or deep side is brought into focus, the rest of the fluid, it may be, presenting only discrete and mobile bacilli; in control preparations I have noticed this, though the broth culture has been carefully filtered; or, if present elsewhere, the islands may be most numerous in the under side of the drop. The notes of the observations themselves need not be detailed; they were carried out with twenty-four hours' incubated broth cultures of the bacillus, the culture being filtered immediately before use through Schleicher's

Digitized by Google

paper; the time limit adopted was half an hour; control preparations were invariably made, the examination of these being equally prolonged.[1] In one case the agglutination remained well pronounced under a dilution of 1 : 50. At this dilution every field presented many clumps of medium size, whilst the control preparation made at the same time exhibited no clumps whatever, not even at the deepest side, but was full throughout of actively moving bacilli. This result led me to suspect that the horse (an in-patient at the Brown Institution, for a sprained leg) may have been at some time used for the raising of antityphoid serum and afterwards sold for work; the owner had bought it a few weeks previously at a sale, but no further history could be traced.

I was independently led to try and find the action of normal horse serum on typhoid cultures by reason of the highly pronounced agglutination of the chromocytes which naturally occurs in the blood of this animal, and which the serum induces in human blood; though the fact had been previously noticed by Johnson and MacTaggart. The same factor in the serum which leads to the one brings about the other.

There is a further likeness in the two phenomena which I may next refer to. The action of cold in inhibiting the subsidence of the red corpuscles in horse or other blood I have already shown; and I imagine that the result is due not to change in specific gravity but to an inhibiting of rouleaux-formation, for the reason that cold acts in a precisely analogous manner upon a mixture of typhoid culture and normal horse serum. To study this microscopically a cold stage would be necessary, but the effect is readily observable in the gross. Into a flat-bottomed glass tube, about half an inch in diameter, 2 c.c. of an incubating broth culture of typhoid of twenty-four hours' growth were poured, the vessel being then placed in the incubator; and into a similar tube 1 c.c. of normal serum from a horse previously tested with mallein and tuberculin. After the serum had been

[1] Some of the horses had been carefully tested with mallein and tuberculin by Dr. Cartwright Wood at the Tooting horse farm, and by Dr. Dean at the Sudbury one; others were in-patients at the Brown Institution for simple injuries; and I may here acknowledge the kindness with which material and help were placed at my disposal by Dr. Gregor Brodie, Dr. Cartwright Wood, Dr. Dean, and Prof. Rose Bradford.

Digitized by Google

warmed in the incubator it was emptied into the culture, the two being mixed with a warm rod and the tube replaced in the incubator.

To compare: 2 c.c. of the same broth culture in a similar glass tube were cooled in iced water and to these was added 1 c.c. of the same normal horse-serum, previously also iced; mixing was carried out with an iced rod and the vessel afterwards kept immersed in iced water.

The typhoid culture itself was not filtered, and was to the naked eye turbid without visible granularity. I first carefully observed that the icing of the typhoid culture for fifteen minutes *before* adding the iced serum produced no result visible to the eye. What followed? The iced mixture remained uniformly turbid even when viewed with a pocket lens for the entire half-hour during which it was under observation. The incubated tube in the same time had become throughout coarsely granular to the unaided eye.

After fifty minutes, the iced tube remaining free of granularity, I removed it from the bath of iced water, and held it in the palm of my warm hand; within the space of five minutes it grew finely granular, and on transferring it to warm water the granularity became very pronounced during the next five minutes. Subsidence then proceeded, the flat bottom of the tube being covered with a sedimentary layer, and an upper zone of half a centimetre depth becoming cleared after the lapse of about twenty minutes.

In the mixture incubated throughout, after fifty minutes, the granular precipitate was collecting over the bottom of the tube; the upper part of the fluid was clear.

In another experiment with an iced mixture, no trace of granularity having arisen at the expiration of three quarters of an hour, I held the tube in a tumbler of warm water, and watched it with a pocket lens; within five minutes an obvious granularity had arisen, and within fifteen minutes this was so coarse, as to be visible to the unaided eye. The actual descent of the bacillary clumps, however, does not proceed rapidly. In such mixtures whether iced or incubated, even after eighteen hours, when sedimentation is complete, a certain number of granules remain suspended. Sedimentation takes place more rapidly with a typhoid culture that has incubated for forty-eight hours, than with one of twenty-four.

Digitized by Google

Thus a mixture of the same proportions kept at the room temperature, though granular throughout, showed no subsidence at the end of fifteen minutes; in forty-five minutes, the granularity being coarser, sedimentation was in progress; after sixty minutes there was a sedimentary layer at the bottom of the tube, but the fluid was full of coarse granules in suspension; and no further change had occurred in seventy-five minutes. On the day following, the same broth culture, in the meanwhile incubating, was used for an exactly similar experiment. Obvious granularity arose within five minutes. In fifteen minutes sedimentation was in active progress, the fluid being more densely granular towards the bottom of the tube, over which an incomplete layer had formed; in thirty minutes the deposit had much increased; in forty-five minutes, though the fluid was nowhere clear, most of the precipitate had subsided.

The same difference has been observed in the agglutination induced in typhoid cultures of twenty-four and forty-eight hours age by the action of typhoid serum.

This result of cold may be provisionally explained by supposing that it inhibits or retards a process that is, whether in chromocyte or bacillary clumping, essentially chemical.

Lord Lister prefaces his study "On the Early Stages of Inflammation" ('Philosophical Transactions,' 1858) with many observations upon rouleaux-formation in normal blood. He remarks that the formation can have no dependence upon the coagulation of fibrin, since it is immediate, and occurs before coagulation. Again, in corrobation of this, "if a drop of blood is stirred with a needle while coagulation is taking place, so as to remove the whole of the fibrin, the corpuscles, which have been separated from one another by the agitation to which they have been subjected, aggregate again in the serum, in the same manner as they did at first, in the liquor sanguinis."

The formation of rouleaux is attributed by Lord Lister to a certain, not very great degree of adhesiveness of the red corpuscles, and the particular arrangement of the corpuscles, to their discoid form, for "in the frog, although the same tendency to agglutination exists as in mammalia, yet as their biconvex form renders it mechanically impossible for them to be applied to one another throughout their entire circumference, they become arranged in groups of an irregular form."

Digitized by Google

Passing from these physiological considerations, I may re-state the observation made by Wharton Jones, that in the blood of inflammatory diseases, the rouleaux are formed more rapidly, and run into masses which have larger spaces between them. Two figures contrasting this with the rouleaux formation of normal blood are given by Sir James Paget in his 'Lectures on Surgical Pathology' (ed. 3, fig. 35).

The thin clot outspread on the glass has in such diseases, as Sir James Paget states, the peculiar mottled pink and white appearance which John Hunter observed as one of the characters of inflammatory blood. And the production of the buffy coat in such blood was ascribed by Wharton Jones to this closer aggregation, and the more rapid subsidence therefrom resulting ('British and Foreign Medical Review,' October, 1842). This observer examined blood drawn in a case of peritonitis, in one of pericarditis, and in one of pneumonia; in each a buffy coat formed, and a microscopic preparation made from the blood whilst flowing showed an exaggerated rouleaux-formation. Wharton Jones states that this view of the production of the buffy coat in such diseases, was first propounded by Nasse, and afterwards noticed by Rudolph, Wagner and Henle.

Having arrived thus far, I may now record my own observations, which were made with the object of seeing whether the blood serum from patients suffering with acute pneumonia, erysipelas, or rheumatism had any result upon the rouleaux-formation of normal human blood. The blood serum used was in all cases obtained from blood received into pipettes, which were at once sealed in the flame, and kept in the dark for after use.

If we add one loop of the blood serum from a patient suffering from acute pneumonia to one loop of normal human blood, a highly remarkable result ensues in the hanging drop, and one that is strictly comparable to the result I have already described as happening when normal horse serum is added to normal human blood. The blood serum used in the first test was from a woman admitted to St. Thomas's Hospital January, 1899, and taken whilst the temperature was still high, and the physical signs of pneumonia were present. Four pipettes of blood were drawn on February 2nd. On adding one loop of normal human blood to one loop of the pneumonic serum, an immediate result was obvious to the naked eye, the drop appearing as though it held a deep red precipitate in suspension. Under one-sixth objective, the chromocytes

Digitized by Google

were seen to have run together into long rouleaux, which formed a complete, very coarse network, not only at the thinner marginal part, but throughout the drop; at the nodal points the discs were clustered into large knotted masses. Even in the central thickest part of the drop, the net was so coarse and sharply defined, that the lacunæ were quite empty, from the upper focus to the lower.

The action of salt solution upon normal human blood (1 : 1) is, as already described, to almost abolish rouleaux formation and netting. What is the result if normal human blood-serum is added (1 : 1) to normal human blood?

In this control no appreciable difference ensues from the picture presented by normal human blood; the rouleaux maintain a moderate length, and construct a uniform and comparatively close web.

In a second case the blood was drawn in pipettes on May 2nd, 1899, from a well-pronounced case of acute pneumonia with a high temperature; the serum added to normal human blood (1 : 1) gave the same result.

The blood-serum, however, stands very little dilution. If one loop of salt solution is mixed with one of the serum, and to one loop of the mixture is added one of normal blood, the typical picture no longer presents itself, the hanging drop not being appreciably different from that of normal blood.

In none of their experiments have Dr. Washbourn and Dr. Eyre ever obtained a clumping reaction upon the pneumococcus by means of the blood-serum of animals experimentally immunised. Being, therefore, anxious to see whether the serum of pneumonic blood taken from the human subject during life would have any specific action, I made a suspension of the diplococcus on a cover-glass in distilled water,[1] and from this transferred a loop to a second cover-glass to study as a hanging drop. At the same time a second hanging drop was prepared by adding one loop of the pneumonic serum to one loop of the same suspension. For at least twenty minutes no difference was noticeable in the two preparations, but some time within twenty and fifty minutes of their making well-marked clumping ensued throughout in the serum mixture, the bacterial islands

[1] The distilled water is for such and similar purposes best prepared for immediate use by allowing steam from a beaker to condense on the under side of a capsule partly filled with cold water, and quickly inverting the latter so as to bring the under side uppermost.

Digitized by Google

being parted by large clear intervals, whereas the control preparation examined at the same period had undergone no change whatever. This admixture (1 : 1) is, of course, one of high strength, but that the result was specific was shown by treating one loop of a 24-hours incubated and filtered (through filter-paper) broth culture of typhoid with one loop of the same pneumonic serum. Though the examination was prolonged for forty minutes, no similar result ensued; the bacilli remained quite active in large numbers in every field, a very few minute clusters being all that appeared.

I submit, then, that in the production of these results, the same cause, the same change in the serum, which leads to clumping of the pneumococci accounts for that of the chromocytes, and if the hypothesis of an increased amount of "agglutinating" substance meets the first, it may be extended to the second. The formation of a buffy coat in acute pneumonia and other bacterial diseases, in short, may be viewed as a Durham's reaction, the agglutination of the chromocytes leading to their more rapid subsidence, and the clearing of the upper part of the plasma. Or, more accurately, it may be compared with Widal's reaction, seeing that it is obtainable during the period of infection. This interpretation of the phenomenon neither increases nor lessens the difficulty of explaining the specificity of bacterial clumping. It is quite obvious that the mere increase of an agglutinating substance will not account alone for bacterial cohesion, otherwise the result would obtain indifferently in the case of any bacterial cultures.

Some specific interaction between the bacilli of the culture and the blood-serum must be supposed, which brings the agglutination about; the bacilli cannot behave passively under an increase of "agglutinin;" some other, as yet, imperfectly known factor underlies the phenomenon. Such an increase, however, acting upon indifferent elements, such as the chromocytes appear to be, may lead to this abnormal cohesion and exaggerated rouleaux-formation, and in this way to the production of the buffy coat in bacterial diseases.

I may next briefly note the results upon normal human blood of the blood-serum from cases of erysipelas, typhoid, and acute rheumatism.

In *erysipelas* the same result ensues as I have previously described in acute pneumonia. The serum tested was from the blood of a

Digitized by Google

child with a temperature of 103° F., and in whom erysipelas arose at the site of a discharging tubercular lesion of the leg. The mixture of one loop of the serum with one loop of normal blood, was followed by an obvious macroscopic granularity in the hanging drop; and on microscopic examination there was seen to have resulted a widely meshed picture with empty spaces, and dense clusters of chromocytes on the threads of the net, *i. e.* clusters so dense as not to be resolvable into a meshwork, the whole being strikingly different from that obtained in the control hanging drop made at the same time by adding one loop of normal human blood to one loop of normal human blood-serum.

Typhoid.—The result in this disease I have not found quite so pronounced as in either of the foregoing, though a positive and sufficiently obvious one ensues. The hanging drop of an equal admixture of typhoid blood-serum and normal human blood showed throughout, when compared with a control made with normal human serum and normal human blood, a rouleaux-formation of exaggerated length and abnormally coarse mesh.

Acute rheumatism.—I tested the action upon normal human blood, of the blood-serum from a man who had been ill twelve days with acute rheumatism, his temperature at the time the blood was drawn being 103° F., at which date there was also pericardial friction. Equal quantities in the hanging drop, gave nothing very striking on immediate examination, but the picture shortly grew quite characteristic, long rouleaux forming with wide meshes, and coarse clumps, the drop itself becoming notably granular to the naked eye.

Not only does the reaction obtain during the period of infection, but it persists during that of convalescence; for how long I am not able to state.

On March 30th, 1899, blood was drawn into a pipette from a boy who had been admitted for acute rheumatism; the blood was drawn the day after the temperature had fallen to the normal.

One loop of the serum added to one loop of normal human blood in a hanging drop gave immediately an obvious macroscopic granularity, and showed beneath the microscope an abnormally wide and irregular mesh of chromocytes with long rouleaux and large clumps of chromocytes in the course of the net. In this case I again tested the blood serum from blood drawn on the thirteenth day after the fall of the temperature to the normal. The same clumped

Digitized by Google

or knotted picture presented itself. These results show that the change in the serum leading to the increased agglutination persists during convalescence as in the bacterial clumping obtainable in specific infective diseases.

The blood-serum, however, as in the case of pneumonia, withstands very little dilution. If the loop of rheumatic serum is diluted with four of distilled water, and one loop of such a mixture is added to one loop of normal human blood, it produces no such result. Even when one loop of serum is diluted with only one of distilled water, and one loop of the mixture is added to one loop of normal blood, the picture is very little modified from the normal.

Among the leucocytes no cohesion ensues. This can be seen in preparations of the kind described, where leucocytes may be observed lying in the lacunæ of the chromocyte mesh in all degrees of proximity without cohering. But it is most strikingly observable on treating leukæmic blood with, *e. g.*, rheumatic serum. In such circumstances the chromocytes immediately become agglutinated into widely separated islands unconnected with a mesh, of irregular form; the islands consist of rouleaux, but these are so compact as to leave no mesh or only one that is very close; at the thinner marginal part of the drop in such a preparation there may be well-marked rouleaux associated with minute clumps. The leucocytes, on the contrary, however large their numbers, remain quite unaffected.

The serum used in this particular instance was from a man who had been twelve days ill with acute rheumatism, his temperature when the blood was drawn being 103° F., at which time, also, there was pericardial friction.

The cohesion of the red corpuscles was held by Lord Lister (loc. cit., 'Phil. Trans.,' 1858) to constitute an important element in the production of stasis in the vessels of an inflamed part. And I would conclude by asking how far bacterial clumping arising during life may not be responsible for the determination of the lesions met with in the later stages of bacterial disease, *i. e.* at a time when this agglutination may be brought about by the change of the blood which arises in the natural course of the disease itself. The lodgment of such bacterial emboli during the earlier periods of infection would lead to progressive lesions; whilst occurring later, such emboli, though for the time rendered harmless by

Digitized by Google

natural anti-toxinisation, might constitute latent sources of future local recrudescence.

The difficulty of explaining the secondary affections in pyæmia as due solely to vascular thrombosis and the transference of emboli from a primary focus is removed, if the circulating cocci may clump in any parts of the circulatory system, since they might as a result become implanted in situations having no correspondence with an anatomical distribution of vessels related to the seat of a primary vascular thrombus. In fact, given the infection, there is no reason why such bacterial embolism should not avail to cause suppurative lesions without the presence of any primary vascular thrombosis whatever. *February 2nd, May 7th*, 1899.

---

7. *An account of some experiments upon the toxicity of normal urine.*

By W. P. Herringham, M.D., F.R.C.P.

Ever since it became known that renal disease could produce death, the common, and until lately universal, belief ascribed this result to the retention of waste products. They were at first thought to be those excreted, later to be some modification of them produced by retention, and lastly to be some antecedent of them, such as the salts of carbamic acid. Of recent years, indeed, another theory has entered the field, whose supporters maintain that the cause of uræmia is not the accumulation of waste products in the blood, but the perversion or loss of an internal renal secretion. The evidence brought forward in support of this is, however, inadequate.

Those who held the former, still the common view, have lain under the disadvantage that they have never been able to point to any special substance excreted in normal urine, to which could be attached the poisonous properties required to explain the symptoms, while at the same time the means of investigation were of necessity imperfect. For injection of urea or other substances separately, into the blood of an animal, is an experiment open to much error.

Digitized by Google

If we could first prove that the urine itself was poisonous, and could then remove one by one all the substances it contains, leaving the rest each time unaltered, we should by thus changing one alone of the many factors concerned be using the method of difference in its strict form, and should obtain the best form of evidence known to inductive inquiry. But this is not possible. Such an elimination, in which we should remove one "spilikin" out of the heap without touching the others, is chemically out of the question. On the other hand, in the separate injection of each constituent, we alter, not one alone of the many original factors, but all of them save one.

Now the first part of the experiment, the injection of urine into the blood, was performed eighty years ago. The conclusion was then formed, and is held now, that the urine so injected causes death. Whether this injection reproduces the conditions of uræmia, is a question which may for the moment be left unconsidered, while we trace the curious fortunes of this research.

In 1822, Vauquelin and Segalas[1] injected urine directly into the circulation, and stated that it caused death. But their experiments were rightly discredited. They were only two in number. The first was performed on a dog, from which apparently one kidney had been removed, and which had been bled immediately before. About 90 c.c. of urine were injected, and the animal died in ten minutes. The second animal died a fortnight after the injection with double pneumonia and sero-purulent pleurisy. There was probably septic infection at the time of the operation. No weights are given, and no conclusions can be founded on these experiments.

In the same volume Gaspard[2] states that he injected 1½ oz. of fresh human urine, into the jugular of a large dog without serious results. He cites Bichat and Courten as having already done the same. This was apparently before 1812, and I do not know where their performances are recorded. Frerichs[3] many times injected 20 to 40 grms. of filtered human urine into dogs and cats without ill effect.

Thus the opinion was formed that the urine was innocuous when injected into the blood, and in Cohnheim's 'Lectures' (1877), as well as in Voit's article on "Uræmia,"[4] this is taken for granted.

[1] 'Magendie's Journ. de Physiol.,' 1822, tome ii, p. 354.
[2] Ibid., p. 34.
[3] 'Die Bright'sche Nierenkrankheit,' 1851, S. 106.
[4] 'Ztschr. f. Biol.,' München, 1868, Bd. iv, S. 142.

Digitized by Google

The fact was that the doses employed were much too small. But in 1881, Feltz and Ritter [1] published a long series of researches in which they demonstrated conclusively that the urine, whether canine or human, was toxic when injected into the blood of dogs, and, like many others, they yet found that the separate injection of its various organic constituents produced no serious symptoms. Thus they injected urea, urates, hippurates, creatin, creatinin and its salts, leucine, tyrosine, taurin, xanthine, hypoxanthine, and guanin, in far larger doses than could be contained in a fatal dose of urine, yet found no ill effects. After trying inconclusive experiments with dialysis, they at last burnt off from the dry residue of evaporated urine all the organic constituents, and then found that the mineral salts were as toxic, or even more toxic than the original fluid. After experimenting with the various mineral salts contained in it, they concluded that the toxic effects are due to the salts of potassium which it contains, and to nothing else.

At the same time and quite independently Astachewsky [2] reached the same conclusion. In 1883, Schiffer [3] published experiments, the only useful outcome of which was the statement that, of urine freed from mineral salts, it required a litre, to a litre and a half, to kill a large rabbit. In these doses normal salt solution might well prove fatal. Some years later, Bouchard embodied the contents of several papers already contributed to the Société de Biologie and Académie des Sciences in his lectures on auto-intoxication. [4] He fully confirmed the fact of urinary toxicity, gave the average fatal dose of human urine as 60 c.c., and, while allowing that potash salts were to a considerable degree responsible for the result, claimed a share for every other constituent, and in especial for the organic extractives. Assuming these to give to the urine about one third of its poisonous total, he deduced therefrom an elaborate theory of auto-intoxication which will be discussed later. He worked with rabbits.

Albu [5] in the course of his work tried similar experiments, but found the results with rabbits very variable.

[1] 'De l'urémie expérimentale,' Paris, 1881.

[2] 'St. Petersb. med. Wochnschr.,' 1881, No. 27. It is cited by Horbaczewski, 'Wien. med. Jahrb.,' 1883, S. 389. I have not seen the original.

[3] 'Verhandl. d. Ver. f. innere Med.,' 1883–4, Jahrg. 3, S. 13.

[4] Translated by Oliver, London, 1896.

[5] 'Ueber die Auto-intoxicationen des Intestinal-Tractus,' Berlin, 1895.

Digitized by Google

During the last three years I have been engaged in repeating Bouchard's experiments, and in 1898 Beck,[1] who has been at the same task, brought out an important paper upon the subject, whose results will be given later.

I have experimented with rabbits, since it is an easy and painless operation to inject into their large auricular vein. The fine syringe-needle is connected by tubing with a burette, and a steady flow is ensured by a hand air-pump, attached by a perforated cork to the burette. If the injection be too slow, interrupted, or irregular, excretion may so far interfere with the results as to render the experiment valueless. If it were possible, it would be best to vary the rate of injection inversely with the toxicity of the sample, that the fatal dose of the poison might always be placed in the circulation within a uniform time. But our ignorance of the fatal dose of each sample as it comes prevents this, and the next best is to keep the rate uniform for all the series. I have always injected 10 c.c. per minute.

No anæsthetic is necessary. The animal will often remain perfectly quiet throughout the operation. If it is wild, it can be held quiet; to fasten it down disturbs the rabbit, and thereby interferes with the natural evolution of the nervous symptoms. In registering the blood-pressure it is of course necessary to fasten the rabbit.

The urine must be filtered clear. I neutralise it; but in a few cases, whose results I could compare, urine was of the same toxicity when acid and when neutralised. The longest that I have kept it has been when collecting the excretion of twenty-four hours, that is about twenty-six hours from passing the first sample. I have sometimes warmed it to near the body heat, more often injected at the temperature of the room. When the injection is thus performed, the symptoms follow a fairly regular course.

1. When about 20 c.c. have been injected the pupils begin to contract, and the contraction usually increases till they are pin-point.

2. The animal generally gets drowsy. Sometimes this effect is only slight, sometimes the eyes shut and the head bobs just as that of a man asleep in a chair.

3. A sort of muscular twitch begins in the neck. It looks like a

[1] 'Arch. f. d. ges. Physiol.,' Bonn, Bd. lxxi, S. 560.

Digitized by Google

gulping movement. Rabbits do not vomit, but this may be a sort of retching.

4. In many cases the bowels act, sometimes loosely.

5. In many a little urine, up to 30 c.c., is passed; rarely the flow is more copious.

6. The respiration, either with or without previous acceleration, gradually falls in rate; when it falls below 100 there is some embarrassment of expiration. This increases and the rate of breathing falls, till death.

7. Beck's observations on the circulation will be mentioned later. One cannot count the pulse or auscult the heart reliably.

8. As the breathing becomes difficult, the rabbit wakes up and becomes a little restless. A few spasmodic movements of the head usually precede a fit of convulsions, which, beginning with clonic movements of the limbs, quickly end in strong opisthotonos. The animal generally dies in the first fit, but sometimes respiration begins again, and a second, third, or even more occur before death. Fibrillar tremor of the skin may occur at almost any time during the injection, or may be absent.

9. In opisthotonos the eye protrudes, and the pupil often dilates.

After death—

10. If the temperature be taken directly, it will be found to have fallen considerably.

11. If the body be at once opened, the heart will be found universally dilated and full of fluid blood. Flickering contraction occurs here and there, and a touch will produce it. If the examination be postponed for half an hour the heart is found contracted. The brain and lungs are natural, the liver full of blood, the kidneys and spleen natural.

Beck made the following important observations on the blood-pressure and pulse during the injection:

1. The respiration quickens gradually up to a certain point as the urine is injected, and then begins to get slower.

2. Slow injection has little effect on the blood-pressure or pulse-rate.

3. If more rapid the pressure falls and the pulse slows. These effects soon wear off, if the injection be stopped or slowed, and can be reproduced by again quickening it.

4. They are then followed by restlessness, spasms, and sudden stoppage of respiration.

Digitized by Google

5. All these symptoms appear also if the injection be slow, but it needs much larger doses. The blood-pressure falls to zero before death. Respiration stops altogether a little before the last heart-beats, but artificial respiration does not alter the course of events. Section of the vagi makes no difference, so that the heart is affected peripherally. Similar symptoms follow the injection of a solution of the mineral ashes of urine. Similar symptoms follow the injection of an 0·4 per cent. solution of potassium chloride.

That the potash salts were one of the chief poisonous constituents was to be presumed. Their known toxic qualities and the toxic nature of the urinary ash was enough to prove that much. There arose, however, the question whether there was another poison aiding them. Bouchard, introducing the accuracy of mathematics into a subject which is wholly unsuited to it, endeavoured to assign to each constituent of the urine a partial toxicity. Thus, reckoning that the twenty-four hours' urine was capable of killing 461 grms. of living animal, he calculated that—

Potash killed	217 grms.
Soda killed	30 „
Calcium killed	10 „
Magnesia killed	7 „
Urea killed	63 „
Other organic matter	134 „
	461

The astonishment with which we regard this attempt is increased when we find that the quantities from which these values are calculated are not the results of special chemical analysis, but are merely averages taken from the standard physiological text-books. And it may here be said that the minuteness of Bouchard's mathematical calculations can only be valued properly, when it is remembered that neither in his lectures nor in his original papers is any chemical analysis—upon the accuracy of which they must all depend—put forward in their support.

This theory of division of labour rests upon the idea that the effect of small doses is similar to, but weaker than, that of large. That this is not so is known to every physiologist. "The effect of drugs varies very much according to the quantity employed. Sometimes this is due to the interaction of different parts of the body on one another, as already mentioned in regard to veratrine.

Digitized by Google

Sometimes it is due to the different effects upon individual cells or tissues. Thus we find, very generally, that any substance or form of energy, whether it be acid or alkali, heat or electricity, which in moderate quantity increases the activity of cells, destroys it when excessive. But varying doses do not always produce opposite effects. We sometimes find that exceedingly small and exceedingly large doses have a similar effect, which differs from that produced by moderate doses. Thus, very minute quantities of atropia render the pulse somewhat slow; larger quantities make it exceedingly rapid, and very large quantities again render it slow. Moderate doses of digitalis slow the pulse, larger quantities quicken it, and still larger quantities render it slow again."[1]

Apart from this fallacy, which is quite fatal of itself, Bouchard's reckoning is much as if, finding that a man had taken a fatal dose of strychnia in an ounce of whisky diluted with water, we should, remembering that men have died from swallowing a bottle of spirits at a draught, certify that the patient had been poisoned, $\frac{1}{40}$ by alcohol, $\frac{39}{40}$ by strychnia.

Considering for the present purpose the one fact of death alone, I made a series of analyses of urine to see if any factors could be found to vary constantly with the toxic value. In this way I calculated the urea, the uric acid, the mineral acids, in a few cases the lime salts, and the potash. Thinking that if any organic body participated appreciably in the fatal result, it would probably be traceable in that small amount of nitrogen which is not due to the urea or the urates, I calculated also the total, and thus the residual nitrogen.

I soon satisfied myself that no other factor than potassium varied in harmony with the toxicity. But I was long unable to obtain a proportion of this body which should be even approximately constant. I at last became convinced that in the best method recommended by the text-books[2] there is liable to be a loss of potassium, when in the last stage of the process ammonium chloride is being driven off by heat from the dried residue of mixed chlorides, or else too large a result if the ammonium be not fully driven off. I altered the process[3] by distilling off the ammonium as

[1] Lauder Brunton, 'Pharmacology,' 2nd edit., p. 26.

[2] Neubauer and Vogel (Huppert), 10th edit.

[3] My process is described in the 'Journ. Physiol.,' Cambridge and London, 1899.

Digitized by Google

Table I.

No. of experiment.	IN 100 PARTS.														
	Urea.	Nitrogen of urea.	Uric acid.	Nitrogen of uric acid.	Total nitrogen.	Residual nitrogen.	Cl.	P_2O_5	SO_3.			CaO.	K_2O.	Fatal dose per kilo. c.c.	Fatal dose of K_2O per kilo.
									Simple.	Conjugate.	Total.				
1	...	...	0	...	...	...	·3824	0	0	0	0	...	·1734	98	·1699
2	0	...	...	...	...	...	·1778	·225	...	...	Pres.	...	·3430	42	·1440
3	1·693	...	...	...	...	...	...	·11	...	...	·10	...	·2255	93	·2097
4	...	...	0	...	...	...	·55	0	0	0	0	...	·1723	103	·1774
5	0	...	...	...	...	...	·04	·11	...	...	Pres.	...	·2305	81	·1867
6	1·36	·6378	...	...	·756	...	...	·10	...	...	·06	...	·1237	136	·1682
7	1·281	...	...	...	...	...	...	·12	...	...	·12	...	·1326	258	·3421
8	2·282	·958	·0365	·0121	1·0836	·1135	·4053	·2	...	...	·03	...	·2698	75	·2023
9	1·693	...	·0310	...	...	...	·24	·12	·14	·03	·17	...	·2692	66	·1776
10	1·995	·9213	·0376	·0125	1·0710	·1372	·391	·16	...	...	·18	...	·2087	92	·1919
11	1·830	·842	·0323	·0107	·9324	·0797	...	·13	·06	·03	·09	...	·2679	65	·1740
12	1·570	...	·0307	...	...	...	·494	·21	·05	·025	·075	·0218	·2774	71	·1968
13	1·942	...	·0375	...	...	...	·504	·18	...	...	·17	·0503	·3420	43	·1470
14	1·6236	...	...	...	...	...	·514	·12	·08	·04	·12	·0604	·2886	67	·1933
15	1·4996	...	...	...	...	...	·154	·175	...	...	·12	·0404	·1157	>150	>·1735
16	1·4354	·7551	·0320	·0106	·8792	·1135	·348	·15	·09	·02	·11	·0634	·3298	49	·1615
17	1·2990	·5942	·0245	·0081	·7084	·1061	·112	·10	·06	·04	·10	·0339	·1307	90	·1176
18	2·674	1·2348	0	0	1·272	·0372	·46	0	0	0	0	...	·1090	110	·1199
19	0	0	·0695	·0231	·0616	·0385	·348	·15	...	...	·26	Pres.	·3251	47	·1527
20	1·2339	·5697	·0227	·0075	·7000	·1228	·467	·11	·07	·02	·09	·0314	·2506	88	·2204

Notes.—Nos. 1 and 2, 18 and 19, are the alcoholic and watery extracts respectively of two samples of urine.
No. 3 is the original urine of which No. 4 is the alcoholic, No. 5 the watery extract.
Nos. 14 and 16 are the urines of day, corresponding to Nos. 15 and 17, which are those of the night.
In No. 15 the injection was not pushed to a fatal result; the fatal dose is therefore described as greater than 150 c.c.

Digitized by Google

ammonia, and have since then obtained results which appear to me conclusive. I have no doubt that potassium varies constantly with toxicity, and that nothing else does. The results of the last twenty analyses are given in the accompanying table.

The estimation of urea was made by the hypobromite process, corrected for atmospheric pressure and temperature, reckoning 1 c.c. of nitrogen = ·001363 grammes of nitrogen and ·002952 of urea by weight.

The uric acid was estimated by Gowland Hopkin's method. The total nitrogen was estimated by Kjeldahl's method, using $\frac{N}{10}$ sulphuric acid and $\frac{N}{10}$ caustic soda solutions. Chlorine was reckoned by Volhard's method, titrating with $\frac{N}{57}$ solution of silver nitrate, of which 1 c.c. = ·001 grm. Cl; phosphoric acid, by titrating with a solution of uranium acetate, containing 35·5 grms. to the litre; sulphuric acid, by adding gradually barium chloride solution, containing 30·5 grms. to the litre to 100 c.c. of urine boiled with a little HCl, and, after each addition, testing the clear filtrate with mag. sulph.

The simple sulphates were tested in the same way, except that the urine was not heated. The conjugate sulphates were reckoned as the difference between the two results. Lime was estimated by adding ammonia, filtering the precipitate after standing, redissolving with acetic acid and adding excess of ammonium oxalate. After twelve hours standing the precipitate was burnt with the filter to a constant weight.

To the view held by Feltz and Ritter, and by Astachewsky, that death is due to poisoning by potash salts, Bouchard raises several objections.

First, he asserts that there is not enough potash in the urine to produce death in the doses required, and gives the fatal doses of the various salts as follows:

Chloride of potassium,	0·180	grm.	per kilo.
Sulphate ,,	0·181	,,	,,
Phosphate ,,	0·263	,,	,,

As he nowhere gives any chemical analyses of the urines he has used, he appears to have arrived at their contents by guess-work.

In my own estimations the amount of potassium (reckoned as K_2O) in the fatal dose per kilo. lies in all but four instances between 0·1400 and 0·2100 grm. The lower amount would correspond to 0·224 grm. of the chloride, 0·252 grm. of the sulphate or neutral phosphate, and 0·406 of the acid phosphate.[1] Two of the remaining four contain larger, and two smaller amounts. The lowest (No. 17) might have contained 0·188 grms. of potassium

[1] 1 grm. K_2O will form 1·6 grms. KCl, 1·8 grms. K_2SO_4, 1·8 grms. K_2HPO_4, 2·9 grms. KH_2PO_4.

Digitized by Google

chloride alone, or 0·211 grm. of the sulphate, or 0·341 grm. of the acid phosphate. The mixture, whose proportions, it will be remembered, are unknown, would certainly fall little, if at all, short of the required total. The next lowest (No. 18) which contained no sulphates or phosphates had therefore ·191 grm. of the chloride, which is more than required. The lowest of Beck's fifteen estimations contains over ·1400 grm. of K_2O. Direct estimation therefore disposes of Bouchard's first objection. Another series of estimations will be found on p. 315.

It is plain from the table that the proportion of potash is not constant, and the same is confessed by Beck. The highest amount of potash that he found in the fatal dose per kilo. was ·3521 grm., the lowest ·1432 grm. And it is here proper to inquire whether this wide variation obliges us to suppose varying conditions in the urine, or variable reaction in the rabbit. Of this latter factor there is no hint in the writings of Bouchard, nor in those of the many French observers who have followed in his steps. The following tables will show the state of the case.

TABLE II.—*Injection of saline solution of similar rate and under similar conditions.*

Weight of rabbit.	Total injected.	Total retained.[1]	Fatal dose per kilo.
2900 grms. . . .	960 c.c.	900 c.c.	310 c.c.
2850 „ . . .	1550 „	1200 „	491 „
2800 „ . . .	1850 „	1610 „	575 „
2720 „ . . .	1030 „	1030 „	378 „
2650 „ . . .	880 „	850 „	320 „
2530 „ . . .	1560 „	1090 „	430 „
2520 „ . . .	820 „	730 „	210 „
2450 „ . . .	1290 „	1150 „	469 „
2100 „ . . .	850 „	850 „	404 „
In the following cases the rabbits survived:			
2850 grms. . . .	1400 c.c.	1350 c.c.	>477 c.c.
2520 „ . . .	2500 „	1180 „	>468 „
2300 „ . . .	2260 „	1750 „	>760 „

[1] The rabbit is weighed before and after the injection; the increase in weight is taken as the amount retained, the rest escapes by the urine, which is passed profusely. 1 grm. is reckoned at 1 c.c.

Digitized by Google

TABLE III.—*Cases in which the same urine was injected into two rabbits. The injections were made in immediate sequence and under the same conditions.*

Weight of rabbit.	Total injected.	Fatal dose per kilo.	Variation.[1]
2150 grms.	209 c.c.	97 c.c.	6 per cent.
1850 „	193 „	104 „	
2400 „	165 „	68 „	6 „
2300 „	170 „	73 „	
2300 „	93 „	40 „	11 „
2200 „	100 „	45 „	
2660 „	212 „	79 „	12 „
2440 „	220 „	90 „	
2400 „	165 „	68 „	12 „
2300 „	180 „	78 „	
2630 „	163 „	61 „	14 „
2400 „	172 „	71 „	
2090 „	163 „	77 „	16 „
2155 „	200 „	92 „	
1980 „	108 „	54 „	16 „
2150 „	140 „	65 „	
2410 „	175 „	72 „	17 „
2430 „	212 „	87 „	
2350 „	122 „	51 „	19 „
2630 „	168 „	63 „	
3150 „	144 „	45 „	23 „
2660 „	155 „	59 „	
2800 „	115 „	41 „	24 „
2650 „	145 „	54 „	
2870 „	74 „	25 „	30 „
2720 „	100 „	36 „	
2200 „	143 „	65 „	35 „
2220 „	222 „	100 „	
3020 „	133 „	44 „	38 „
3580 „	255 „	71 „	
2785 „	83 „	29 „	39 „
3055 „	150 „	48 „	
2130 „	80 „	37 „	43 „
3450 „	226 „	65 „	
2340 „	78 „	33 „	52 „
2490 „	173 „	69 „	

These are not selected cases; they are all the cases in which I have injected two rabbits with the same urine. Two conclusions may be drawn:

(*a*) That by a large number of experiments a standard may b e

[1] I have taken as the standard the larger fatal dose in each pair. Had I taken the smaller, the variation would have appeared greater still.

Digitized by Google

obtained with an approach to accuracy, for in these eighteen cases twelve vary less than 25 per cent. from one another.

(*b*) That nothing more than this must be expected, and that wide variations will occasionally be met.

A third follows from the fact mentioned on a previous page:

(*c*) That these variations will tend to be wider the weaker the urine in potash.

Bouchard, secondly, asserted that the urine killed by stoppage of the respiration, and not, like potash salts, by heart failure. That this is not the case has been shown by Beck.

Thirdly, Bouchard objects that if potash were alone responsible the solution of the mineral ash[1] should not be less toxic, as it sometimes is, but should have the full toxic value of the parent urine. But he apparently does not remember that in the process of incineration the chloride, which is the most toxic of the potash salts, would partly volatilise, and he does not seem to have analysed the ash solution to see if the potash content is the same or not. The following are such analyses, which show a loss of potash proportionate to the loss of toxicity:

TABLE IV.

1.	Urine . .	K_2O ·3641 per cent.	Fatal dose per kilo., 41 and 54 c.c.[2]	
	Ash solution .	,, ·2970 ,,	,, ,,	57 ,,
2.	Urine[3] . .	,, ·2679 ,,	,, ,,	65 ,,
	Ash solution .	,, ·2145 ,,	,, ,,	66 and 87 ,,
3.	Urine[4] . .	,, ·2506 ,,	,, ,,	88 ,,
	Ash solution .	,, ·2248 ,,	,, ,,	124 ,,

There is, indeed, a remarkable difficulty about the effect of this solution of the ash, but it is very different from that raised by Bouchard. It was noticed by Feltz and Ritter, by Bouchard himself, and by Beck, that the ash solution is sometimes not less

[1] The dry residue of evaporated urine is fused on platinum, and the crystalline product treated with hot water. It will not all dissolve. Filter and make up the filtrate to the original volume by repeatedly washing the precipitate on the filter. The filtrate is clear and alkaline, contains chlorides, phosphates, and sulphates, with alkalies, but gives no precipitate with ammon. oxalate. The precipitate on the filter dissolved in acetic acid gives a copious precipitate with excess of ammon. oxalate.

[2] Where two values are given two rabbits were tested.

[3] No. 11 in Table I.

[4] No. 20 in Table I.

Digitized by Google

but more toxic than the original urine. The following instances have occurred in the course of my injections:

TABLE IV—*continued.*

4.	Urine . .	K_2O	—	per cent.	Fatal dose per kilo.,	54 and 65	c.c.
	Ash solution .	„	—	„	„ „	36	„
5.	Urine . .	„	·1584	„	„ „	109	„
	Ash solution .	„	·1418	„	„ „	45	„
6.	Urine . .	„	—	„	„ „	77 and 91	„
	Ash solution .	„	—	„	„ „	41 and 46	„
7.	Urine . .	„	—	„	„ „	71	„
	Ash solution .	„	—	„	„ „	58	„

In these last four cases there has been present, during the injection of the ash solution, a symptom that I have never seen except in them,—slow, irregular spasms of various parts, one after the other, resembling the "athetoid" movements seen in old cases of hemiplegia.

On the other hand, in the three cases before given, and in the following:—

8.	Urine[1] . .	K_2O	·3420	per cent.	Fatal dose per kilo.,	43	c.c.
	Ash solution .	„	—	„	„ „	52	„

the toxicity has been what might have been expected, a little less than that of the parent urine, and there have been none of these curious "athetoid" spasms. To what they and the great increase of toxicity are due I do not know. Bouchard suggests that the carbonates are increased; but when I tested the ash solution by acidulating, boiling, and passing the vapour through baryta water, the reagent was only rendered faintly opalescent. They could only increase at the expense of the chlorides, and the toxicity of the two is described as equal by Ringer.[2] Beck thinks that the absence of urea prevents urination, and that, the whole of the potash being now retained, the solution kills more quickly than the urine. But, at the rate at which I inject, my rabbits never pass more than a few c.c., often none; and moreover, they sometimes urinate during the injection of the ash solution. A second suggestion of Bouchard is that the organic constituents burnt off in calcination counteract the potash salts. In any case the effect is not constant.

[1] No. 13 in Table I.

[2] 'Handbook of Therapeutics,' 12th edition, p. 177.

Digitized by Google

Others do not mention these peculiar convulsions that I have seen, so that they may have been accidental, but it is odd that they should have occurred in those very cases wherein the poison was greatly stronger. There is a certain curious antagonism between lime and potash salts, and I thought once that the absence of lime might heighten the effect of the potash, but the idea was not borne out, either by direct experiment or by the other cases in which the ash solution produced no such symptoms, though it was destitute of lime.

Bouchard's fourth objection is that urine filtered through animal charcoal loses one third of its toxicity, but only one sixteenth of its potash. In the absence of all detail, and in the absence of any chemical analysis, I have not thought it worth while to repeat this experiment. Every chemist knows that this carbon behaves very variably when used in different ways, and that it is impossible without direct analysis to say what is in the filtrate, or, what, or how much, is retained.

Fifthly, he objects that if evaporated slowly, urine becomes not proportionately, but absolutely more toxic, which he ascribes to changes in organic compounds. But this is a known law for potash salts.

"The poisonous action of potassium, sodium, ammonium, and some other salts depends mainly on the percentage dose, not on the total amount conveyed to the heart. In experiments on the frog's heart, when sufficient of the fluid is added to the circulating blood to cause arrest of contractility, this annulled property can be restored by diluting the blood with an equal quantity of saline solution, so that the ventricle receives the same quantity of the salt, but in a more diluted form."[1]

It has been maintained by Mairet and Bosc[2] that a large part of the fatal effect was due to the pigments, which they obtained by precipitating with lead subacetate. This precipitate, extracted and purified, they re-dissolved in water and injected. But the precipitate so prepared is not pure,[3] and its effects cannot be considered as those of the pigment. Lapicque and Maretti[4] found no con-

[1] Ringer, 'Handbook of Therapeutics,' 12th edition, p. 129.

[2] 'Arch. de physiol. norm. et path.,' Paris, tome iii, p. 273.

[3] A. E. Garrod, "A Contribution to the Study of the Yellow Colouring Matter of the Urine," 'Proc. Roy. Soc. London,' vol. lv, p. 394.

[4] 'Compt. rend. Soc. de Biol.,' Paris, 1894, sér. 10, tome i, p. 598.

Digitized by Google

nection between the degree of colour tested by the colorimeter and the degree of toxicity.

Dr. Archibald Garrod was so good as to give me a specimen of the yellow pigment of the urine (urochrome is the name given it by its first discoverer, Thudichum) dissolved in alcohol. He could not tell me the exact quantity of urine employed to obtain it, but it was many hundred cubic centimetres.

To dissolve this in distilled water (after evaporation of the alcohol) would have produced a fluid so unlike the normal urine that injection would have given no certain results. I preferred, therefore, to dissolve it in urine. The result was as follows:

1. RABBIT.—Weight 1870 grms.; temperature 102·4° F. Urine at temperature of room was injected into the auricular vein.

At 10 c.c.—The pupils began to contract.

At 30 c.c.—Twitching of neck muscles; respiration slower.

At 50 c.c.—Respiration still slower and a little embarrassed; slight stool and a very little urine.

At 85 c.c.—Convulsions; exophthalmos.

At 86 c.c.—Pupil a little dilated; death.

Duration of experiment eleven minutes; temperature at death 102·6° F.

2. RABBIT.—Weight 1870 grms.; temperature 102·8° F. Same urine.

At 20 c.c.—The pupils began to contract.

At 30 c.c.—Twitching of neck muscles.

At 40 c.c.—Respiration slower.

At 80 c.c.—Respiration irregular; a slight stool and a little urine.

At 122 c.c.—Convulsions; exophthalmos.

At 125 c.c.—Convulsions; pupils widely dilated; death.

Duration of experiment sixteen minutes; temperature at death 102·6 F.

3. The yellow pigment described above, dissolved in alcohol, was evaporated below boiling-point on a water-bath, and was re-dissolved in 200 c.c. of the same urine.

RABBIT.—Weight 1550 grms.; temperature 101·6 F.

At 25 c.c.—The pupils began to contract.

At 55 c.c.—Twitching of neck muscles.

At 90 c.c.—Respiration very low.

At 95 c.c.—Convulsions began.

At 100 c.c.—Exophthalmos; pupils dilated; death.

Duration of experiment fourteen minutes; temperature at death 101° F.

The post-mortem was made carefully in each case, and the organs were natural. The heart was dilated in the last case, the body being opened immediately; but in the first two, which were made nearly an hour after death, it was contracted. This I have always found to occur after this interval.

The toxic values were—(1) 45·98 c.c. per kilo.; (2) 66·84 c.c. per kilo.; (3)

Digitized by Google

4·51 c.c. per kilo. Thus the addition of more than double the previous amount of yellow pigment did not increase the toxicity. The absence of any loss of temperature in the first two is a very uncommon thing. The experiment was done in June, 1896.

A similar experiment was performed with uroerythrin. I need not give full details. The injection was made on 9th July, 1896, a very hot day.

1. RABBIT.—Weight 1680 grms.; temperature 103·2° F. Normal urine killed, with convulsions, at 83 c.c.; duration of experiment twelve minutes; temperature at death 103·4° F.

2. RABBIT.—Weight 2050 grms.; temperature 103·6° F. The same urine killed, with convulsions, at 112 c.c.; duration of experiment thirteen minutes; temperature at death 103·6° F.

3. To 200 c.c. of the same urine ·0080 grm. of uroerythrin was added. This had been given me by Dr. Garrod. It was extracted by him[1] in alcohol, kept in a coloured stoppered bottle in a dark place, evaporated in a dark room at 38° C., and re-dissolved in the urine.

RABBIT.—Weight 2120 grms.; temperature 102·4° F. 127 c.c. were injected. The respiration was now slow and irregular. As the purpose of the experiment was fulfilled, the injection was stopped, and the rabbit recovered.

The toxic values were as follows:—(1) 49·40 c.c. per kilo.; (2) 54·63 c.c. per kilo.; (3) more than 59·90 c.c. per kilo.

A similar experiment was performed with urobilin in June, 1896.

1. RABBIT.—Weight 2400 grms.; temperature 104° F. Normal urine killed, with convulsions, at 165 c.c.; duration of experiment fifteen minutes; temperature at death 103·2° F.

2. RABBIT.—Weight 2300 grms.; temperature 102·8° F. The same urine killed, with convulsions, at 170 c.c.; duration of experiment twenty-four minutes; temperature at death 102·2° F.

3. To 200 c.c. of this urine was added the urobilin extracted by Dr. Garrod[2] from a much larger quantity of urine. It had been preserved in chloroform and alcohol, was evaporated on a water bath, and was dissolved in the urine by heating.

RABBIT.—Weight 2200 grms.; temperature 102·8° F. This urine was fatal, with convulsions, at 172 c.c.; duration of experiment twenty-three minutes; temperature at death 102° F.

Toxic values:—(1) 68·75 c.c. per kilo.; (2) 73·91 c.c. per kilo.; (3) 78·63 c.c. per kilo. The post-mortem examination was made in every case with a negative result.

These experiments, made with the purest pigments hitherto extracted from urine, prove that their addition in quantity, which

[1] For his method see 'Journ. Physiol.,' Camb. and Lond., vol. xvii, p. 439.

[2] For his method see ibid., vol. xx, p. 112.

Digitized by Google

is proportionately very large, does not increase the toxic value of normal urine.[1]

But the actual cause of death was not the only point on which Bouchard held novel views.

He asserted that the urine of sleep differs from that of waking hours, both in the quantity and the quality of its poisonous property; that the urine of sleep is less toxic, and is also more convulsant than that of day; and that if the two be mixed the toxic value of the mixture will not be equal to, but less than, that of the proportionate mean between the two. He founded upon this an ingenious theory that sleep was the result of a chemical poisoning. During the day he supposed mankind to form a narcotic substance within their system which, gradually accumulating in the blood, made them sleepy; while during sleep, "a convulsive substance is elaborated, which, when accumulated, could produce muscular twitchings and induce waking."[2] As usual, he produced no chemical grounds for this view.

The following cases show—

(*a*) That the urine of night is less toxic than that of day in proportion as it contains less potash.

(*b*) That there is no such qualitative difference as Bouchard claims, but that both somnolence and convulsions occur in equal proportion with each urine.

1. Urine, 8 a.m. to midnight, 1190 c.c.; clear, amber, acid; sp. gr. 1015; urea 1·3 per cent.; uric acid ·0391 per cent. RABBIT 2850 grms. Fatal dose 280 c.c. = 98 c.c. per kilo. Somnolent till just at the end, when it had the usual convulsions and died.

Urine, midnight to 8 a.m., 450 c.c.; slightly hazy, amber, acid; sp. gr. 1022; urea 2·1 per cent.; uric acid ·0734 per cent. RABBIT 2700 grms. Fatal dose 290 c.c. = 107 c.c. per kilo. Somnolent till just at the end, when it became convulsed and died.

2. Urine, 8 a.m. to midnight, 795 c.c.; clear, amber, acid; sp. gr. 1020; urea 2·1 per cent.; uric acid ·056 per cent. RABBIT 3010 grms. Fatal dose 150 c.c. = 49 c.c. per kilo. Somnolent until 120 c.c. At 140 c.c. convulsions began, which ended in death.

Urine, midnight to 8 a.m., 615 c.c.; turbid, pale, amber, neutral; sp. gr.

---

[1] The toxic values given above must not be taken as the toxic value of the excretion of twenty-four hours. The urine was that passed during a part only of the day.

[2] Oliver's translation, p. 41.

Digitized by Google

1016; urea 1·7 per cent.; uric acid ·060 per cent. RABBIT 1960 grms. Fatal dose 300 c.c. = 153 c.c. per kilo. Slight drowsiness only, and for a short time. At 300 c.c. there were slight convulsions, ending in death.

3. Urine, 8 a.m. to midnight, Oct. 28, 1897, 870 c c.; clear, amber, acid; sp. gr. 1020; urea 1·9 per cent.; uric acid ·070 per cent.; K_2O ·3182 per cent.[1] RABBIT 2360 grms. Fatal dose 180 c.c. = 76 c.c. per kilo. No somnolence. Convulsions began at 170 c.c., and ended in death.

Urine, midnight to 8 a.m., Oct. 28, 1897, and the same hours, Oct. 29, 1090 c.c.; slightly turbid, pale, amber, slightly acid; sp. gr. 1013; urea 1·7 per cent.; uric acid ·043 per cent.; K_2O ·1098 per cent. RABBIT 2710 grms. Fatal dose 400 c.c. = 147 c.c. per kilo. Drowsy from 60 c.c. to 300 c.c. Death with convulsions. RABBIT 1900 grms. Fatal dose 370 c.c. = 184 c.c. per kilo. Drowsy from 70 c.c. to 270 c.c. Convulsions began at 300 c.c., and occurred at intervals until death.

4. The analyses are given in Nos. 14 and 15 of the table. Urine of 8 a.m. to midnight, Jan. 17—No. 14. The RABBIT, 3070 grms., was drowsy from 40 c.c. to 100 c.c. Convulsions occurred at 170 c.c., and were repeated at 190 c.c., when they proved fatal. Urine of midnight to 8 a.m., Jan. 17 and 18—No. 15. The RABBIT, 2720 grms., was drowsy from 30 c.c. to 70 c.c., and again from 190 c.c. to 300 c.c. No convulsions occurred before 420 c.c., when the experiment was stopped.

5. The analyses are Nos. 16 and 17 in the table. Urine of 8 a.m., to midnight, Feb. 5—No. 16. RABBIT 1098 grms. No somnolence. Convulsions began at 80 c.c., and were fatal at 98 c.c. Urine of midnight to 8 a.m., Feb. 5 and 6 —No. 17. RABBIT 1760 grms. Drowsy throughout the injection until at 150 c.c. convulsions began, which ended in death at 159 c.c.

Beck performed many more experiments on this point than I, and entirely confirms the second of my conclusions. He does not appear to have made comparative chemical analyses of the two urines. But he did what I find I have omitted, namely, mixed the urines, and found that the toxicity of the mixture was actually the proportional mean of the toxicity of its components. In this point also, therefore, he was unable to confirm Professor Bouchard's statements.

Bouchard further attempted to establish the existence of many poisons in the urine, each with its appropriate and peculiar symptom. Firstly, there is a diuretic substance; secondly, a narcotic; thirdly, a sialogenous; fourthly and fifthly, two convulsant substances; sixthly, something that produces miosis; and, lastly, a body that reduces temperature. The simplest way to consider them is to consider the various symptoms which occur during the injection.

[1] Analysis by old method.

Digitized by Google

1. Miosis nearly always occurs with urine. It begins quite early and becomes extreme. In four different urines, extracted by alcohol after evaporation, I have never seen it occur either with the alcoholic or with the watery extract. It does not occur with the solution of the ash. It is said not to occur with urine that has been boiled.[1] I have several times distilled urine, and find that the distillate does not produce it. Once I made up the residue, which had been boiling a long time, to its original volume with water, and after filtration injected it. This urine contracted the pupil; but it is the only note that I have on this point with boiled urine. Miosis may occur at the end of large injections of saline solution, but this is probably from some cause quite other than in the case of urine. It occurs with all urines, whether of herbivora or carnivora.[2]

2. Urination has usually, not always, occurred during the injection. The amount has been insignificant, perhaps because my experiments have rarely taken so long as twenty minutes. The urine so passed does not contain the poison,[3] and hardly any urea. Out of eight injections of ash solution, urine has been passed in four. It has occurred both with the alcoholic extract which contains all the urea, and with the watery which contains none. It occurs profusely with large injections of saline solution, and it occurred with injections of sulphate and chloride of potash dissolved in saline solution. It has, therefore, no special significance.

3. The passage of fæces, in which the motion has sometimes been very loose, has often occurred during injection of urine, and also in injections of the alcoholic extract; but I have not seen it either with the watery extract or with the solution of the ash. It is quite possible that urea may play a small part in producing these two symptoms.

4. I have only noted salivation in injections of the alcoholic extract, and in one urine, No. 3 in the table.

5. Drowsiness occurs very commonly with urine; it occurs with injections of the ash solution, and it occurs with injections of potash salts dissolved in saline solution.

6. Convulsions occur with urine, with alcoholic and watery extracts, with the ash solution, and with salts of potash dissolved

[1] Lapicque and Maretti, 'Compt. rend. Soc. de Biol.,' Paris, 1894, sér. 10, tome i, p. 598.

[2] Guinard, 'Compt. rend. Soc. de Biol.,' Paris, 1893, sér. 9, tome v.

[3] Guinard, ibid., p. 489.

Digitized by Google

in saline solution. They often begin with backward jerks of the head. A measure of their prevalence in any experiment may be made by noting the point at which the first of these spasmodic jerks takes place, and the point at which death occurs. Reckoning in this way the last twenty cases, which are those given in the table, I can find no strict rule.

TABLE V.

No. 15	had no convulsions;	420 c.c.	were injected.	The rabbit survived.		
„ 19	had one convulsion	at death.	Total given,	100 c.c.		
„ 8	„	„	„	„	203	„
„ 2	had convulsions	for the last	5 c.c.	„	105	„
„ 18	„	„	„	8 „	„	83 „
„ 17	„	„	„	9 „	„	159 „
„ 12	„	„	„	10 „	„	130 „
„ 16	„	„	„	18 „	„	98 „
„ 20	„	„	„	18 „	„	228 „
„ 14	„	„	„	20 „	„	190 „
„ 10	„	„	„	28 „	„	155 „
„ 3	„	„	„	30 „	„	240 „
„ 11	„	„	„	30 „	„	145 „
„ 1	„	„	„	30 „	„	245 „
„ 4	„	„	„	34 „	„	234 „
„ 6	„	„	„	40 „	„	300 „
„ 5	„	„	„	50 „	„	190 „
„ 9	„	„	„	50 „	„	120 „
„ 18	„	„	„	172 „	„	260 „

It is obvious that, though there is a slight tendency for the weaker urines to allow longer time for convulsions before they produce death, yet this has many exceptions.

Death always, in my experience, occurs with some convulsive movement.

7. The loss of temperature is almost always found, but not always.

With injections of 1400 to 1800 c.c. of saline solution, warmed nearly to blood heat, the loss is only about 1·3° C., though the injections took more than an hour. With injections of urine warmed to the same heat the loss varies from nothing up to 1° C. With injections of urine, at a temperature of the room, the loss varies from 0·4° C. to 2·7° C., but of twenty-one cases only two lost as much as 2° C.

Guttmann thought that potash salts lowered temperature, but

Digitized by Google

this seems uncertain. At any rate, the injection of a mass of cold fluid, together with the weakening of the circulation and embarrassment of breathing, are quite enough to account for the loss. Bouchard elaborately calculates that the calorics subtracted by the injection are insufficient, but appears to take no account of the fact that the heat-producing organs are crippled.

On a review of the whole, I see no valid ground for concluding that any urinary constituent but potash is actively concerned to produce any of these symptoms, with the single exception of miosis. This is as yet unexplained.

I have already alluded to Bouchard's statement, that a healthy man of 60 kilos. excreted in the twenty-four hours sufficient urinary poison to kill 24 kilos. of rabbits. With a pretence of mathematical accuracy which frequently disfigures his lectures, he calculates that, if that be the case, each kilo. of the man will excrete enough to kill 0·4 kilos. of the rabbit. The dose that is fatal to a kilo. he has named a "urotoxy," and the amount of poison excreted by each kilo. per diem he calls the "urotoxic coefficient." The standard thus set up has obtained a considerable vogue in France, and I have seen it quoted in American publications, but I am not aware that it has been treated seriously in Germany or in England.

It has already been shown that the urinary toxicity is, in the healthy subject, merely an inexact expression of the excretion of potash. The injection of rabbits can, therefore, never take the place of chemical analysis. But it is as well also to examine how far the "urotoxic" excretion bears out the possibility of fixing a standard for health. The following table is calculated from the results of injection in a healthy man of 11 stones (70 kilos.), who enjoyed excellent health throughout, and who led an active professional life. The total of urotoxies excreted is calculated from the dose of the urine fatal to the kilo. of animal, and, where two injections were performed, from the mean of the two results. (See Table VI.)

These three series, exclusive of the days on which citrate of potash was taken for experiment, were conducted under conditions of uniformity as great as, and in the last case greater than, occur in ordinary life. Dining well means four or five courses with a pint of champagne or some other wine; frugal diet means very little meat once a day and no wine.

Digitized by Google

TABLE VI.

Date.	Excretion.	Remarks.
1896.	Urotoxies.	
March 15 . .	27·3	Dined sparingly.
,, 16 . .	30·2	Dined well.
,, 17 . .	22·2	Dined well.
,, 18 . .	23·5	Dined well.
,, 19 . .	24·3	Dined sparingly.
,, 20 . .	15·2	Dined sparingly.
,, 21 . .	...	Dined sparingly. Half a day's exercise in country.
,, 22 . .	16·5	Dined sparingly.
,, 23 . .	19·8	Dined sparingly.
,, 24 . .	18·9	Dined sparingly.
,, 25 . .	19·5	Dined well.
,, 26 . .	24·1	Dined well.
,, 27 . .	26·9	Dined well.
May 4 . .	27·8	Dined sparingly.
,, 5 . .	16·4	Dined sparingly.
,, 6 . .	21·5	Dined sparingly.
,, 7 . .	31·5	Dined sparingly. Pot. citrat., 2 drms. during the day.
June 1 . .	20·5	Very frugal.
,, 2 . .	22·6	Very frugal.
,, 3 . .	20·2	Very frugal.
,, 4 . .	36·2	Very frugal. Pot. citrat., 1 drm. during the day.
,, 5 . .	17·3	Very frugal.
,, 6 . .	...	Dined well.
,, 7 . .	16·8	Very frugal.
,, 8 . .	17·1	Very frugal.
,, 9 . .	15·2	Very frugal.
,, 10 . .	17·2 or 25·7[1]	Dined well.
,, 11 . .	23·7	Dined well.

During the first series the potash was estimated for me.[2] The results are given below with the fatal dose per kilo. (See Table VII.)

It is plain from these figures that even with the diet of ordinary life the excretion may vary from 27·8 to 15·2 urotoxies per diem, a variation too wide to admit of any standard. But in sick persons the diet is even more restricted, and therefore the excretion will be still lower. Thus in a man æt. 38, who lay in the hospital with symptoms of pressure on his left bronchus, due to a small aneurysm,

[1] Very discrepant results from injections.

[2] I do not know the method employed in the analysis.

Digitized by Google

TABLE VII.

Date.	Fatal dose per kilo.	K_2O per cent.	K_2O fatal per kilo.
March 15 . .	61·9 c.c. and 71·6 c.c.	0·316	0·1956 g.[1]
„ 16 . .	40·4 c.c. and 45·4 c.c.	0·335	0·1353
„ 17 . .	97·2 c.c. and 104·3 c.c.	0·217	0·2109
„ 18 . .	51·9 c.c.	0·330	0·1712
„ 19 . .	87·5 c.c.	0·224	0·1960
„ 20 . .	115 c.c.	0·215	0·2472
„ 22 . .	79·6 c.c. and 90·1 c.c.	0·294	0·2340
„ 23 . .	51·9 c.c. and 63·8 c.c.	0·347	0·1800
„ 24 . .	68·7 c.c. and 78·2 c.c.	0·279	0·1916
„ 25 . .	116·4 c.c.	0·188	0·2188
„ 26 . .	50·5 c.c.	0·405	0·2045
„ 27 . .	53·8 c.c.	0·328	0·1764

who took the *dieta dimidia* of the hospital, and was treated with small doses of potassium iodide, the excretion was—

Oct. 22	13·3 urotoxies.
„ 25	20·9 „
„ 27	14·5 „
Nov. 3	17·0 „

Another man, æt. 29, who was suffering from neuromimesis, and who was living upon the same diet and took no drugs, excreted—

Dec. 30	14·5 urotoxies.
„ 31	9·0 „
Jan. 1	8·0 „

I have little doubt that rest in bed, by lessening both tissue change and appetite, will greatly lower the potash excretion of any person, and, since we do not know to what extent this takes place, we must conclude that, even though a standard were possible in health, which it is not, it could not be usefully applied to disease.

A last question remains, whether the symptoms produced in animals by intra-venous injection of urine can be compared with those of uræmia. It is obvious that there is no necessary connection between the two, for the circumstances are different, and, though the symptoms found in the one are certainly found in the other, yet this may be but an example of the well-known rule that similar effects may have many different causes. I propose to put the question to the test of analysis, but the difficulties attending

[1] Reckoned from the smallest dose fatal.

Digitized by Google

such an investigation are so great and so numerous, that the result must be very doubtful. I am not unaware, moreover, that such analyses have, to a small extent, been already made without leading to any positive conclusion. *March* 21*st*, 1899.

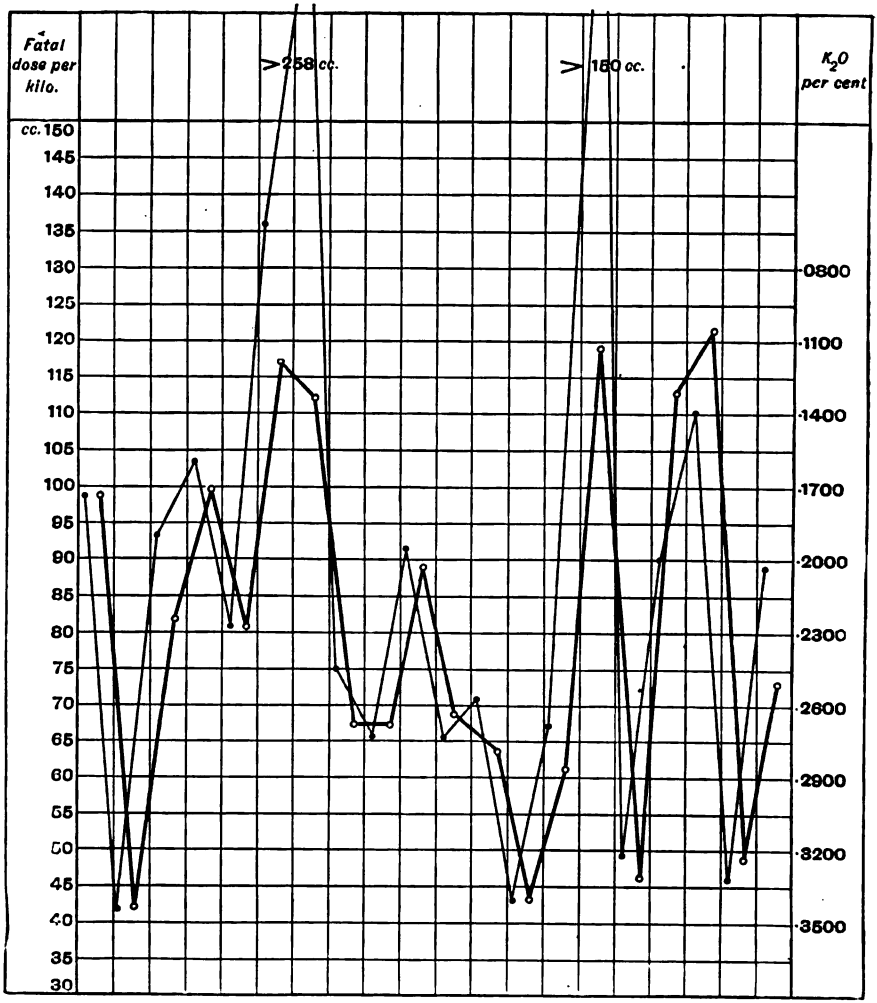

CHART I shows the percentage of potash, marked by crosses, and the fatal dose per kilo, marked by dots, in the twenty cases given in Table I. The order is that in which they were performed.

Digitized by Google

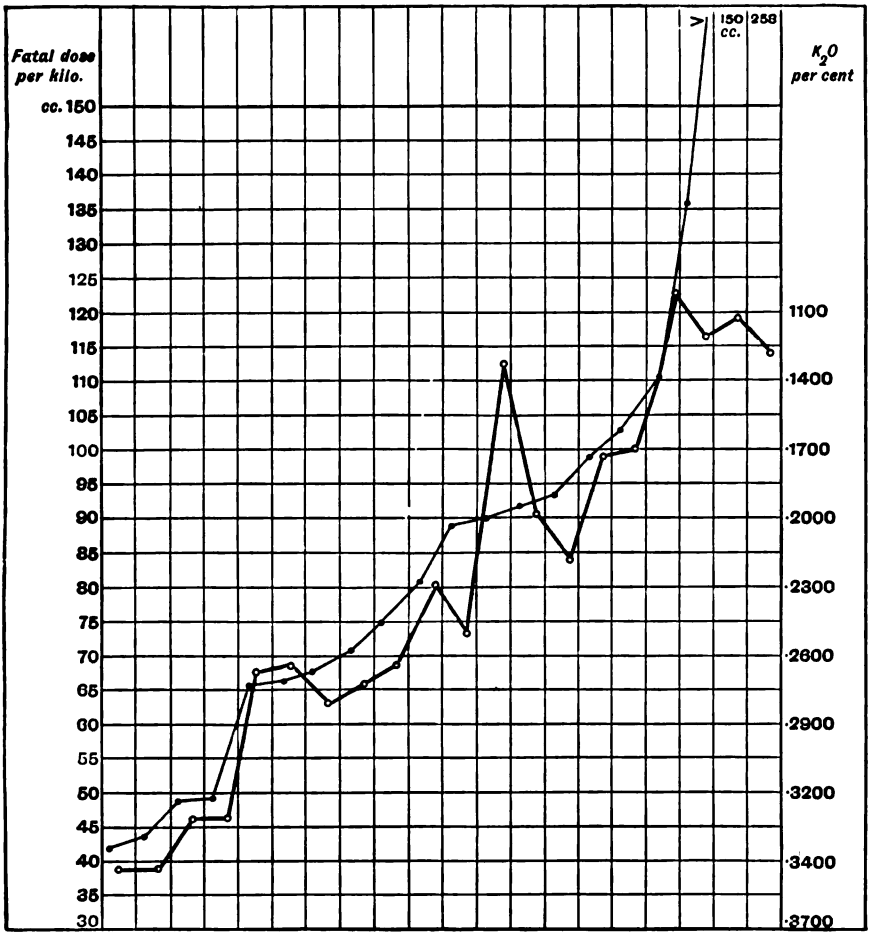

CHART II gives the same results, but arranged according to the fatal dose.

Digitized by Google

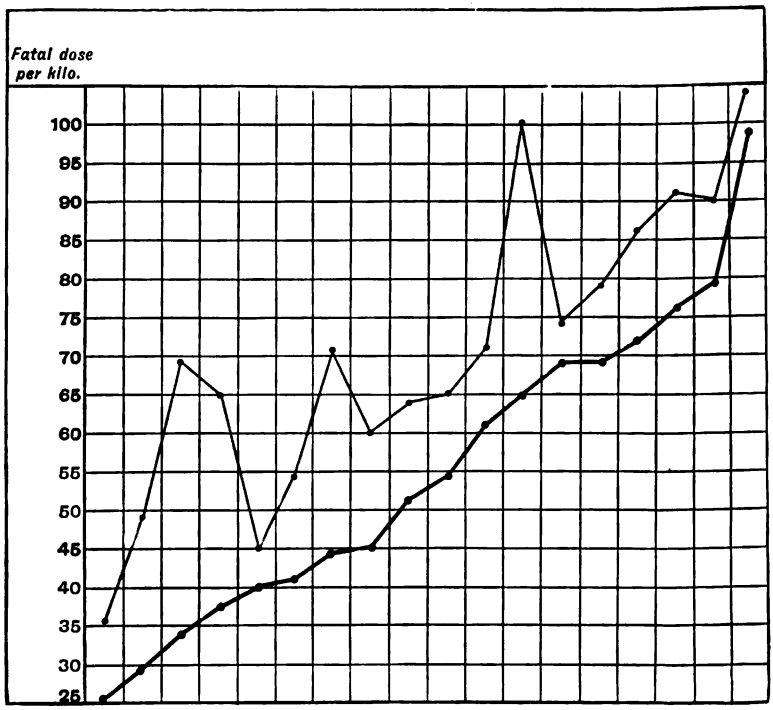

CHART III is composed from Table III. It contains the results of eighteen cases in which two rabbits were killed by the same urine. They are arranged according to the smallest fatal dose. It will be seen that the variation is greater than that of Chart II.

The object of the Charts is to show—first, that there is a very close correspondence between the percentage of potash and the toxicity of the urine; and secondly, that, though this correspondence is broken by occasional aberrations, these are actually less than the variability of the rabbits themselves would lead us to expect.

Digitized by Google

Digitized by Google

Fig. 1.

Fig. 3.

Fig. 2.

Digitized by Google

Digitized by Google

Digitized by Google

DESCRIPTION OF PLATE X,

Illustrating Mr. Barwell's paper on a case of Congenital Limb Deficiency and Redundancy. (Page 320.)

FIG. 1.—Skiagram showing osseous deformities of left hand.

FIG. 2.—Photograph showing the deformities of both upper extremities.

FIG. 3.—Skiagram showing bony deformities of right upper extremity.

(Stereoscopic skiagrams by Mr. Mackenzie Davidson.)

Digitized by Google

Digitized by Google

XI. MISCELLANEOUS COMMUNICATIONS.

1. *A case of congenital limb deficiency and redundancy.*

By R. Barwell.

[With Plate X.]

A good many years ago I brought to the notice of this Society ('Path. Trans.,' 1881, p. 280) "Two cases of truncated arms bearing at the ends fœtal hands voluntarily mobile," and took the opportunity of pointing out the errors of Montgomery, Simpson, and many other writers in ascribing these truncations to intra-uterine amputation, the latter even going so far as to call the minute finger-ends seen at the termination of such abbreviated limbs "rudimentary reproductions." It is not desirable now to trouble the Society with a recapitulation of this paper further than to say it pointed out that by far the larger number of truncations were due to a peculiar arrest of development, and it ended thus: "I believe I know how this arrest is achieved, but must give the matter a little more study." Advantage has since been taken of such opportunities as have presented themselves, and a few weeks ago there came under my notice a girl who bears in her one body a set of congenital deficiencies which go far to confirm the views thus alluded to, and to clear up some lacunæ in our rather deficient knowledge of limb development.

In this matter the members will be very much assisted by the very excellent work of Mr. Mackenzie Davidson. He has taken a number of stereoscopic skiagrams of these limbs, showing in almost startling realisation and relief the various osseous defects. He has further kindly promised to give to the members, who I hope will by-and-by examine these Röntgen shadows, demonstrations of his methods. In the meantime, I show by lantern the external appearances.

The girl, pictures of whose upper limbs are now seen, is 16 years old, rather small and short, but not mentally deficient. Her right

Digitized by Google

hand and forearm are almost entirely absent; they are represented by an addition to the upper arm of a fleshy cushion, which she can flex, extend, and to a slight degree rotate (Plate X, fig. 2). At each distal corner of this somewhat quadrilateral cushion is a small conical projection bearing lilliputian nail-beds, showing that they represent the tips of the original limb-buds as they appeared about the twenty-fourth or twenty-fifth day of fœtal life, only of somewhat larger size. We go on to the osseous defects, but let me first remark that it is very difficult to isolate and localise specific points in the flat shadow, whether cast by the Röntgen ray or by sunlight, of a cylindrical object. Mr. Davidson's method of stereoscopic skiagraphy eliminates this difficulty almost entirely, and by this aid members will be able to see that the lower end of the humerus, although not greatly deformed, is abnormal chiefly in the flattened form of the trochlea, and indeed of the whole articular end. The ulna is represented by a somewhat triangular piece of bone barely two and a half inches long, beginning above in a misshapen olecranon and ending below in a button-like enlargement; the surface nearest to and perhaps articulating with the humerus is only very slightly concave. The radius is entirely absent.

There is, however, in this little apology for a wrist and hand a small curved piece of bone, a little over an inch long, so placed slantwise in the cushion-like appendix, that one end lies quite near the base of the inner undeveloped digit, the proximal end lying outside, and a few lines below the button-like end of the ulna, and this is all that represents the twenty-nine bones of the limb segments (Plate X, fig. 3).

A few words as to my views on the production of this condition, although I must revert to the subject, may here be interpolated. I hold that in this, as in all cases not due to the comparatively rare intra-uterine amputation, the limb-buds duly appeared about the twenty-fourth to the twenty-fifth day of intra-uterine life, and then when that edge, which afterwards should become finger-tips, projected, formative energy ceased; that is to say, just within the Wolffian ridge no more cells or clumps of cells, the foundation and forerunner of each future bone, were deposited. The period or duration of this stasis in formative energy is measurable by observing at what distal point of the limb the deficiency begins and at what proximal part it ceases.

We turn now to the right lower limb. It is at once evident that

Digitized by Google

here also is deficiency; it occurs, however, not in the distal segments, but in the proximal one. All the distal parts of the limb, from the

FIG. 22.

Almost total absence of right femur.

upper end of the tibia onward, are as nearly normal as want of use will allow; neither in circumference nor in length is there greater difference than may thus be accounted for.

But there is no thigh. That segment is represented by a voluminous though short fleshy mass, which proximally is continuous and mingled with the buttock, and distally—that is, two or three inches in front of, rather than below, the pelvis—merges into a slightly narrower part which contains the upper end of the tibia. This right limb is short, therefore, by nearly the whole length of the femur, and the foot is only a little below the level of the left knee.

Digitized by Google

In skiagraphy it is barely if at all possible to get a very detailed shadow of such a large bone as the pelvis, especially when surrounded by massive soft parts. Yet Mr. Davidson has well succeeded in obtaining two good views, which in the stereoscope show that the pelvis is properly formed. The condition of the acetabulum can hardly be seen, as the cavity is occupied by a bone 1¼ inches long which represents the head and a part of the neck of the femur. Beyond this is a gap, and then we come to another piece of bone—a more or less misshapen condyloid end, articulating with a fairly normal tibia. If the condition of the upper and lower limbs of this right side be contrasted, it is clear that we have to do with two periods of stasis in development which succeeded one another without intermediate interval. In the upper limb this began, as already said, immediately after the first appearance of the limb-bud. Certain work I did some years ago, but which I never had the opportunity of completing or verifying, led me to believe that the germ of every bone is deposited in the limb before that particular part is extruded from the Wolffian ridge, and that afterwards, although these deposits shape themselves and grow, no foundation of any bone is laid. Thus, in regard to these upper limb segments, developmental stasis continued until very near the period when all the foundations for the forearm bones should have been laid; then very gradually, as seen by the imperfections of lower end of humerus and upper of ulna, formative functions returned; these then resumed full activity, a good shaft of the upper arm bone growing out of the Wolffian ridge pushed the belated hand, wrist, and forearm before it beyond and away from the area of depositing work.

During that period of inactivity in the upper limb, development of the lower was proceeding normally until in the arm formative activity was gradually resumed, and at that time it ceased in the lower, as though a defect, probably inflammatory, in the central nervous system occupied in the spinal cord a certain tract which slowly travelled down so as to influence the development power of successive regions in the mesoblastic elements of the Wolffian ridge. In those parts of that ridge which should have formed the femur the formative energy never returned. Both thoracic and pelvic girdles—but now I speak only of the latter—are not developed from this ridge, but in the mesoblast of the fœtal body, much as the protovertebræ are formed, the upper part of the femur being developed in continuity with it. Hence those parts, having nothing

Digitized by Google

to do with the Wolffian ridge, do not suffer from its defective energy and are perfect.

The condition of the left hand also shows a series of developmental faults which also are instructive. The forearm and wrist are perfect; so also is the thumb and index, as likewise the middle finger down to the two terminal phalanges, which are thick and clumsy in form, and, as they cast a peculiarly dark shadow, are probably exceedingly dense. This finger is closely webbed to the next one on the ulnar side. This one, the ring finger, is also normal to the end of the first phalanx—the second begins with a very broad joint, and in about the middle of its length splits into two branches, standing apart from one another at an angle of sixty degrees (Plate X, fig. 1). At the end each branch articulates with a similarly bifid third phalanx, the two forks of which unite at an angle of ninety degrees to form a wide ungual end supporting a broad nail. Thus each phalanx roughly resembles a letter Y, the one upright, the other inverted, jointed together at the ends of the branches so as to enclose an almost circular space. There is no fifth metacarpal bone; the little finger articulates by a side extension of their joint surfaces with the metacarpal bone and with the first phalanx of the fourth finger. All these peculiarities are so well seen in the stereo-skiagrams in the next room that they need not be further described here; but I ought to mention that, in spite of these inept-looking extremities, the girl's sewing is, I am told, exceptionally good and neat.

A few words about the bearing on fœtal events which may be deduced from this hand. It appears that the morbid state of the central nervous system, alluded to above as responsible for the deficiencies of the right hand was not completely confined to one side, but spread itself out somewhat into the other side of the cord; not, however, in a degree sufficient to produce complete stasis of development, but only partial deficiency and disorder. Another point is worthy of notice. I believe it is generally considered that the bones, as well as the muscles of limbs, are developed under the sway and influence of ganglia in the motor tract of the central nervous system. This hand suggests, though of course it does not prove, a different conception, as far as the bones are concerned. For the deformity corresponds with the distribution, not of the motor, but of the sensory part of the ulnar nerve.

January 3rd, 1899.

Digitized by Google

2. *The histology of the rheumatic nodule.*

By F. J. Poynton, M.D., and G. F. Still, M.D.

In bringing before this society a paper upon the histology of the rheumatic nodule, we are fully conscious that its structure has been already described in detail by many excellent observers; but we venture to think that the descriptions which have been given, especially in the text-books of medicine, are based upon appearances that are found when the nodule has already passed through the earliest stages of its formation, and for that reason undue stress has been laid upon the fibrous elements which are then so evident. The essential character of the nodule is to be judged from its earliest appearances, before the morbid effects of the rheumatic poison have been modified to any considerable extent by the reactive processes that occur within the body; and it is from a study of these earlier phenomena that one sees most clearly the closeness of the analogy, perhaps the actual identity, which exists between the rheumatic process, as seen in endocarditis and pericarditis with that seen in the nodule, a relation pointed out long ago by Dr. Barlow and Dr. Warner.

It is, then, to the earlier phenomena that we desire to call attention, and the sections shown have been selected as illustrating this stage of nodule formation, and of the allied processes in the endocardium and pericardium.

We may perhaps first be allowed to make a few general observations upon the difficulties that are met with in preparing sections of the rheumatic nodule, and to call attention to certain staining processes which are of value in such an investigation. In the first place, as already pointed out, it is necessary to take the newer formations, and not those of many weeks' standing, and to ensure this it will probably be necessary to take the smallest that can be obtained. Further, the section must pass through or at least near the centre of the nodule, for, as has been repeatedly demonstrated, the microscopic appearances at the periphery are very different from those at the centre. It is probable that the difficulty in carrying out these precautions account in some degree for the discrepancies in the descriptions which have been published. Finally,

Digitized by Google

certain colour reactions given by the aniline dyes carbol-thionin and carbol-gentian violet give considerable assistance in the study of the early formation of the nodule.

Tho value of thionin as a nuclear stain was first pointed out by Martin Heidenhain in the "Festschrift für den fünfzigen Jahren Jubillaume Herrn Dr. Kölliker."[1] If this stain be used for recent fibrinous exudations, such as occur in rheumatic pericarditis, or in pleurisy, it is found that the exudate stains a pale-blue colour, in contrast to the violet blue of the nuclei of the cellular elements and fibrous tissues. If this exudation be stained by Weigert's fibrin method it will be also seen that the carbol-gentian violet gives the usual reaction for that material.

It occurred to one of us (F. J. P.) to make use of these methods in the investigation of the nodule, and they have proved, we believe, of value.

So far as the naked-eye appearance goes, the smallest nodules which can be appreciated either by sight or touch during life are by no means the smallest which can be seen after death. It was noted on several occasions that where only a few nodules could be found on the head during life, numerous minute deposits of the same yellowish-pink material were visible at the *post-mortem*. Some of these deposits were more or less rounded in outline, others ran together into irregular areas, each with its leash of small dilated blood-vessels running up to it, the whole being too small to be appreciated during life. The colour of these minute deposits is much less like that of fibrous tissue than that seen in the older nodules, which are greyish white rather than yellowish pink. On attempting to remove one of these smaller nodules there is considerable difficulty, for they contain a certain amount of fluid, exudative in character, and any squeezing or traction diminishes their bulk, so that they are often lost altogether. This difficulty is the greater because there is no distinct line of demarcation from the surrounding fibrous tissue.

Turning now to the microscopic details, we should like to point out the close resemblance that there is between the appearances of an early rheumatic nodule and recent rheumatic peri- and endocarditis when stained by a precisely similar method.

The sections shown were taken by one of us (F. J. P.) from a

[1] We are indebted for this reference to Mr. Plimmer, bacteriologist to St. Mary's Hospital.

Digitized by Google

case that died in St. Mary's Hospital. Three weeks elapsed between the first visible evidence of the nodule and the death of the patient, and thus, though not in its very earliest condition, it still shows distinctly the nature of the early changes.

All the sections were from tissues fixed in corrosive sublimate, they were cut in paraffin, and stained with carbol-thionin.

In the centre of the nodule there is a homogeneous material arranged in layers and free from cellular elements. This stains pale blue with carbol-thionin, and gives Weigert's fibrin reaction with gentian-violet. We look upon this material as fibrin in the interstices of which there was originally fluid. It is the presence of this homogeneous material which we wish particularly to emphasise: for, as we have pointed out below, it is this, and not the subsequently developed fibrous tissue, which is, in our opinion, to be regarded as the essential element in the nodule. Compare now

FIG. 23.

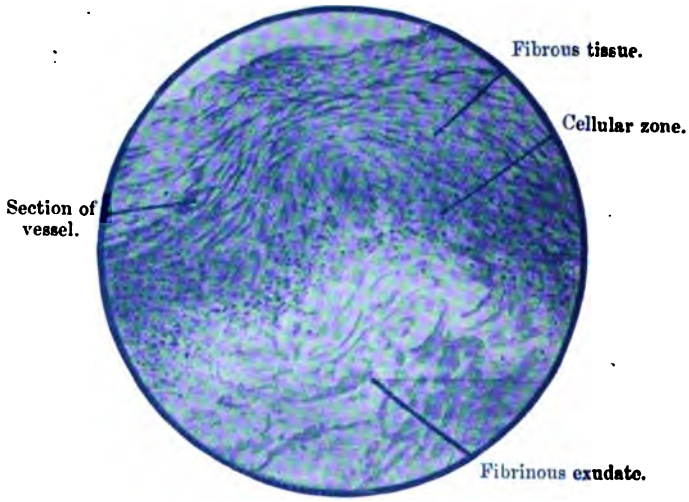

Section of rheumatic nodule of three weeks' duration.
Drawn under 1″ obj., oc. 2.

with this the exudation on the free surface of the inflamed pericardium, and the vegetations on the valve, and it will be seen that they have much the same appearance and give the same reaction.

Away from the centre of the *nodule* towards the periphery, many

Digitized by Google

cellular elements become visible encroaching upon this fibrinous centre; and again comparison with the deeper part of the pericardial exudation and with the valve shows a similar appearance. Still further towards the periphery of the *nodule* fibrous tissue is apparent, some of it swollen and hyaline, and in places there are distended and tortuous vessels. In the deeper part of the pericardium also the distended vessels are very apparent, and the hyaline appearance of its fibrous matrix is also distinct. In the *valve* the swollen appearance of the fibrous tissue can also be detected.

Thus we can recognise in these three sections fibrinous exudation, cellular infiltration, and fibrous tissue, and we know that in the pericardium the sequence of changes is as follows: first, vascular dilatation; then exudation, which in rheumatism is usually fibrinous; cellular infiltration; and, finally, fibrosis. We conclude that the same sequence of events occurs in the rheumatic nodule.

In this way, and in this way only, it seems to us that the occasional rapid appearance and disappearance of a nodule can be explained, for if the rheumatic process is rapid and evanescent, the fibrinous exudate is as rapidly absorbed, and the nodule, which in such a case is probably not fibrous at all, vanishes. If the morbid process be more protracted, then the restorative changes will be slower, and there will be some fibrosis in addition to absorption, and the nodule will more slowly disappear. It is of such a nodule as this that sections can be most easily obtained. Now and again the nodule lasts for many months, and the section of such an one shows imperfect restorative processes, the fibrous tissue is ill-formed and only to be found in patches, a condition which can also be observed in some of the old nodules upon the cardiac valves.

We are aware that it has been suggested that the structureless material is a product of degeneration in the nodule, but this suggestion can hardly, we think, be correct, in view of the fact that the appearance is particularly well seen in the smaller and more vascular nodules which are presumably the young ones, and therefore the least likely to degenerate.

A study of nodules in various stages of development has seemed to us to show that this central portion, consisting apparently of fibrinous exudate, is the basis, so to speak, of the nodule, and it is from this, therefore, and not from the peripheral portion, that its essential character must be judged. Moreover, the comparison with the pericardial exudation shows, we think, that the essential

Digitized by Google

change which produces the rheumatic nodule is an actual deposit of inflammatory exudation, and one might even go further and say that the formation of fibrous tissue is not a necessity: it need not, and certainly does not always, occur. This conclusion, drawn from the microscopic appearances, is confirmed by the clinical fact that a nodule may appear in twenty-four to forty-eight hours, and the whole time from appearance to disappearance may, it would seem, be only three days.

Finally, we would suggest, if the occurrence of fibrous tissue formation is to be regarded as a late phenomenon and in no way essential to the formation of nodules, a view which we think is confirmed by the appearance we have described, that it is more satisfactory to apply the term "rheumatic" or "subcutaneous" to these nodules than to call them "fibrous."

April 4th, 1899.

---

3. *The technique of blood films.*

By W. C. C. Pakes and R. Howard.

We are venturing to bring forward what we consider to be two or three improvements in the technique of blood films.

Firstly, there are two places from which blood may be conveniently collected: the lobe of the ear and the back of the finger. The ear has considerable advantages; it is easily sterilised, and rendered hyperæmic, and is out of sight of children and neurotic patients, as well as being much less sensitive than the finger. The advantage of the finger is that it is rather more convenient to the operator.

The best instrument for pricking the ear or finger is undoubtedly a lancet. Ordinary sewing needles, surgical needles, and pen nibs are not much good. The lancet, however, is not suitable for constant sterilising and may frighten the patients. We have therefore had constructed for us by Messrs. Down Brothers what is practically the point of a lancet mounted on a needle. It is a hare lip pin which has been cut off at the broadest part of the lance head and ground and sharpened to represent the point of a lancet. This we have found cheap, efficient, and, of course, painless.

Digitized by Google

The ordinarily described "2 Coverslip" method of preparing films is not satisfactory. It requires a great amount of practice, and even in the hands of good manipulators is not constant. Dr. Manson some time ago suggested that good films could be made by collecting the blood on the edge of a piece of tissue paper and drawing it along a slide. This certainly is easy to do and gives good results. But the slide has many disadvantages. It is difficult to keep clean, is unhandy in the stains, and is bulky when many specimens are to be collected and transmitted to the laboratory.

We have applied this method to the coverslip. If two *square* coverslips are laid edge to edge on blotting-paper and held down with a slide, the cigarette paper may be drawn over these as over the slide. A still better method is to use 1½-inch by ¾-inch coverslips. On these excellent films can be made.

The inconvenience of their lightness we have overcome by having a special clip made. This clip consists of a small block of wood five-eighths of an inch from the free edge of which a strip of cork is inserted. On this strip of cork a piece of brass is pressed by a spring so that the coverslips can be held between the cork and brass. In order to charge the clip, four coverslips are laid on the wood so that one edge rests on the cork, the spring being depressed. On releasing the spring the coverslips are held in position. A great advantage of this clip is that the coverslips need never be touched with the fingers, and that the clip can be held in the most convenient position when the films are being made. In fact, it is just as convenient as the slide.

We must here emphasise the fact that clean coverslips must be used. These as they are usually sold are not clean enough for blood film work. An easy and efficient method is to boil them in nitric acid or chromic acid, remove the acid with water, dehydrate with and then keep in absolute alcohol. They should be prepared for use by picking them out of the alcohol singly and burning off the alcohol. They must never be touched with the fingers until the films are actually fixed, otherwise the moisture from the hand may lake the corpuscles.

The cigarette papers to be used should be those that are not fastened to the case, as the tarlene or zigzag. Strips about half and inch wide should be cut across the ribs, and the ungummed edge used for collecting the blood.

In order to prepare the film, the under surface of the edge of the

Digitized by Google

strip is moved laterally over the drop of blood, care being taken not to get any blood on the upper surface of the paper. The end of the strip bearing the blood is laid upon one end of the coverslip and the blood is allowed to spread out between the two. The strip is then drawn slowly to the other end of the coverslip. A very little practice enables the manipulator to gauge the amount of blood required, and thin, even films can be obtained nearly every time.

The films are allowed to dry in the air (this only takes a few seconds), and are then ready for fixing and staining.

Whilst admitting that the method we propose requires a certain amount of apparatus, we maintain that the advantages far outweigh the disadvantages. The only real essentials are long slips or slides and cigarette papers.

We wish here to call attention to a very excellent single stain which was suggested to us by Dr. MacConkey. Muir and Ritchie recommend carbol-thionin blue, *i. e.* 1 grm. thionin blue in 100 c.c. of 1 in 40 carbolic in water, as a bacterial stain; we do not think it is very useful for this purpose, but are satisfied that it is extremely simple and effective for certain blood examinations. It stains the red discs a faint grey, and the nuclei of the leucocytes a distinct reddish colour. It can be used equally well after any fixing reagent, a feature common to very few blood stains. It stains the young parasites of malaria extremely well, but is, of course, useless for staining eosinophile or basophile granules. It picks out blood in tissue very well, but it is slightly apt to precipitate. The preparations should not be left in the stain more than three minutes, when they should be well washed in water, dried and mounted.

We have exhibited two films, one of leucocythæmia and the other of malaria, to show the characteristics of the stain.

Mr. Howard, who is shortly going to Africa, has had the accompanying microscope and accessories fitted up for him, and the case contains everything which is necessary for the examination of blood. *December 20th*, 1898.

Digitized by Google

XII. DISCUSSION ON PSEUDO-TUBERCULOSIS.

February 21st and March 7th, 1899.

INTRODUCTORY ADDRESS.

By Prof. G. Sims Woodhead.

Mr. President and Gentlemen,—I have little doubt that many of those who take part in this discussion will describe such conditions of "pseudo-tuberculosis" as they have had the opportunity of studying. Although I must necessarily say something concerning the forms of pseudo-tuberculosis that have come under my notice, I may say at the outset that it will be my endeavour so to put the matter before you that we, as a Society, may see it our duty to attempt to do away altogether with this term "pseudo-tuberculosis," and eventually, after due consideration, submit a nomenclature, the basis of which I hope may be suggested this evening—a nomenclature which may assist us not only to get rid of some bad terminology, but in giving a foundation of a classification at once accurate and comprehensive of what at present must be looked upon as the flotsam and jetsam of the Pathological theatre and laboratory.

I have long been of the opinion that at some time or other it would be necessary to get rid of the term "pseudo-tuberculosis," as its use has been responsible for a good deal of misunderstanding, and now, in the light of recent investigation, one feels that it would perhaps be better to treat this question in the same free and easy manner that the chapter on snakes was dismissed by a certain mythical Hibernian historian. On going over the literature of the question, however, one finds that it is absolutely impossible to dismiss it thus curtly "that there is no 'pseudo-tuberculosis,'" but

Digitized by Google

references to it are so numerous, and the number of conditions classified within this term are so numerous, that "pseudo-tuberculosis" is no longer of the slightest value as a term in classification, for after eliminating a number of specific conditions which at one time were included under this heading, we have still numerous pathogenic conditions most varied as to appearance and etiology described by different writers as "pseudo-tuberculosis."

I may as well begin by confessing my own faults, and referring to a series of cases which came under my observation during our investigations carried on for the Royal Commission on Tuberculosis. I do this because I spoke of them at the time as being cases of "pseudo-tuberculosis." I may give the notes and photographs of one of these specimens that might undoubtedly have been mistaken for true tuberculosis had not the conditions under which it occurred and the microscopic examination given such definite indications that it was not really a case of true tuberculosis. For the sake of convenience I spoke of the process as being "pseudo-tubercular." In a series of experiments carried on for the purpose of determining whether the meat from a certain cow contained the specific tubercle virus a guinea-pig died on the second day after the meat had been eaten; much too early, therefore, to show tubercle as the result of the ingestion of the meat that was being experimented with. In this case the following conditions were found: "venous congestion of the large intestine and cæcum; the solitary glands and Peyer's patches were enlarged and œdematous, and there were small hæmorrhages into their substance; in these glands in the small intestine were white opaque points; in some cases these were scattered over the whole glandular patch; the mesenteric glands were slightly enlarged; the liver was mottled with small yellow patches, very irregular in distribution; in the lungs were two yellowish-grey points; the spleen was normal, but the mediastinal glands were evidently enlarged.

These photographs (taken from portions of the large and small intestine of this animal) show extremely well the appearances presented; the degenerated patches were much whiter than any tubercle nodules that I had hitherto come across, and the breaking down was more complete, so that on microscopic examination one could not make out even the outlines of any cells in the degenerated area; no tubercle bacilli could be found in any of the lesions, but micrococci, especially in the form of diplococci, sometimes slightly

Digitized by Google

elongated, were numerous. Until our attention was drawn to the peculiar whiteness of the nodules, Dr. Cartwright Wood, who was working with me, and I agreed, that it was probably a case of tuberculosis accidently acquired, but when we came to go into the history of this series of animals and found that all the others were perfectly free from tubercle, and that it was impossible in a single lesion to make out any tubercle bacilli, it was evident that we must look upon it as some mycosis other than tuberculosis; that, in fact, it was not even an atypical tuberculous lesion. Still, without having recourse to microscopic examination I could not then satisfy myself that this was not a case of true tuberculosis.

In a couple of guinea-pigs inoculated with raw meat from the same cow, small nodules were observed in the spleen: in one case all the organs except the spleen were perfectly normal, but here were several nodules which to the naked eye looked exceedingly like small yellow infarctions. On section and microscopical examination these nodules were found to consist of three layers or zones; a central or necrotic area in which the cells were dead, had lost their outlines, and had become fused into irregular masses; near the margins of this portion were short bacilli, stained by methylene blue, but very readily discoloured, some of them appearing almost like diplococci, as the ends were so much more deeply stained than the central portions; *i. e.* there was distinct polar staining; no tubercle bacilli could be made out. Around this central area was a zone of shadowy-looking splenic tissue, whilst around this, again, is a distinct capsule consisting of connective tissue and leucocytes surrounded in turn by fairly normal splenic tissue. In the second case the spleen again presented the same nodular infarcted appearance, the other organs being quite normal; the central degenerating area, however, is larger and the connective-tissue capsule is not nearly so distinctly marked; otherwise this is exactly like the specimen already described.

In another guinea-pig injected with artificial tubercular milk, heated to 70° C. for one hour, at which tubercle bacilli are rendered innocuous, at any rate as far as guinea-pigs are concerned, the animal died eleven days after injection, when it was found that there had been peritonitis and adhesions between the visceral and parietal serous membranes. In some of the adenoid patches there were opaque areas over the adherent surfaces. These opaque

Digitized by Google

patches on microscopic examination were found to consist of tissue in an advanced stage of necrosis, whilst around this dead mass numerous tissue cells, leucocytes, and micro-organisms were found. These micro-organisms were in the form of short bacilli with slightly pointed ends, some of them again almost like diplococci. The non-stained central band was more marked and the polar staining was also distinctly brought out. Here also we have evidently the necrosis due to the action of an organism other than the tubercle bacillus.

Another specimen (photograph): a small yellow nodule about the size of a millet-seed was found near the surface of the liver of a guinea-pig that had been injected with artificial tuberculous milk heated to 70° C. for ten minutes. The animal was killed 101 days after inoculation. On microscopic examination this small nodule was found to be made up of a large mass of organising connective tissue in which were a number of small blood-vessels; at the margin of the mass were numerous leucocytes and young connective-tissue cells in which the blood channels were larger and more numerous than were those in the older fibrous nodule. Not a single tubercle bacillus could be found, and there was no evidence of caseation or of extension into the surrounding tissues, and, in view of the fact that no other evidence of tubercle could be found in any part of the body, we were compelled to come to the conclusion that this growth was not tubercular.

As I was engaged on a special investigation, I used the term "pseudo-tuberculous" very much as a matter of convenience, and in order to distinguish this condition resembling tuberculosis from the true tuberculosis with which I had to deal, but I was fully conscious of the fact that in using this term I was adding to a confusion that was already sufficiently great, especially in comparative pathology.

Whilst on this subject, I may mention one or two other conditions which, at first sight, were mistaken for tubercular granulations, and I throw on the screen a photograph of a small grey area found in the muscle of a cow. This patch, or group of patches, rather, simulated grey miliary tubercular granulations in the muscle of a cow in which the visceral organs were tuberculous throughout. On microscopic examination it was found that, although the muscle fibres were swollen and had undergone hyaline or vitreous (?) degeneration, there was a slight increase in the number of leucocytes, and

Digitized by Google

the formation of a fibrous tissue capsule around the degenerating area; but there was no true tubercular structure, and tubercle bacilli could never be demonstrated in any part of the muscle at any stage of the degenerative process. The nature of this change may be more distinctly seen in the high-power photograph, from which it will be seen that the degenerating muscle has undergone a granular disintegration; this, however, being preceded by a loss of striation of the muscle, which becomes homogeneous and swollen —hyaline. It is evident, of course, that this has nothing to do with a true tubercular process, nor is it even pseudo-tuberculosis in the widest sense of the term, except superficially and to the naked eye; though it is quite possible that, as in the hyaline degeneration found in the muscles of the fowl in fowl cholera, this condition may be due to the action of some micro-organisms or their poisons.

A doctor friend—a medical officer of health—some five or six years ago, shortly after the Epidemiological Congress, startled me greatly by assuring me that he had seen an enormous amount of tubercle in the lungs of sheep. I mildly suggested that I thought there must be some mistake, but he assured me that he had only that day confiscated the lungs of some thirty or forty sheep, in every single one of which he found well-marked grey tuberculous nodules. I asked him to show me one of these, and also to give me his authority for supposing that these were tuberculous. He brought up one of the lungs, and I at once recognised it as what is called in Scotland "hoos," small pearly-grey glistening nodules, the result of the presence of the *Strongylus filariæ*, a very common parasite in the lungs of sheep.

On microscopic examination, as no doubt Professor McFadyean will demonstrate, these small nodules are found to consist of small nematode worms coiled up and surrounded by proliferating connective-tissue cells which exhibit very little tendency to undergo degenerative changes, any change being in the direction of the formation of fibrous tissue rather than towards caseation.

The tubercle-like bodies met with in the lungs, the so-called "worm-knots" of the Germans, are really due to the action of the strongylidæ, which may give rise to an actual epidemic in sheep, oxen, rabbits, and pigs; and Leuckart quotes a case in which a similar condition is described as being met with in the lung of a child who suffered from the presence of an organism which is sup-

Digitized by Google

posed to correspond to the *Strongylus paradoxus* which occurs in the lungs of the pig. These strongyles, which are egg-bearing nematodes with a short larval existence, are found in the air-passages of the animals mentioned. The ova are said by some to be brought by the blood-vessels and to be deposited in the walls of smaller bronchi and air-vesicles, where they develop into the worm form, then giving rise to the formation of these "pseudo-tubercular" growths, by the irritation they set up. It appears to be much more probable, however, especially as the ova may sometimes be found on the mucous membrane of the air-passages, that they make their way in by the air-passages, and then, impacted in the smaller bronchi, and perhaps even in the infundibular passages, give rise to that tissue-proliferation so characteristic of their presence. They act not merely as foreign bodies, but also as irritant foreign bodies, as we cannot imagine these animal parasites living without excreting certain products which are probably irritant; this irritant, however, appears to be only sufficiently active to stimulate the cells to proliferation and to be incapable of bringing about the secondary degenerative changes that are so frequently associated with rapid proliferation. Hence it is that we have the glistening translucent nodules with little tendency to undergo caseous or purulent changes. This, as we have said, is a perfectly distinct process, and one which should certainly not be called a "pseudo-tuberculosis."

This verminous "pseudo-tuberculosis" is recognised as a distinct pathological condition by comparative pathologists, and it would certainly make for greater clearness and simplicity could the term "pseudo-tuberculosis" be dropped entirely, and some more specific name applied. Pathology is already burdened with too many of these vague and general terms which can only have the effect of keeping back a scientific classification and nomenclature. This is an even greater drawback in comparative than in human pathology, for in human pathology certain terms, though inapt in themselves, have come to be endowed with a certain significance, and we have gradually come to accept a series of names which, had we to commence afresh, we should be dissatisfied with. Comparative pathology, however, a field that has been worked with such marked success by the modern school of veterinary surgeons, is in many places virgin soil; consequently clumsy and misleading terms may be readily dropped, as they have not yet come to be too closely

Digitized by Google

associated with the conditions they denote, and these more recently described diseases and conditions may at once receive appropriate names.

In the introduction to his article on "pseudo-tuberculosis" in birds, Professor Muir draws attention to the fact that there are at least six conditions which have been described as "pseudo-tuberculosis," but he describes a form of "pseudo-tuberculosis" in birds which is probably the same as that described by Malassez and Vignal, Nocard, and Pfeiffer. This is a point of special interest, as Malassez and Vignal's experiments were carried on with an organism which was separated from a guinea-pig inoculated with a portion of a nodule taken from the arm of a tubercular child; whilst a number of the cases of "pseudo-tuberculosis" described by other authors have also been produced by the inoculation of sputum from tuberculous patients or from milk from animals that were supposed to be suffering from atypical tubercle; in others, again, guinea-pigs appear to have been affected "spontaneously," that is, they have contracted the disease quite apart from experimentation. This is a point of considerable importance in connection with my own observations on the pseudo-tuberculosis of the guinea-pig which evidently occurred, in certain cases at any rate, spontaneously; as, in the animal that died two days after inoculation with heated tuberculous material; whilst another case, in which bacilli identical in appearance with those described by Nocard, Muir, and Pfeiffer were found, was injected or fed with artificial tuberculous milk, consisting of the pounded tubercular organs of guinea-pigs mixed with ordinary milk. This apparently gave rise to this condition on the eleventh day, thus corresponding very closely with the condition presented in Professor Muir's experiments, though, of course, here we were dealing, not with pure cultures, but with crude material.

Dr. Muir points out that this special form of "pseudo-tuberculosis," when met with in the subcutaneous tissue of guinea-pigs, takes the form of a "subacute inflammatory focus which undergoes caseation, and usually softening;" this extends, as a rule, to the neighbouring lymphatic glands, and a few nodules may be found in internal organs, usually the liver and the spleen. This disease is not necessarily fatal. The most marked feature about it is that the cells, both leucocytes and connective tissue corpuscles, undergo a very rapid necrotic breaking down. This corresponds to the

Digitized by Google

description already given, whilst, as already observed, the caseation and softening both take place at a very early stage after the inflammatory reaction and leucocyte infiltration, the result being that the centre of a nodule becomes almost purulent rather than caseous. He also points out, as noted in my cases, that the proliferative changes are well marked and are confined almost entirely to the periphery of the nodule, and he draws attention to the fact that, owing to the absence of giant cells, the lesion somewhat resembles the glanders nodule, except that in "pseudo-tuberculosis" the softening takes place more rapidly and is more extensive. He also found that the bacilli, as in bacterial necrosis, are usually found near the margin of the caseous centre; they may, however, be entirely absent, especially in chronic cases. This accords perfectly with what I observed in the "pseudo-tuberculosis" of guinea-pigs described in the Report to the Royal Commission on Tuberculosis, and I now greatly regret that, owing to pressure of other work connected with the Report, it was impossible to follow out the study of the bacteria producing this disease. I shall, therefore, say nothing further about this, beyond expressing my belief that the disease we met with was identical with the *tuberculose zoogloeique* of Malassez and Vignal, Nocard, Pfeiffer, and Muir.

In comparatively recent years those of us who have had the opportunity of examining cases of actinomycosis have, in searching for corresponding cases in our museums, come across cases labelled "tuberculosis," which, having the more recent cases before you, have at once been recognised as being cases of actinomycosis; whilst there have been brought under the notice of pathologists in this country, by Prof. Boyce, of Liverpool, a case which he very properly describes as aspergillo-pneumonomycosis, a much better term than that given to a similar condition by Kotljar, who describes what he terms an aspergillo-pseudo-tuberculosis. Kotljar, indeed, insists specially that these "pseudo-tuberculoses" can be divided into two groups, those of bacterial origin, and those of mycotic etiology, these latter being produced by aspergilli, especially probably the *Aspergillus fumigatus*.

Here, again, we are at once led into difficulties when we come to consider these different forms of "pseudo-tuberculosis." During life it is impossible to find the tubercle bacillus in the expectoration, whilst, as is well known, there are a number of cases on

Digitized by Google

record in which an aspergillus has been found in the sputum directly it comes from the lungs. In birds and animals this condition of pneumonomycosis is of comparatively common occurrence, and the term used by Boyce is certainly much preferable to aspergillo-pseudo-tuberculosis. Even when we come to the bacillary *pseudo-tuberculosis ovis*, or pseudo-tuberculosis of sheep, the inconvenience of using a term which applies to a pathological condition so entirely different from the strongylar disease also met with in sheep, to which the same name has been given, is obvious. It is not necessary to do more than point out that a pseudo-tuberculosis occurring specially in mice, has been described; whilst Kutscher and Pfeiffer mention a form set up by the inoculation of material from glandered horses. Pfeiffer's bacillus is considered to be identical with Malassez and Vignal's, and it is quite possible that Kutscher's is of the same nature. Hayem brought forward evidence that the human subject might be affected by the pseudo-tuberculosis bacillus (*Tuberculose zoogloeique*) a statement that is corroborated by the fact that Malassez and Vignal's pseudo-tuberculosis was induced by the inoculation of a guinea-pig with a portion of a nodule from a child that was said to be suffering from tuberculosis.

I believe that our President will bring before us to-night some interesting cases in which mechanical irritants have induced changes in the delicate tissues of the eye—changes which resemble very closely some of those met with in a true tubercular iritis. With these, however, he will deal, and it is necessary for me only to mention these mechanical irritants as producing changes somewhat similar to those that I have already described in the "Wurmknötchen" of the sheep.

In comparatively recent times we have passed from the anatomical pseudo-tuberculosis to a pseudo-tubercle bacillus, a factor which promises, unless taken firmly in hand and in time, to render the question of pseudo-tuberculosis still more complicated. The smegma bacillus was comparatively easily dealt with so long as it was found only in certain well-defined positions, but Frau Rabinowitch opened a very serious question when, in milk and butter, she found a bacillus which, morphologically, and in its staining reactions, but in little else, was identical with the tubercle bacillus. Frau Rabinowitch's observations have been confirmed by other investigators, and we have now the two positions from which it is

Digitized by Google

absolutely necessary we should free ourselves by getting rid of terms which, under present conditions, can only end in inextricable confusion. On the one hand, we have pseudo-tubercle bacilli which have morphological and staining character of the true tubercle bacillus, but which pathologically appear to be widely separated from it; whilst, on the other hand, we have a whole series of lesions which present certain superficial resemblances to tubercle in some of its forms, but which can be distinguished in most cases by certain specific differences, and, most important of all, are not induced by the action of the tubercle bacillus. One of the great difficulties that the earlier pathologists experienced in arriving at a definite conception of the pathology of tubercle was its protean form, and even in the present day, now that tuberculosis has come to be so intimately associated with the ultimate etiological factor—the tubercle bacillus—the bacillus itself rather than the exact histological lesions has come to be looked upon as the essential determining factor in classification, and, although in tuberculosis a general sequence of changes may be observed, these may be so masked, and take place at such very different rates, and give rise to such varying results, that it would be difficult to describe any single form of tubercle that should be taken as typical. When, therefore, it comes to be a question of comparing other pathological conditions, and speaking of them as pseudo-tuberculosis, it is necessary, if the term is to convey any distinct meaning to those to whom the process is being named and described, to give a kind of tuberculosis with which the pseudo-form is to be compared. For instance, what possible resemblance can there be between the pseudo-tuberculosis set up by *Strongylus filariæ* in the sheep and the pseudo-tuberculosis of which I have thrown examples on the screen, the form occurring in guinea-pigs as the result of the action of the short polar-stained bacillus? It is impossible to make out even a naked-eye resemblance; whilst, when we come to the histological features and the pathological factors, any points of resemblance are absolutely wanting. In the same way the *pseudo-tuberculosis ovis* of Preisz is absolutely distinct from the filarial *pseudo-tuberculosis ovis;* whilst, coming to birds, the pseudo-tuberculosis described by Malassez and Vignal, Nocard, Pfeiffer, Muir, and others is essentially different from the aspergillar tuberculosis also met with in birds; whilst the similar condition in man should no more be called an aspergillar

Digitized by Google

pseudo-tuberculosis than should a case of actinomycosis be said to be of a pseudo-tubercular nature.

When we come to the histological features of tubercle, they are so varied at different stages and under different conditions that almost every new tissue at some period of its development may be said to be like some stage of a tubercular process: we find similar cells in the glanders nodule. Take the rapid infiltration of leucocytes, this also is met with in certain other specific conditions. Even the giant-cells, which are supposed to be so characteristic of chronic tubercle, may be mimicked, imperfectly no doubt, in ordinary granulation tissue and in the new tissue of the glanders nodule. The various forms of phagocytic cells met with in tubercle are, as might be expected, to be found in actinomycosis, in aspergillar pneumonomycosis, and, in fact, in all those conditions in which foreign bodies are to be absorbed, and in which, too, irritant substances are produced by the action of the higher fungi or bacteria.

Coming now to more general changes, one finds that endarteritis obliterans, taking this as an example, may be met with in tuberculosis, in actinomycosis, in glanders, and in a variety of other conditions in which poisonous products are being developed regularly and over considerable periods of time; and in tubercle as in specific disease the caseation which results, although due no doubt in a certain measure to the direct action of toxic products, is the result also to some extent of the cutting off of the blood supply from the caseating area, brought about by the gradual obliteration of the blood-vessels. It seemed possible at one time that we should be able to simplify pathological nomenclature by gradually eliminating from the term tuberculosis all those conditions that are not brought about directly by the action of the tubercle bacillus. A large number of conditions which had hitherto not been recognised as tubercular were, in comparative pathology, brought into their proper position. For example, the term lymphadenoma as applied to certain conditions met with in the horse in the spleen, in the mesentery and even in the lungs, has now been practically obliterated, as, owing to the investigations of McFadyean in this country, and Nocard, Ostertag, and others abroad, most of these lesions have been found to be typically tubercular; whilst certain lesions in the cat and other feline animals, which have been described as glanders and caseous pneumonia, have also been

Digitized by Google

recognised as being tubercular, and it appears to me to be very inadvisable that we should, just as order is being evolved from chaos, bring in any nomenclature which can only ultimately lead to confusion; and I hope to-night to have an expression of opinion on this point not only from those who take part in the discussion and exhibit specimens of what have hitherto been called "pseudo-tuberculosis;" but a suggestion from our President as to the best means of drawing up an accurate descriptive nomenclature of many of these forms of disease which at present are practically unnamed.

Pseudo-tuberculosis as a pathological entity has now no longer any existence, and, although it may be necessary, owing to the exigencies of use and wont, to retain the term tuberculosis, that term should be restricted as far as possible to a process which has a distinct etiological factor, and we should minimise, as much as possible, the evil of the term by eliminating altogether the term pseudo-tubercle.

Dr. SIDNEY MARTIN said that in the course of time, when the conditions which were at present described under the name of pseudo-tuberculosis had been more completely studied, the name would have to be given up. Tuberculosis was a definite disease, caused by a well-known micro-organism, and the nodules (miliary tubercle) which constituted the early lesions of this bacillus underwent certain degenerate and other changes, such as caseation and peripheral fibrosis. Other living agents, as was now known, could produce appearances which were more or less similar to the naked eye and to microscopical examination. Dr. Martin was familiar with the lesions in guinea-pigs and rabbits which Dr. Sims Woodhead had referred to. These lesions were found in the liver, spleen, lungs, intestines, and mesenteric glands of many of these animals which were kept in large quantities for experimental purposes. The lesions consisted of whitish or whitish-yellow nodules, sometimes soft, sometimes hard, varying in size and shape and tending to coalesce; microscopically they consisted of cells in varying degree of necrosis, and there was also found in the necrosed area, sometimes chiefly in the vessels round, groups of bacilli or of cocci to which the condition must be ascribed. No tubercle bacilli are found in these lesions. The lesions are best referred to as "bacterial necrosis," at any rate provisionally, until

Digitized by Google

the characteristics of the micro-organisms producing them are more clearly known. To what extent these cases of slowly forming bacterial necrosis occur in man is not known. But there are other lesions produced by fungi which are becoming of great importance in the pathology of infective disease. Apart from actinomycosis, our knowledge of which is rapidly extending, there are lesions sometimes sufficient to cause death, and produced by fungi allied to the actinomyces, and which are called streptothrix. Simon Flexner, in a recent article, refers to these diseased conditions as *pseudo-tuberculosis hominis streptothricha*, and relates the case of a male negro, aged seventy, who was admitted to the hospital with the history of a chronic illness, and the symptoms and signs, among other things, of consolidation of the lungs. At the *post-mortem* examination, the upper lobe of the left lung was solid, grey, opaque, and softening; in the lower lobe there were scattered masses of consolidation. The middle lobe of the right lung was solid, and there were nodules in the rest of the lung, some calcified, some caseous. The omentum was thickened and rolled up, and showed large and small nodules like those of tuberculosis; these were also present in the liver and spleen.

Histologically the nodules were composed of cells undergoing caseation and fibrin. Although no cultivation was obtained from the nodules, and the single inoculation experiment was practically negative, streptothrix forms were present in the lesions of the lungs but not in those in the abdomen; no tubercle bacilli were found. The case is incomplete, but it is a contribution to the study of chronic and caseating non-tuberculous disease of the lungs, and indicates the importance of looking out for such cases. Buchholz has described a case of mixed infection of the lung by streptothrix and streptococcus; there was consolidation, excavation, and empyema. Scheele and Petruscky have described a case of infection by a hyphal fungus, in which the skin as well as the lung was affected. Other cases have been published under the name of "aspergillosis." The subject, therefore, is at present very incomplete; but it is evident that, although the most common cause of caseating and destructive disease of the lungs (more particularly) is tuberculosis, yet there are other similar conditions produced by hyphal fungi. The mycelium of these fungi are not stained by the carbol-fuchsin method for tubercle bacilli, and Flexner makes the suggestion that in doubtful cases of lung disease

Digitized by Google

in which no tubercle bacilli are found in the sputum, it would be well to stain this by the Gram-Weigert method.

Dr. WASHBOURN said that it would be advisable to discard the term pseudo-tuberculosis, as it was somewhat misleading. There were several bacilli which resembled the tubercle bacillus in morphology and in staining reactions. By some observers such bacilli would be called pseudo-tubercle bacilli. They were of importance from the point of view of clinical diagnosis, for by relying upon a microscopical examination alone they might easily be mistaken for the tubercle bacillus. In the urine pseudo-tubercle bacilli of this nature were by no means uncommon. It was on this account that inoculations were necessary for the diagnosis of tuberculosis of the genito-urinary tract. The term pseudo-tuberculosis was usually applied in quite a different sense to the above. It was used to denote diseases which resembled tuberculosis in morbid anatomy, but which were caused by other organisms than the tubercle bacillus. Of late a large number of such diseases had been described. There were many organisms which produced similar anatomical lesions to those produced by the tubercle bacillus. These organisms were of widely different character. There were bacilli such as the bacillus pseudo-tuberculosis, giving rise to caseating tubercles in many animals; the bacillus pseudo-tuberculosis murium, causing caseating tubercles in mice; and the bacillus pseudo-tuberculosis liquefaciens, causing tubercles in the peritoneum in the human subject and similar lesions in rabbits. There were various kinds of streptothrix, such as the one described by Flexner in the human lung. There were also organisms which do not belong to the class of bacteria; a form of mould, the aspergillus, had been described as causing a tuberculous lesion in the human lungs; an organism belonging to the class of the blastomyces was described by Gilchrist and Stokes as producing a lesion resembling lupus vulgaris in the human skin; while even nematode worms might produce tubercles consisting of giant cells and epithelial cells in the lungs of cats and the kidneys of dogs. The skin disease described by Gilchrist and Stokes was of especial interest. Although it resembled lupus vulgaris in its clinical aspect, it was caused, not by the tubercle bacillus, but by a blastomyces, which they obtained in pure cultivations, and which when inoculated produced in animals tubercles consisting of epithelial cells and

Digitized by Google

giant cells. It was quite probable that many of the cases of so-called tuberculosis of the skin were due to other organisms than the tubercle bacillus. The speaker had seen such a case lately, in which tubercle bacilli could not be obtained either by microscopical examination or by inoculation. It was quite clear that the lesions caused by the tubercle bacillus were by no means specific, for many organisms might produce exactly the same changes. Again, the lesions produced by the tubercle bacillus were not constant; sometimes there was much caseation with formation of giant cells, while in other cases there was the production of a granulomatous tissue. In fact, the tubercle bacillus and the other pathogenic organisms mentioned obeyed a general law. They set up a more or less chronic form of inflammation, the character of which depended partly upon the virulence of the organism and partly upon the relative susceptibility of the animal. Thus the same pathogenic organism might produce several types of inflammation, and the same type of inflammation might be produced by several pathogenic organisms. The most important lesson to be learnt from this discussion is the importance of making a systematic bacteriological examination of every case in the *post-mortem* room. The speaker was afraid that such a procedure was very much neglected, and he did not know of any *post-mortem* room in London where an adequate examination was conducted in every case.

Dr. GALLOWAY said that he was glad that the subject of pseudo-tuberculosis had been brought forward, as it might give the opportunity of disposing of a term which would inevitably lead to a confusion in our terminology if it were perpetuated. He noted with satisfaction that Dr. Woodhead and Dr. Martin agreed on this point. There was little doubt that there are many specific granulomata causally associated with different micro-organisms which produced lesions in the form of tubercles, more or less resembling both in naked-eye and histological structure the lesions of what we understand as true tuberculosis. He imagined that it was too late in the day to use the word "tuberculosis" as the designation for this group of diseases, and that we should still have to confine the name "tuberculosis" to the malady associated with Koch's bacillus tuberculosis. There would necessarily, therefore, come about a revival in the use of the term "infective granuloma" to connote this group of disease. He hoped that we

Digitized by Google

should not have a repetition of such terminology as that used by Dr. Flexner, of Baltimore, as a title to his important paper on the form of disease which he describes as "pseudo-tuberculosis hominis streptothricha." He considered that one of the results of Dr. Flexner's paper would be to draw the attention of pathologists to the fact that the organisms of the streptothrix family were capable of producing other forms of disease than those already recognised under the titles of actinomycosis and madura foot disease. He remarked that he considered the present was a favourable opportunity of bringing under discussion any forms of disease in the human subject resembling tuberculosis, but probably unassociated with Koch's bacillus tuberculosis. Recently he had had the opportunity of studying two forms of cutaneous lesions which might well be placed in this category.

1st. An example of a very characteristic form of granuloma occurring as a rule on the cutaneous surface of the lower eyelid, pursuing a chronic course, becoming finally absorbed, and sometimes accompanied by the occurrence of similar small tumours on the face. A histological examination recently conducted on such a tumour from the lower eyelid revealed a structure not unlike tuberculosis in its general arrangement. There was a readily recognisable focus of round cell infiltration, mainly of leucocytes, the central part of which underwent a peculiar form of necrosis; caseation did not occur, but the connective-tissue elements and the cells seemed to pass into a condition of "mucoid" degeneration previous to their absorption. Round the margin of this area of infiltration (especially the cutaneous margin) occurred numerous sharply-defined giant-cells. These giant,cells had numerous nuclei, usually peripherally arranged, and showing some differences, such as their regular contour and the exact distribution of their nuclei from the ordinary giant-cells of tuberculosis. In this particular instance he had examined numerous sections stained to demonstrate the presence of the bacillus tuberculosis with a completely negative result. Unfortunately, no material could be obtained for experimental inoculation, so that evidence from this source was not forthcoming. The rarity of diseases such as this makes a complete investigation difficult to make. He believed, however, that this form of disease was one that had been described as a giant-cell xanthoma of the eyelid, although none of the fatty material of true xanthoma is present.

Digitized by Google

2nd. Another example of a form of tumour which may come under this category had been brought to his notice by Dr. Radcliffe Crocker. In this case there appeared rapidly occurring nodular tumours of the skin, very closely resembling sarcomata. These tumours appear to be almost always multiple. Upon microscopic examination they were found to contain enormous numbers of giant-cells and undoubtedly presented close histological resemblances to giant-celled sarcomata, but these tumours underwent spontaneous involution, so that their clinical course was very different from true sarcomata.

Dr. Galloway wished simply to allude to these two forms of disease so that they should be borne in mind in investigation of the forms of growth resembling tuberculosis. He felt sure that one of the results of the discussion of this evening would be greater care in the diagnosis of tubercular structures. Every one admits that the occurrence of giant-cells and even the appearance of "giant-cell systems" such as have been described as diagnostic features of the tuberculosis of Koch are not sufficient to form an accurate diagnosis of the nature of the disease. The isolation of the associated micro-organisms, and especially the evidence obtained from experimental inoculation must become of supreme value. Judging from his slight experience, he considered that much light on the subject of the uncommon infective granulomata would be obtainable from the more careful study of the new forms of this class of disease observed in the tropics.

Professor McFadyean said that the term pseudo-tuberculosis was open to the very serious objection that it could not be employed in practice in strict conformity with any definition of it that could be framed. Adopting the widest definition possible, one might agree to include under the term all diseases other than that caused by Koch's bacillus, with lesions in the form of tubercles or nodules. But to any proposal to employ the term in this sense it might be objected in the first place that there was no need of a name for the heterogeneous affections which this would group together, and in the second place that several diseases etiologically distinct from tuberculosis, and already provided with names irrevocably fixed by long custom, had their most characteristic lesions in the form of tubercles. In glanders, for example, much more constantly than in tuberculosis, the primary lesions had the form

Digitized by Google

of tubercles, but no good purpose would be served by calling glanders a pseudo-tuberculosis. It would be absurd to call every disease other than tuberculosis with tubercle-like lesions pseudo-tuberculosis, and as a matter of fact the term had never been so employed. As far as one could trace any rule, in its application, it appeared to have been generally reserved for anatomically tuberculous diseases that were until recently of obscure origin, and which, but for Koch's discovery, or the application of bacteriological methods of diagnosis, might still have been confounded with true tuberculosis. For each such case a new name had to be invented, but if pseudo-tuberculosis were the name chosen for the first case of the kind it thereby acquired a new meaning (just as tuberculosis did after Koch's discovery of the specific bacillus) and must be reserved for that one disease. Unfortunately, however, it had already been applied in this way to several different diseases, and some degree of confusion was the inevitable result. He was inclined to think that it would be better in the future to discard the term altogether. With reference to the question of *post-mortem* diagnosis of true tuberculosis, he thought that within the same species, the ox, for example, the appearance of the lesions was so characteristic as to leave little room for error in the case of persons of experience. The demonstration of tubercle bacilli might appear to be theoretically desirable in every case, but in slaughter-house inspection it was not practicable, and if insisted upon it would greatly increase the proportion of errors, owing to the occasional difficulty or impossibility of finding tubercle bacilli with the microscope in undoubtedly tuberculous lesions. On the other hand examination of the histology of the lesions was generally sufficient to establish a diagnosis in tuberculosis of the horse, ox, and pig. Like some other observers, he had met with bacilli which might have been mistaken for tubercle bacilli owing to their staining reactions, but any such bacilli that he had encountered were morphologically different from the tubercle bacillus.

In conclusion, he described (with lantern illustrations) a number of lesions of the lower animals which he found were pretty frequently mistaken for tuberculosis.

Mr. ALEXANDER FOULERTON.—My object in taking part in this discussion was principally to protest against any use of the term "pseudo-tuberculosis." All this has, however, been done so

Digitized by Google

explicitly by Professor Sims Woodhead and most of those who have followed him, that it is unnecessary to add anything to what has already been said on that point. But, although the term pseudo-tuberculosis appears to be rightly discredited, it would seem that the fallacy upon which its use was founded is still, to a certain extent, prevalent. This fallacy is the supposition that there is anything anatomically characteristic about the tubercles which are found in the particular disease caused by the tubercle bacillus of Koch, and known as tuberculosis. I believe, on the other hand, that a tubercle is merely a common result of the action on the tissues of a large number of vegetable parasites, of which the bacillus of Koch is only one. And just as we do not speak of the abscess produced by one particular micro-organism as a "true" abscess, and of that produced by another micro-organism as a "pseudo"-abscess, so there is no reason for calling the tubercle produced by one parasite a true tubercle, and that produced by another parasite a pseudo-tubercle. And, further, I believe that it is impossible in the present state of our knowledge to distinguish with any measure of certainty by either anatomical or purely histological appearances between the tubercles produced by various different species of micro-organisms. Thus one might place side by side lungs containing grey miliary tubercles caused respectively by the bacillus of Koch, by the glanders bacillus, and by *Aspergillus fumigatus*, and I venture to assert that it would be impossible to say, from the anatomical appearances alone, which set of lesions were caused by each parasite. One would have first to identify the parasite itself. And with reference to this view of the matter I quite agree with what Dr. Washbourn said as to the frequent inadequacy of the pathological examination of the bodies of those who have died with what has, on clinical grounds only, been diagnosed as tuberculosis. The pathologist is too often satisfied with a mere naked-eye inspection of certain anatomical changes before confirming the clinical diagnosis, and this kind of confirmation appears to me to be of but little value. Bacteriology is an exact science, aud tuberculosis cannot now be regarded as the disease characterised by tubercles—for we know that there are many such—but as a disease due to infection by a specific parasite, the bacillus of Koch; and the pathologist is not justified in describing a case as being one of tuberculosis, unless the causative parasite has been positively identified. In illustration of my contention I may refer

Digitized by Google

to a remark made during this discussion by a member who said that aspergillosis must be uncommon because he had never seen a case of pulmonary phthisis which there was any reason, anatomical or clinical, for supposing was not caused by the tubercle bacillus. Now, aspergillosis is probably a fairly uncommon disease in man, but it seems certain that when a pulmonary aspergillosis does occur it may be just one of those conditions which cannot be distinguished from pulmonary tuberculosis by either anatomical appearances or clinical symptoms. Aspergillosis is a disease which has been carefully studied in France, especially since attention was called to the pathogenic action of *Aspergillus fumigatus*, in a paper by Dieulafoy, Chantemesse, and Widal, read at the Berlin Congress in 1890. Rénon and Lucet in particular have added much to our knowledge of the disease, the former having carefully described several cases of pulmonary aspergillosis in man, and the latter having given a very complete account of the infections by *Aspergillus fumigatus* as they occur in the lower animals. And, to repeat myself, it is quite clear that cases of pulmonary aspergillosis in man sometimes cannot be distinguished from pulmonary tuberculosis, either by the symptoms occurring during life, or by the anatomical character of the lesions found after death. And the same remark applies to pulmonary aspergillosis in the cow and other animals. From my own observations I can say that grey miliary tubercles resulting in the lungs of a rabbit after an intravenous injection of a culture of *Aspergillus fumigatus*, are anatomically indistinguishable from those which one may get after an intravenous injection of the tubercle bacillus in the same species. The distinction between the two conditions is, of course, easily made by bacteriological methods. With regard to what have been called pseudo-tubercle bacilli, I do not think that they can be very common. The smegma bacillus, after the usual staining with carbol-fuchsin and treatment with 33 per cent. nitric acid, is decolourised if the counter-staining is done with a solution of methylene blue in absolute alcohol. There are sometimes found in milk bacilli which, as Professor John McFadyean pointed out, resist the ordinary methods of decolourisation after staining with warm carbol-fuchsin, but which do not appear to be the tubercle bacillus of Koch. And these bacilli should be submitted to culture and inoculation tests before any opinion is given as to their nature. Before concluding I would like to briefly refer to the question of yeast infections. The pathogenic yeasts are of some

Digitized by Google

Digitized by Google

DESCRIPTION OF PLATE XI,

Illustrating Mr. Foulerton's remarks in Discussion on Pseudo-tuberculosis.

FIG. 1.—Tumour in popliteal space and posterior tibial region of a rabbit after inoculation with a pathogenic yeast (*Saccharomyces tumefaciens albus*). About half natural size.

FIG. 2.—Section through a similar tumour formed at site of inoculation in another rabbit. (× 600.)

FIG. 3.—Another portion of the same section as the last. (× 600.) Stained with methylene blue.

Digitized by Google

Digitized by Google

[illegible] E XI.

[illegible] Discussion on Pseudo-

[illegible] space [illegible] posterior tibial region of a rabbit [illegible] (*Saccharomyces* [illegible] *albus*).

[illegible] a similar tumour formed at site of inoculation in

[illegible] of the same section as the last. [illegible]

[illegible]

Digitized by Google

Fig. 1.

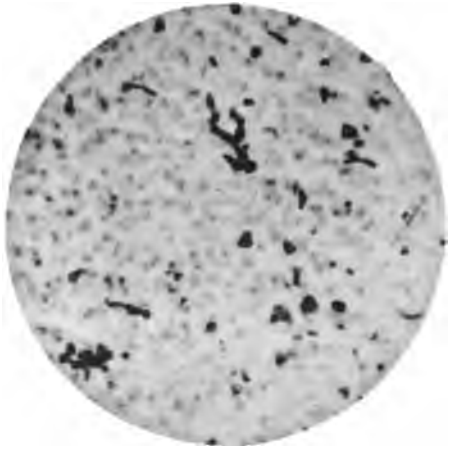

Fig. 2.

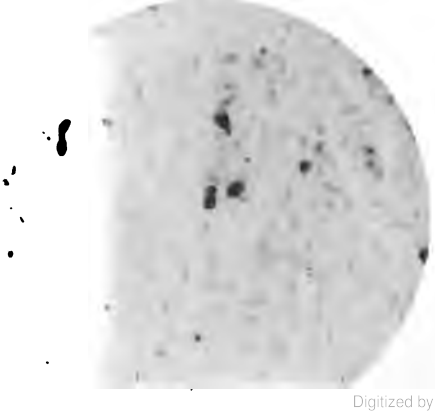

Digitized by Google

Fig. 3.

Digitized by Google

Digitized by Google

Fig. 1.

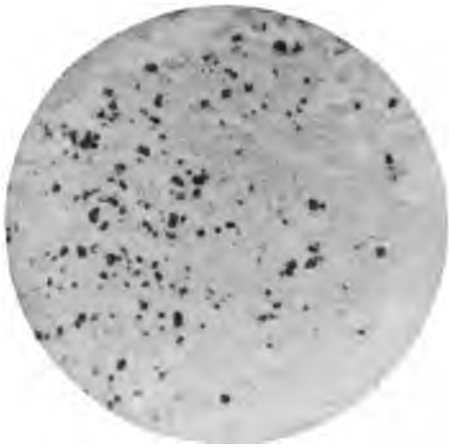

Fig. 2.

Digitized by Google

Fig. 3.

DESCRIPTION OF [illegible]

Illustrating Mr. [illegible]
tuberculosis.

FIG. 1.—Section [illegible]
with pathogenic [illegible]

FIG. 2.—Section [illegible]

FIG. 3.—[illegible]
culture twenty-four [illegible]
liver from same rabbit as last

Digitized by Google

Digitized by Google

DESCRIPTION OF PLATE XII,

Illustrating Mr. Foulerton's remarks in Discussion on Pseudo-tuberculosis.

FIG. 1.—Section through nodule on diaphragm of rabbit after inoculation with pathogenic yeast. (× 20.)

FIG. 2.—Section through same nodule on diaphragm. (× 600.)

FIG. 3.—Photograph of living culture of *S. tumefaciens albus*. From sub-culture, twenty-four hours old, on glucose agar, direct from secondary nodule in liver from same rabbit as last.

Digitized by Google

Digitized by Google

interest in connection with the present discussion because they are capable of producing tubercles which are indistinguishable anatomically or histologically from tubercles produced by other vegetable parasites. I may perhaps also claim that the particular specimens which [Pls. XI, XII] I am showing to-night have a further interest as being the first specimens of yeast infection which have been shown as such in this country. The first specimen can only be described as being probably a result of yeast infection, since, although it was thought that yeast cells could be identified in fresh "teased out" preparations, all attempts to isolate the yeast by culture failed. The specimen consists of a portion of the rump muscles of an ox, and shows a number of round white nodules, which have the structure of granulomata. I believe that the case is in its nature similar to the disease which Prof. Tokishige has described as being commonly found in cattle and horses in Japan, where it is known as "worms." Tokishige has practically proved that the disease is a blastomycetic infection.

The other specimens and sections shown under the microscope are all the result of experimental inoculations with a pathogenic yeast (*Saccharomyces tumefaciens albus*), and I may just mention that quite similar results may be obtained with a number of other species of blastomycetes. The first of these specimens consists of the lungs of one of three white rats, each of which received a small subcutaneous injection of this yeast. The animals died at intervals of three weeks, five months, and six months after the inoculation, and all presented a number of yellowish caseous nodules in their lungs after death. These particular lungs came from the rat which died at the end of six months, and are extensively infiltrated with the caseous nodules. These changes, again, can only be said to be probably due to the yeast infection, as I was not able to identify the yeast cells in the tissues. The next specimen shows a largish, firm, nodulated tumour in a rabbit, partly projecting into the popliteal space and partly embedded in the posterior tibial muscles. This tumour formed at the site of inoculation, and the animal died on the fourteenth day. The tumour is a granuloma, and from it a pure culture of the yeast was obtained. The remaining specimens came from a rabbit which died on the eighth day after a subcutaneous inoculation in the lumbar region. A tumour developed at the site of inoculation, and numerous tubercles were found in the lungs, liver, and kidneys, and scattered over the

Digitized by Google

diaphragm. The primary tumour and the secondary tubercles all presented the characters of granulomata. Cultures of the yeast inoculated were recovered from the primary tumour, from the tubercles in the liver, kidneys, and diaphragm, and also from some urine which was found in the bladder. The first two slides show sections through the primary tumour. In them numerous yeast-cells, many of which are "budding," can be seen. Some of the cells show an internal concentric arrangement of their contents, which reminds one of the similar arrangement described by San Felice and Roncali as occurring within the alleged yeasts found by them in carcinomata. The next slide shows a section under a low magnification through one of the tubercles on the diaphragm. These tubercles were, except for the contained yeast, not to be distinguished from what one might have found in a case of tuberculosis. The next slide shows a section of the same tubercle under a higher power of the microscope. A large number of yeast cells can again be seen, many of which appear to be surrounded by a distinct capsule. A capsule, like the internal concentric arrangement, has also been described in connection with the alleged cancer yeasts. The next two lantern slides show photographs of cultures of the yeast growing on glucose agar tubes inoculated from the primary tumour and from a tubercle of the liver. And the last slide shows a photograph of the living yeast cells from a culture obtained from the liver.

Mr. PAKES quite agreed with Prof. Sims Woodhead that the term pseudo-tuberculosis was one which should now fall into disuse. A great amount of confusion always arose when the term pseudo was applied, as was evidenced by the pseudo-diphtheria bacillus. When, further, such conditions as pseudo-rickets, pseudo-erysipelas, and pseudo-leprosy were described the confusion became still worse. He thought that it would be preferable to attach a person's name to a condition until its pathology was determined rather than to tack the term pseudo on to a condition which merely bore a superficial resemblance to a condition whose pathology was known. The condition referred to by Prof. Woodhead as aspergillo-pneumonomycosis was a very interesting one, and one which had been emancipated from its connection with tuberculosis. In this disease the pathological lesions very closely resembled those produced by the *B. tuberculosis*. The *Aspergillus fumigatus* could

Digitized by Google

cause lesions resembling both the acute and chronic lesions produced by the *B. tuberculosis*. He had come to the conclusion that there were more cases of aspergillosis than was generally imagined, and he suspected that some of the cases of supposed phthisis which recovered were possibly due to this cause. It was not very rare to find moulds in fresh sputum, and on more than one occasion he had been struck with the large number of these organisms. On one occasion he had made cultivations, and found that the culture was an almost pure one of the *Aspergillus fumigatus*. The observation of Prof. Sidney Martin, that tubercle inoculated in, say, the groin of a guinea-pig was always followed by infection of the glands and lymph channels was, in his opinion, quite sufficient reason why tubercles found in the liver, omentum, &c., after inoculation without any chain of glands should not be called pseudo-tuberculosis. He had recently had such a case, which to the naked eye presented tubercles in the omentum. On section, however, small breaking-down cavities were found which contained a bacillus which stained easily with carbol-methylene blue.

Dr. LAZARUS-BARLOW.—It is with great diffidence that I venture to put in a word for the retention of the term pseudo-tuberculosis after I have heard the strong expressions of opinion for its abolition that have fallen from the lips of the speakers who have preceded me. And yet I think there is a certain number of cases in which use of the term may be distinctly advantageous. I suppose that its recognition is really a cause for self-congratulation rather than of reproach, a sign of knowledge rather than of ignorance. If we assume for the moment that the name "pseudo-tuberculosis" is to be retained, the question at once arises, To what class of case should it be applied? It is quite clear that the purely anatomical conception of tubercle cannot be the criterion. Under that condition we should be obliged, as Prof. McFaydean has said, to include glanders in the category, and besides that disease a host of others, such as actinomycosis, leprosy in certain forms, even cases of malignant disease where the manifestations are of the nodular type. Indeed, since the anatomical tubercle is simply the visible expression of a reaction on the part of the normal tissues of the body to an irritant of a certain degree of intensity, the term would become so wide and indefinite as to be quite useless. Quite extraneous conditions, too, might easily be brought into the group

Digitized by Google

"pseudo-tuberculosis" if the mere appearance were made the criterion. Thus, last week I had in the *post-mortem* room an exquisite example of the confusion that would ensue if such a mode of defining pseudo-tuberculosis were adopted. The case was one in which there were minute emphysematous bullæ in the lung. They were the size of a millet seed, situated immediately beneath the pleura, raised so that they could be felt easily, firm and translucent. They were apparently typical "grey granulations of tubercle." But when a section was made with a knife they, of course, collapsed and their nature was manifest. This case seems to me quite parallel with the case of verminiform pseudo-tuberculosis mentioned by Prof. Woodhead. In both cases—and probably a very large number of other cases of so-called pseudo-tuberculosis are subject to the same remark—a little extra knowledge or a little extra care completely severed them from tuberculosis, not because of their difference of appearance, but because of their difference in ætiology. This brings us to the question whether the *B. tuberculosis* is to form the criterion. So far as concerns the actual recognition of what is *tubercular*, there can be no doubt that if the bacillus of tuberculosis is found we must undoubtedly pronounce the lesion a tubercular one. It follows from this that a pseudo-tubercular lesion can only be either one which appears to be tubercular and is associated with a bacillus having the morphological and tinctorial properties of the tubercle bacillus but yet *not* the tubercle bacillus, or one which appears to be tubercular and is associated with no micro-organism at all so far as can at present be determined. Conditions which, however like tubercular lesions they may appear to the superficial observer, are nevertheless definitely associated with some parasite of whatever kind, I would call by distinctive names, however many were required, but I would not speak of them collectively as examples of pseudo-tuberculosis. We have in ordinary life a somewhat similar example. We speak of a sovereign and of a counterfeit sovereign. The counterfeit sovereign must be so like the real coin that it will deceive the unwary and sometimes even the wary, but it must fail in the essential point: it is not made of gold. More than this, the counterfeit sovereign, if it is going to pursue its career of usefulness, must rigidly withhold information—at least from the superficial or unskilled observer—as to the metal of which it is composed. So, I think, should be the case with pseudo-tuberculosis. It is not sufficient that a lesion should be anatomically and clini-

Digitized by Google

cally like tubercle; it is not sufficient that it should not be caused by the *B. tuberculosis*; it must rigidly withhold information as to its ætiological factor. Directly it yields up that information I would have it referred to this category or that to which it legitimately belongs. It would be in the highest degree unscientific to term a condition "pseudo-tuberculous" when we have really good evidence that it is caused by some mould or animal parasite or other factor. And yet herein lies the weakness of the position. A very considerable number of the cases that have been grouped together under the name of pseudo-tuberculosis are cases in which some mould or streptothrix is present in the tissues, and in which it is uncertain whether the micro-organism is causal or accidental. There is no inherent impossibility in the claim that a lesion resembling that caused by the *B. tuberculosis* may be caused by a parasite other than *B. tuberculosis*. There is no reason why the moulds that have been found associated with lesions apparently tubercular should not really be causal; that, for example, the case should really be an aspergillosis, and not a tuberculosis at all. Until, however, the scientific proof is complete in these cases I do not know that I should greatly object to their being temporarily classed together as pseudo-tuberculoses.

But there is one point on which I should lay very great stress. I am strongly of opinion that in a very large number of cases of so-called pseudo-tuberculosis, whether micro-organisms other than *B.* tuberculosis are obvious or not, a prolonged search would reveal the presence in the lesion of the true tubercle bacillus, and would therefore determine that the condition was not one of pseudo-tuberculosis but a true tuberculosis. There came under my notice last year a very pronounced example in support of this statement. A cab-driver died in hospital after an illness of a few months in which pronounced wasting, severe night sweats, and troublesome cough with some expectoration were the most important symptoms. As was natural, it was diagnosed to be pulmonary tuberculosis. At the autopsy there was found pneumonic consolidation with a yellowish colour of the right lung from apex to base; this consolidation was more advanced in the upper and middle lobes, where it was so considerable that portions of lung sank in water. There was not a great deal of excavation, but had the case lasted longer the degree of caseation was so great and the softness of the caseous material was such that the excavation would have proceeded by strides, and

Digitized by Google

the whole lung would have become converted in a short time into a huge vomica. As it was, there were numerous vomicæ the size of a small pea, and filled with purulent material, and one or two the size of a bean. In the left lung anteriorly there was a small patch of consolidation of the same type. The clinical diagnosis was naturally confirmed by the macroscopic appearances of the lung. When, however, I came to examine microscopical sections, I found that the "caseous pneumonia" was permeated by a strepto-bacillus of very definite appearance in all directions. This strepto-bacillus could not have gained access to the tissues after they reached my hands, for the material was preserved in strong spirit until it was ultimately embedded in paraffin, and since they were not confined to the surfaces but permeated the lung throughout, there is reason to believe that they were present in the body before death. As to the actual part they played in causing the condition it is impossible to say, and for my present purpose it is immaterial. The case obviously assumed at the moment of their discovery a different complexion, and it became possible that it was one of pseudo-tuberculosis and not one of true tuberculosis. I therefore prepared and stained by the Ziehl-Neelsen method with the greatest care over eighty sections of the material, in order, if possible, to determine the point. It was not till I reached the fiftieth section that I found a single tubercle bacillus, but in the fiftieth section I found a region where *B. tuberculosis* was present in great numbers and was quite unmistakable. I should have been absolutely wrong had I spoken of the condition as a pseudo-tuberculosis, and yet it required the examination to proceed far beyond the number of specimens ordinarily examined for the purpose before the diagnosis was cleared up. I cannot express my opinion in sufficiently strong terms that a similar result would follow in a large number of cases of "pseudo-tuberculosis" if a sufficient number of sections were examined for tubercle bacilli.

If, then, my opinion is that of cases of "pseudo-tuberculosis" a large number should be given places in definite categories, and that not a few are really cases of true tuberculosis, the question is why I should wish the term to be retained and what class of case I should include therein? I think there is at present, and probably for some time there will remain, a residuum of cases upon which no other opinion can be pronounced than that they are extremely like true tuberculosis and yet are in certain respects unlike it. For

Digitized by Google

these I would reserve the term. Thus I should feel inclined to speak of the condition so frequently met with in the last stages of diabetes mellitus as a pseudo-tuberculosis when it is not definitely proved that it is a true tuberculosis, a matter often of extreme difficulty or impossibility. And other examples rise to one's mind; I will grant that pseudo-tuberculosis is probably a term destined to vanish, but at all events at present I believe that it may be made to serve a useful purpose so long as its range is defined more strictly than has hitherto been the custom.

Dr. WETHERED said that in 1891 he had the opportunity of investigating "pseudo-tuberculosis," the material being obtained from two cultures sent from Paris of what was then known as *the* bacillus of pseudo-tuberculosis. At first there was some difficulty in obtaining pure cultures, but this was eventually accomplished by means of plate cultivations. The characteristics of the bacilli and colonies were the same as those already described by Dr. Sims Woodhead. The guinea-pigs inoculated died between the ninth and twelfth day. In every case an abscess formed at the site of inoculation. The animals inoculated from pure cultures showed small white nodules scattered through all the organs, which on naked-eye examination simulated the appearance seen in miliary tuberculosis. Unless microscopic and bacteriological examinations had been made, the conclusion might very easily have been arrived at that the animal had died from tuberculosis. He agreed with the remarks made by Mr. Pakes as to the presence of aspergillus in the sputum of cases of supposed pulmonary tuberculosis. He had occasionally found the mould when diligent search failed to discover the tubercle bacillus. He echoed the remarks of previous speakers as to the desirability of doing away with the term pseudo-tuberculosis.

Professor WOODS HUTCHINSON.—I would like to call the attention of the Society to a few specimens illustrating some of the forms of pseudo-tuberculosis which I have collected in the past three months at the Zoological Gardens. One is an aspergillus "tuberculosis" of the lungs of a Trumpeter crane (*Psophia crepitans*) showing a number of brown masses of mould-growth just under the pleura. There were also several large plaques of mould upon a thick, cheesy basis in the air sacs of the bird. Another is a "worm-tuberculosis" of the lungs of a Capuchin monkey, in which the

Digitized by Google

coils of the worms can be clearly seen in the yellow nodules with a hand-lens. Another is a probable yeast-tuberculosis of the lungs, liver, and kidneys of a prairie-dog, which, however, I have not yet had time to examine microscopically. The lung of a coyote studded with little, shotty nodules of bone, and the lungs of an agouti dotted all through with nodules and scars containing black pigments, are merely shown as imitations of some of the lesions usually associated with tubercle.

The strongest impression made upon my mind by even my limited opportunities of study of these pseudo-tuberculoses is that they are an extremely heterogeneous and ill-assorted group. Almost their only connection with each other and with the great process whose "pseudo" name they bear, is that each of them resembles in some one or two points—often most crudely—true tuberculosis. Sometimes this resemblance consists solely in the fact that tubercles, in the primitive sense of "little tubers," are produced, and the mind of the observer would needs be in a state of primæval innocence in order to even temporarily confuse them with the handiwork of the *B. tuberculosis*.

Bearing in mind the three criteria, gross anatomy, microscopic appearance, and clinical history or systemic effects, there is not one of them (with the exception of some forms of the bacillary variety) which would conform to more than two of these tests and very few more than one. Microscopic examination will promptly distinguish all forms except the bacillary. Naked-eye appearances would easily disqualify all except the yeast, the bacillary, and a few forms of the mould varieties, and even the yeast and aspergillus nodes can be readily discriminated by a moderately expert eye. Only two varieties, the white aspergillus and the yeast resemble the "true" disease in their clinical history or systemic effects. I have seen the intestines of fat wethers in prime condition, killed in fact for export mutton, thickly studded with worm-tubercles, and the lungs and peritoneum of monkeys which had clearly died of other diseases, similarly affected.

In short a thorough examination from all points of view reduces the danger of any of these "pseudo" lesions being mistaken for true tuberculosis, to almost a "*quantité négligeable.*"

Then why continue the use of the term pseudo-tuberculosis? As already repeatedly stated, there is really no scientific ground for so doing, but, even at the risk of being considered reactionary, I should

Digitized by Google

like to say a few words in its favour, on the ground of practical convenience. The system of naming things or conditions by what they are *not* can hardly be endorsed on rational grounds, although it has one advantage, it leaves opportunity for the advance of our knowledge. We have only one chance in a thousand of being egregiously wrong. And there are not a few of our "positive" names which had better never have been applied, such as "uræmia," "pyæmia," "melancholia," "epilepsy," "lunacy."

And yet under the circumstances this term will probably continue to be used on account of its convenience. For it curiously so happens that the principal practical interest and importance of all these "pseudo" conditions centres in what they are *not*. From the point of view of the clinician, the veterinarian, the meat-inspector, if they are recognised as *not* tuberculosis, they may be practically disregarded. It matters little what they are, so far as prognosis is concerned, for, with the exception of the rare white aspergillosis and the yeast-tuberculosis, they give rise to no systemic infection or serious symptoms of any kind. To the pure pathologist, of course, the distinctions are of great importance, and he will find the use of such a "shot-gun" term as pseudo-tuberculosis a hindrance and discard it. But to the clinician it is of value to know that there are a rarity of conditions which simulate tuberculosis and yet have none of its fatal significance. And this clumsy term is really the only one which will cover this group. So widely do its members differ, that the only thing which unites them all is their liability to be mistaken for tuberculosis. Another practical difficulty in the way of getting rid of the term is the absence of a substitute. The group would have to be broken up into at least ten or fifteen different varieties, each having a new, strange, and terrible name, such as *aspergillosis*, *streptothricitis*, *saccharomycosis*, &c., which would convey no meaning whatever to the ear of other than an expert biologist. Instead of one foolish but easily understood name, we should have a dozen scientific but well nigh incomprehensible ones. To continue an inept or even unfortunate term whose application is clearly understood, is often better than to change to a dozen new terms, more significant, it is true, but whose meaning future developments may also prove to be mistaken. Let it be clearly understood that pseudo-tuberculosis simply means any process which imitates the anatomical lesions of the *B. tuberculosis*, and its retention will not only be justifiable, but of much practical

Digitized by Google

value. It is perhaps no harm for us to be reminded, in these days of a rather too botanical pathology, that there are a number of organisms and even agencies capable of exciting that swarm of angry leucocytes and new cells around an intruder which was known as the old "anatomical tubercle." And as all observers unanimously agree that 90 per cent. of all apparent "tuberculosis" are due to the action of the "genuine" bacillus, I think there is little danger of disturbing in any way the supremacy of the latter, or leading to any confusion in our now clear and definite conceptions of the disease, by retaining the harmless "pseudo" term as a convenient designation for this insignificant minority.

Digitized by Google

REPORT OF THE COMMITTEE

OF THE

PATHOLOGICAL SOCIETY OF LONDON

APPOINTED

TO CONSIDER THE NOMENCLATURE OF THE CONDITIONS SOMETIMES DESCRIBED AS PSEUDO-TUBERCULOSIS.

I.

The term "pseudo-tuberculosis" has been applied to several distinct morbid processes, which agree with one another only in the fact of producing in the tissues small nodular masses which have been considered to resemble "tubercles."

Amongst the various morbid processes which have been so denominated are the following:

(*a*) *A number of bacterial infections, caused by bacilli and cocci of various species.*

As examples of such may be mentioned—

1. A case of pseudo-tuberculosis in man, described by Du Cazal and Vaillard (1891). In this case a number of caseous tubercles were found on the peritoneal membrane and in the pancreas. From these lesions a bacillus, differing from the tubercle bacillus of Koch, was isolated. This bacillus was not pathogenic for guinea-pigs, but produced in rabbits a condition comparable with that occurring in man.

2. Zooglœa pseudo-tuberculosis of the guinea-pig and rabbit ("tuberculose zoogléique"). This condition was first described by Malassez and Vignal (1883); it resulted in the animals named after inoculation with portions of a nodule from the forearm of a child who had died with a tuberculous meningitis. The tubercle bacillus of Koch could not, however, be identified in the nodule in question. The first two series of rodents inoculated presented nodules in which a coccus with distinctive characters was found.

Digitized by Google

In the third series of inoculations the tubercle bacillus of Koch was found in addition to the characteristic coccus. The exact nature of the conditions in these particular cases must, therefore, remain doubtful. Chantemesse (1887) produced a zooglœa pseudo-tuberculosis of a similar kind in guinea-pigs by introducing into the peritoneum small portions of cotton wool through which had been filtered the air of a hospital ward in which there were a number of phthisical patients.

Nocard (1889), Zagari (1890), and Parietti (1890) described zooglœa pseudo-tuberculosis in the guinea-pig, occurring respectively after inoculation with the sputum of a cow which was suspected of tuberculosis, as a natural disease, and after inoculation with cow's milk. Eberth (1885) had also recorded two such cases occurring naturally in the guinea-pig.

3. Zooglœa pseudo-tuberculosis of fowls, described by Nocard (1885).

4. Bacillary pseudo-tuberculosis of rodents. Charrin and Roger (1888), and Dor (1888), described this condition in the guinea-pig, and Eberth (1885) in the rabbit. Legrain (1891) described a similar condition occurring in the rabbit after inoculation with sputum from phthisical patients.

5. Pseudo-tuberculosis of the ox. Courmont (1889) isolated from some nodules on the pleura of a cow a bacillus, differing from the tubercle bacillus of Koch, which produced a pseudo-tuberculosis in the guinea-pig. Nuvoletti (1894) has also described a bacillary pseudo-tuberculosis occurring in calves.

6. Pseudo-tuberculosis of the horse, described by Pfeiffer (1889). The bacillus isolated produced a pseudo-tuberculosis in the hare, the rabbit, the guinea-pig, tame mice, and house mice.

7. Pseudo-tuberculosis of mice, described by Kutscher (1889). This disease occurred naturally in some laboratory mice; the bacillus isolated was not pathogenic for either the guinea-pig or rabbit.

8. Pseudo-tuberculosis of sheep, described by Preisz and Guinard (1891), by Preisz and Morey (1893), and by Turski (1897); the bacillus isolated by these writers was pathogenic for both the rabbit and guinea-pig.

9. Pseudo-tuberculosis of swine, described by Galli Valerio (1896), by Turni (1896), and by Deleidi (1896).

Digitized by Google

(*b*) *Blastomycosis.*

Gilchrist and Stokes have adopted a somewhat similar nomenclature in describing a case of "pseudo-lupus vulgaris" caused by a blastomyces.

(*c*) *Streptotrichosis.*

Amongst streptothrix infections the following have been described:

Pseudo-tuberculosis (*cladothrica*) by Eppinger.

(NOTE.)—The fungus causing this disease was classed by Eppinger amongst the cladotriches; it is now recognised as a streptothrix (*S. asteroides*).

Pseudo-tuberculosis hominis streptotricha, by Flexner.

(*d*) *Aspergillosis.*

Infection by *Aspergillus fumigatus* was described as a pseudo-tuberculosis by Dieulafoy, Chantemesse, and Widal, and other authors have used the same term as descriptive of the pathological results of infection by certain mould fungi.

(*e*) *Protozoal infection.*

Gilchrist and Rixford have described a case of "Protozoan or Coccidioidal pseudo-tuberculosis."

(*f*) *Pathological conditions resulting from the presence of higher animal parasites in the lungs.*

Hartenstein refers to a condition resulting from the presence of *Echinococcus* in the lungs of cattle as a pseudo-tuberculosis; and nodules ("Wurm-Knötchen") brought about by the presence of the ova of *Strongylus vasorum* in the lungs of cats (Laulanié, 1884), and in the lungs of horses, cattle, sheep, and dogs by the ova or larvæ of nematode worms, have been described as "verminous pseudo-tuberculosis."

II.

We think that confusion has arisen from the employment of the word "tubercle" in two senses:

Digitized by Google

(1) As a general anatomical term for a small nodule.

(2) In a specific sense for the nodular lesions of the disease produced by the tubercle bacillus of Koch.

III.

We think that the word should no longer be used as a general anatomical term; but if used at all, it should be only as a designation of the nodular lesions produced by the tubercle bacillus.

To prevent ambiguity, however, we suggest that all lesions having the form of "tubercles" should be called generally "nodules," those produced by Koch's bacillus being distinguished as "tubercular nodules;" and that the nodules produced by other causes should in like manner be distinguished by a prefix indicative of their cause, if known,—as, for example, "glanders nodule," "aspergillar nodule," or, if their cause is not known, by some distinctive designation not involving any reference to the word "tubercle."

We further suggest that the diseases themselves (as distinguished from the lesions produced) should, when possible, be designated in accordance with the plan indicated in headings (*b*), (*c*), and (*d*), "Blastomycosis," &c.

The term "pseudo-tuberculosis" would then become superfluous, and ought in our opinion to be discarded altogether.

J. F. PAYNE, *Chairman.*
J. MCFADYEAN.
S. G. SHATTOCK.
J. W. WASHBOURN.
G. SIMS WOODHEAD.
ALEX. G. R. FOULERTON, *Secretary.*

May 6th, 1899.

Digitized by Google

INDEX.

SUBJECTS.

(*For the list of Authors see p.* 371.)

PAGE

ACHROO-AMYLOID LIVER, spleen, and kidneys (W. J. Hadley) . 134

ACROMEGALIC SKULL, and that of a normal giant (S. G. Shattock) . 185

ACTINOMYCOSIS of the tongue (L. Cooper) 61

ADENOMA, multiple, in contracted kidney (F. P. Weber) . . 179
„ of breast, associated with cyst and calcareous degeneration (C. F. Beadles) 223

ADENO-LIPOMA of submaxillary salivary gland (H. J. Waring) . 67

ADRENAL, cyst of (H. D. Rolleston) 214
„ cystic disease of (R. Crawfurd) 212
„ lesions of, in the insane (C. F. Beadles) 214

ANÆMIA, pernicious, peculiar condition of the colon in; necrosis of the mucosa (H. M. Fletcher) 127
„ splenic, with internal hæmorrhages, in infants (G. B. Hunt) . 209

ANEURYSM of the splenic artery (H. D. Rolleston) . . . 55
„ — (W. S. Lazarus-Barlow) 57

ANTRUM, vacuolated, spheroidal-celled carcinoma of (H. D. Rolleston) . 251

AORTA, perforation of, by ulcer (probably syphilitic) of trachea (N. Dalton) 30

APPENDIX VERMIFORMIS: See *Vermiform appendix.*

ARTERIES, middle cerebral, embolism of; rheumatic endocarditis; carcinoma of the pancreas and liver (L. Freyberger) . . . 1

ARTERY, right common iliac, embolism of; incipient gangrene of leg; cardiac thrombosis, in typhoid (W. Hunter) . . . 52
„ splenic, aneurysm of (H. D. Rolleston) 55
„ — (W. S. Lazarus-Barlow) 57

ASPERGILLOSIS (?) of lung of horse (A. G. R. Foulerton) . . 272

ATROPHY, symmetrical senile, of parietal bones (H. M. Fletcher) . 195

AURICLE: See *Heart.*

BILE-DUCTS, syphilitic stricture of (W. S. Lazarus-Barlow) . . 158

BILIARY CALCULUS: See *Calculus, biliary.*

BLACK-WATER, or hæmoglobinuric fever (W. H. Crosse and W. C. C. Pakes) 273

BLOOD-FILMS, the technique of (W. C. C. Pakes and R. Howard) . 328

Digitized by Google

PAGE

BONE, fracture of cervical portion of spinal column (H. P. Potter) . 196

BRACHIAL PLEXUS, fibroma of, associated with molluscum fibrosum (T. Carwardine) 27

BREAST, adenoma of, associated with cyst and calcareous degeneration (C. F. Beadles) 223
„ "butter" cyst of (H. B. Robinson) 227
„ cystic disease of, in a boy (D'Arcy Power) . . . 225

BUFFY COAT, significance of, in the shed blood of acute pneumonia, etc. (S. G. Shattock) 279

CALCANEUM, central spindle-celled sarcoma of (P. de Santi) . . 198

CALCULI, biliary, healed perforation of duodenum after passage of (C. F. Beadles) 113

CALCULUS, biliary, in children (G. F. Still) . . . 151

CARCINOMA, columnar-celled, arising in remains of Meckel's diverticulum (?) at the umbilicus in an adult (C. D. Green) . . . 243
„ cystic papilliferous; sequel to a case of, arising in accessory thyroid (?), and leading to gland infection (A. E. Barker) . . 251
„ squamous-celled, in substernal region (W. S. Lazarus-Barlow) . 248
„ vacuolated spheroidal-celled, of antrum (H. D. Rolleston) . . 249
„ of stomach. See *Stomach.*

CARDIA: See *Stomach.*

CHROMOCYTE CLUMPING in acute pneumonia and certain other diseases, and the significance of the buffy coat in the shed blood (S. G. Shattock) 279

CIRRHOSIS, chronic, acute degeneration of liver-cells supervening in the course of (F. P. Weber) 136

COLITIS, diffuse ulcerative, with secondary acute interstitial hepatitis (T. D. Lister) 130

COLON, peculiar condition of (necrosis of mucosa), in pernicious anæmia (H. M. Fletcher) 127

CORD, spinal: See *Spinal cord.*

CYST, "butter," of breast (H. B. Robinson). . . . 227
„ dermoid, multiple abdominal (A. C. Latham) . . . 232
„ multiple, in relation with an inguinal hernial sac in a woman (H. B. Robinson) 230
„ of the adrenal (H. D. Rolleston) 214

CYSTIC DISEASE of breast in a boy (D'Arcy Power) . . . 225
„ of adrenal (R. Crawfurd) 212

DEFICIENCY and redundancy of limbs, congenital (R. Barwell) . 319

DERMOID CYSTS: See *Cyst, dermoid.*

DEXTROCARDIA, left superior vena cava, endocarditis (N. Dalton) . 41

DIABETES MELLITUS, atrophied pancreas from a case of (T. W. P. Lawrence) 171
„ sarcoma of pancreas (T. Churton) 178

DIARRHŒA, fatal summer, with acute enteritis, two cases, bacteriology of (F. W. Andrewes) 118

DILATATION of the right ventricle upwards and to the left (T. S. Wilson) 41

Digitized by Google

PAGE

DIPHTHERITIC PARALYSIS, further evidence on the pathology of (F. E. Batten) 22

DUODENAL ULCER from a case of melæna neonatorum (T. D. Lister) . 111

DUODENUM, healed perforation of, after passage of gall-stones (C. F. Beadles) 113

EMBOLISM of both middle cerebral arteries; rheumatic endocarditis; carcinoma of the pancreas and liver (L. Freyberger) . . 1

„ of the right common iliac artery; cardiac thrombosis in enteric fever; incipient gangrene of leg, etc. (W. Hunter) . . . 52

ENDOCARDITIS DEXTROCARDIA, left superior vena cava (N. Dalton) . 41

ENTEROLITH from the rectum (S. G. Shattock) 134

EPITHELIAL TUMOURS of skin, probably congenital in origin (nature ambiguous) (H. R. Crocker) 220

FAT NECROSIS, lesions of the pancreas with (C. F. Beadles) . . 174

FIBROMA from the neck of a child (congenital) (H. A. Lediard) . 223

„ of brachial plexus, associated with molluscum fibrosum (T. Carwardine) 27

FIBRO-SARCOMA, multiple, of scalp, of nineteen years' duration; removal; recurrence in lungs (P. de Santi) 234

FRACTURE of cartilaginous portion of trachea; fractures of sternum and ribs (W. S. Lazarus-Barlow) 32

GALL-STONES: See *Calculus, biliary.*

GASTRIC, GASTRECTOMY, etc.: See *Stomach.*

GERMICIDAL ACTION, the relations of chemical composition to (J. Ritchie) 256

GIANT, skull of a normal, and an acromegalic skull (S. G. Shattock) . 185

GLAND: See *Breast, Pituitary*, etc.

GLIOMA of pineal body (T. W. P. Lawrence) 12

HÆMOGLOBINURIA, or black-water fever (W. H. Crosse and W. C. C. Pakes) 273

HEART, left auricle, extreme dilatation of, without mitral stenosis (H. M. Fletcher) 48

„ right ventricle, dilatation of, upwards and to the left (T. S. Wilson) . 41

„ spontaneous rupture, two cases of (C. F. Beadles) . . . 49

„ thrombosis of left ventricle in typhoid; embolism of the right common iliac artery; incipient gangrene of leg; infarcts in spleen and kidneys (W. Hunter) 52

HEPATITIS, acute interstitial, secondary to diffuse ulcerative colitis (T. D. Lister) 130

HERNIA, cysts in relation with sac of an inguinal (H. B. Robinson) . 230

HYPERTROPHY, congenital, of the pylorus; three cases, with table of normal measurements (G. F. Still) 86

„ congenital, of pylorus (H. M. Fletcher) 98

„ idiopathic, of the œsophagus (H. D. Rolleston) . . . 69

„ of the right lung, obliteration of left (N. Dalton) 38

Digitized by Google

PAGE

INSANE, lesions of the adrenal in the (C. F. Beadles) . . 214
INTESTINE: See *Colon, Rectum.*
INTUSSUSCEPTION, two unusual cases of (D'Arcy Power) . . 121

KIDNEY, multiple adenomata in contracted (F. P. Weber) . . 179
„ small lipoma of (F. P. Weber) 181

LIMBS, congenital deficiency and redundancy of (R. Barwell) . . 319
LIPOMA, a peculiar, of the groin (C. F. Beadles) . . . 229
„ of kidney (F. P. Weber) 181
LIVER, achroo-amyloid, spleen, and kidneys (W. J. Hadley) . . 134
„ cirrhosis, apparently due to congenital syphilis, with thrombosis of the hepatic veins (T. Churton) 145
„ cirrhosis of, probably syphilitic, associated with thrombosis of the hepatic vein (W. S. Lazarus-Barlow) 146
„ condition of, in hepatic and portal thrombosis (H. D. Rolleston) . 148
„ cysts in, containing living *Paramœcia coli* (A. E. Russell and E. F. Buzzard) 149
„ diffuse fibrosis of, in congenital syphilis (H. M. Fletcher) . . 138
„ diffuse syphilitic changes in (adult) (F. P. Weber) . . 142
„ primary carcinoma of, spheroidal-celled (C. D. Green) . . 166
„ tuberculous cavities in (H. M. Fletcher) 160
LIVER CELLS, acute degeneration of, supervening in the course of chronic cirrhosis (F. P. Weber) 136
LUNG, hypertrophy of the right, obliteration of left (N. Dalton) . 33
„ left, a case of sarcoma of, and of the mediastinum (C. D. Green) . 37

MAMMA: See *Breast.*
MECKEL'S DIVERTICULUM; the source of a columnar-celled carcinoma (?) at the umbilicus, in an adult (C. D. Green) . . . 243
MELÆNA NEONATORUM, duodenal ulcer from a case of (T. D. Lister) . 111
MELANOTIC SARCOMA: See *Sarcoma, melanotic.*
MOLLUSCUM FIBROSUM; fibroma of brachial plexus associated with (T. Carwardine) 27
MYCOSIS, aspergillar (?) of horse's lung (A. G. R. Foulerton) . . 272
MYOMA of œsophagus (H. D. Rolleston) 73
„ of stomach (A. G. R. Foulerton) 85
„ of prostate, removed (T. Carwardine) 183
MYXOMA from the thigh (H. D. Rolleston) 229
MYXO-FIBRO-ADENOMA arising in the region of a socia parotidis (H. D. Rolleston) 66

NECROSIS, fat, lesions of the pancreas with (C. F. Beadles) . . 174
NEURO-FIBROMA of brachial plexus associated with molluscum fibrosum (T. Carwardine) 27
NODULE, rheumatic, the histology of (F. J. Poynton and G. F. Still) . 324

Digitized by Google

PAGE

ŒSOPHAGUS, fusiform dilatation of (W. S. Lazarus-Barlow) . . 71
„ hypertrophy, idiopathic, of (H. D. Rolleston) . . . 69
„ involved in spheroidal-celled carcinoma of the stomach (W. S. Lazarus-Barlow) 101
„ myoma of the (H. D. Rolleston) 73

PANCREAS, atrophied; from a case of diabetes mellitus (T. W. P. Lawrence) 171
„ columnar-celled carcinoma (primary) of the tail of the (H. D. Rolleston) 171
„ lesions of the, with fat necrosis (C. F. Beadles) . . . 174
„ sarcoma of; glycosuria (T. Churton) 178

PAPILLOMA of rectum discharged spontaneously (T. Carwardine) . 133

PARALYSIS, diphtheritic, further evidence on the pathology of (F. E. Batten) 22

PARAMŒCIA COLI in hepatic cysts (A. E. Russell and E. F. Buzzard) . 149

PARIETAL BONES, symmetrical senile atrophy of (H. M. Fletcher) . 195

PEARLS, epithelial, in the tonsil (H. Walsham) . . . 65

PERNICIOUS ANÆMIA: See *Anæmia, pernicious.*

PINEAL BODY, cyst of (A. E. Garrod) 14
„ — two examples (A. E. Russell) 15
„ dilatation of central cavity of; two examples (A. W. Campbell) . 15
„ glioma of (T. W. P. Lawrence) 12
„ (1) sarcoma of, with diffused melanotic sarcoma of the surface of cerebrum; (2) alveolar sarcoma of (C. Ogle) . . . 4
„ syphilitic disease of; general remarks on the pathology and normal structure of the (J. R. Lord) 18

PITUITARY GLAND, hypertrophy of, unassociated with acromegaly (J. and T. W. P. Lawrence) 202

PROSTATE, myomata of, and vesical calculus, removed from the same patient (T. Carwardine) 183

PSEUDO-TUBERCULOSIS, Discussion on, Introductory Address (Prof. G. Sims Woodhead) 331
„ — (S. Martin) 342
„ — (J. W. Washbourn) 344
„ — (J. Galloway) 345
„ — (Prof. J. McFadyean) 347
„ — (A. G. R. Foulerton) 348
„ — (W. C. C. Pakes) 352
„ — (W. S. Lazarus-Barlow) 353
„ — (F. J. Wethered) 357
„ — (Prof. Woods Hutchinson) 357
„ report of committee upon the nomenclature of the conditions sometimes described as 361

PYLORUS: See *Stomach.*

RECTUM, enterolith from (S. G. Shattock) 134
„ villous papilloma of, discharged spontaneously (T. Carwardine) . 133

RECURRENT LARYNGEAL NERVES, pressure on, by calcareous glands; anthracosis of the lungs (N. Dalton) 31

Digitized by Google

PAGE

REPORT OF THE MORBID GROWTHS COMMITTEE upon Mr. C. D. Green's case of umbilical papilloma in a woman æt. 50 . . 247
„ upon Mr. A. E. Barker's specimen of recurrent cystic disease, originally arising in the thyroid (?) 254
„ **OF COMMITTEE** upon the nomenclature of the conditions sometimes described as pseudo-tuberculosis 361

RHEUMATIC NODULE, the histology of (F. J. Poynton and G. F. Still) . 324

SARCOMA, giant-celled, of the neck (H. J. Waring) . . . 232
„ melanotic, with secondary growths of unusual size in the small intestine (H. C. Thomson) 237
„ round-celled, involving the region of the pancreas, the adrenals, liver, and left lung (C. F. Beadles) 239
„ round-celled, of pancreas; diabetes mellitus (T. Churton) . . 178
„ round-celled, of spinal cord, in a child (F. E. Batten) . . 21
„ melanotic, of pineal body, with diffuse formation on surface of cerebrum (C. Ogle) 4
„ alveolar, of pineal body (C. Ogle) 4
„ spindle-celled, central, of calcaneum (P. de Santi) . . . 198

SKIN, epithelial tumours of, probably congenital in origin (H. R. Crocker) 220

SOCIA PAROTIDIS, myxo-fibro-adenoma arising in the region of (H. D. Rolleston) 66

SPINAL COLUMN, crushed fracture of, in cervical region (H. P. Potter) . 196

SPINAL CORD, sarcomata involving the, in a child æt. 3 years (F. E. Batten) 21

SPLENIC ANÆMIA with internal hæmorrhages in infants (G. B. Hunt) . 209

SPRUE, three cases of (J. H. Drysdale) 114

STOMACH, multiple erosion of the mucosa of (H. D. Rolleston) . . 73
„ ulcer of, from a patient with chronic nephritis (H. D. Rolleston) . 75
„ tubercular ulcer of, in children; five cases (G. F. Still) . . 76
„ tubercular ulceration of, in a child (T. D. Lister) . . . 83
„ pylorus, congenital hypertrophy of, three cases, with table of normal measurements (G. F. Still) 86
„ — — (H. M. Fletcher) 98
„ myoma of (A. G. R. Foulerton) 85
„ cardia, carcinoma of (H. D. Rolleston) 99
„ — — (A. F. Voelcker) 100
„ colloid carcinoma of (R. G. Hebb) 102
„ spheroidal-celled carcinoma of, involving the œsophagus (W. S. Lazarus-Barlow) 101
„ carcinoma developing in the scar of a gastric ulcer (H. R. B. Hickman) 109
„ gastrectomy for carcinoma of; death forty hours afterwards; infiltration of œsophagus (T. F. Chavasse) 105

SUBMAXILLARY SALIVARY GLAND, adeno-lipoma of (H. J. Waring) . 67

SUPPURATION of knee-joint, apparently aseptic; phagocytosis of extravasated red blood-corpuscles by leucocytes (F. W. Andrewes) . . 199

SUPRA-RENAL BODY: See *Adrenal*.

SYPHILIS, cirrhosis of liver apparently due to congenital, with thrombosis of the hepatic veins (T. Churton) 145
„ congenital, diffuse infiltration of liver in (H. M. Fletcher) . . 138
„ diffuse change in liver (adult) (F. P. Weber) . . . 142

Digitized by Google

PAGE

SYPHILITIC disease of the pineal body (J. R. Lord) . . . 18
„ stricture of bile-ducts (W. S. Lazarus-Barlow) . . . 158

TESTICLE, an undescended left (A. F. Voelcker) . . . 183

THROMBOSIS of left ventricle; typhoid fever; embolism of the right common iliac artery, etc. (W. Hunter) 52
„ of the hepatic veins; cirrhosis of liver apparently due to congenital syphilis (T. Churton) 145
„ of hepatic vein, associated with cirrhosis of the liver, probably syphilitic (W. S. Lazarus-Barlow) 146
„ hepatic and portal, condition of liver in (H. D. Rolleston) . . 148

TONGUE, actinomycosis of (L. Cooper) 61
„ congenital cyst of the base of (R. Johnson) . . . 62

TONSIL, epithelial pearls in the (H. Walsham) . . . 65

TOXICITY of normal urine; experiments upon (W. P. Herringham) . 293

TRACHEA, transverse fracture of the cartilaginous portion; fractures of sternum and ribs (W. S. Lazarus-Barlow) . . . 32
„ ulcer (probably syphilitic) of, involving the left recurrent laryngeal nerve and perforating the aorta (N. Dalton) . . . 30

TUBERCULOSIS, congenital, in calves (J. McFadyean) . . 268

UNSOUND MEAT, on infections caused by, more especially with regard to the *Bacillus enteritidis* (Gärtner) (H. E. Durham) . . 262

URINE, experiments upon the toxicity of normal (W. P. Herringham) . 293

VEINS, subcutaneous, an apparent thickening of (F. P. Weber) . 57

VENA CAVA, inferior, tuberculosis of (J. H. Drysdale) . . 60

VENTRICLE: See *Heart*.

VERMIFORM APPENDIX in which a pin had lodged; no symptoms (H. A. Lediard) 126

AUTHORS.

ANDREWES (F. W.), a case of apparently aseptic suppuration of the knee-joint, following injury, and associated with phagocytosis of extravasated red blood-corpuscles by leucocytes 199
„ fatal summer diarrhœa with acute enteritis . . . 118

BARKER (A. E.), the final sequel to a case already reported, of recurrent cystic disease of a supposed accessory thyroid . . . 251

BARWELL (R.), a case of congenital limb deficiency and redundancy . 319

BATTEN (F. E.), further evidence on the pathology of diphtheritic paralysis 22
„ sarcomata involving the spinal cord of a child æt. three years . 21

Digitized by Google

PAGE

BEADLES (C. F.), adenoma of breast, associated with cyst and calcareous degeneration 223
„ a peculiar lipoma of the groin 229
„ healed perforation of duodenum after passage of gall-stones . . 113
„ lesion of the pancreas with fat necrosis 174
„ round-celled sarcoma, involving the region of the pancreas, adrenals, liver, and left lung 239
„ some lesions of the adrenals in the insane . . . 214
„ spontaneous rupture of the heart 49

BUZZARD (E. F.) and **RUSSELL** (A. E.), cysts in the liver containing living *Paramœcia coli* 149

CAMPBELL (A. W.), notes on two cases of dilatation of the central cavity of ventricle of the pineal gland 15

CARWARDINE (T.), neuroma of brachial plexus, with molluscum fibrosum of skin 27
„ prostatic myoma and vesical calculus removed from the same patient . 183
„ villous papilloma of rectum 133

CHAVASSE (T. F.), a case of gastrectomy for carcinoma of the stomach . 105

CHURTON (T.), a case of cirrhosis of liver, apparently due to congenital syphilis, with thrombosis of the hepatic veins . . . 145
„ sarcoma of pancreas; glycosuria 178

COOPER (L.), actinomycosis of the tongue 61

CRAWFURD (R.), cystic disease of the adrenal . . . 212

CROCKER (H. R.), epithelial tumours of the skin, probably of congenital origin 220

CROSSE (W. H.) and **PAKES** (W. C. C.), black-water, or hæmoglobinuric fever 273

DALTON (N.), a case of pressure on the recurrent laryngeal nerves by calcareous glands, with anthracosis of the lungs . . . 31
„ dextrocardia; left superior cava; endocarditis . . . 41
„ hypertrophy of the right lung, with obliteration of the left . . 33
„ ulcer of the trachea involving the left recurrent laryngeal nerve, and perforating into the aorta 30

DRYSDALE (J. H.), three cases of sprue 114
„ tuberculosis of the inferior vena cava 60

DURHAM (H. E.), on infections by unsound meat, more especially with regard to the *Bacillus enteritidis* (Gärtner) . . . 263

FLETCHER (H. M.), congenital hypertrophy of the pylorus . . 98
„ extreme dilatation of the left auricle without mitral stenosis . 48
„ diffuse infiltration of the liver in congenital syphilis . . 138
„ peculiar condition of the colon in pernicious anæmia . . 127
„ symmetrical senile atrophy of the parietal bones . . . 195
„ tuberculous cavities in the liver 160

FOULERTON (A. G. R.), myoma of the stomach . . . 85
„ mycosis (aspergillar ?) of lung of horse . . . 272
„ discussion on pseudo-tuberculosis 348
„ report of sub-committee on pseudo-tuberculosis . . . 361

FREYBERGER (L.), embolism of both middle cerebral arteries, rheumatic endocarditis, and carcinoma of the pancreas and liver . . 1

Digitized by Google

PAGE

GALLOWAY (J.), discussion on pseudo-tuberculosis . . . 345

GARROD (A. E.), lung showing uniformly distributed fibrosis . . 36
„ pineal cyst 14

GREEN (C. D.), a case of carcinoma of the liver, believed to have been primary 166
„ a case of sarcoma of left lung and mediastinum . . . 37
„ a case of umbilical papilloma in a woman æt. 50, apparently arising in remains of a Meckel's diverticulum 243

HADLEY (W. J.), achroo-amyloid liver, spleen, and kidneys . . 134

HEBB (R. G.), a case of colloid carcinoma of the stomach . . 102

HERRINGHAM (W. P.), experiments upon the toxicity of normal urine . 293

HICKMAN (H. R. B.), carcinoma developing in the cicatrix of a gastric ulcer 109

HUNT (G. B.), two cases of splenic anæmia, with internal hæmorrhages, in infants 209

HUNTER (W.), heart thrombus in a case of enteric fever; embolism of the right common iliac artery; gangrene of the leg; infarcts in the spleen and kidney 52

JOHNSON (R.), congenital cyst of the base of the tongue . . 62

LATHAM (A. C.), multiple abdominal dermoids . . . 232

LAWRENCE (T. W. P.), atrophied pancreas from a case of diabetes mellitus 171
„ tumour of the pineal body 12
„ and (J.), hypertrophy of the pituitary body . . . 202

LAZARUS-BARLOW (W. S.), a case of substernal carcinoma . . 248
„ aneurysm of splenic artery 57
„ discussion on pseudo-tuberculosis 353
„ fusiform dilatation of the œsophagus 71
„ spheroidal-celled carcinoma of the stomach involving the œsophagus . 101
„ syphilitic stricture of bile-ducts 158
„ thrombosis of hepatic vein associated with cirrhosis of the liver, probably syphilitic 146
„ transverse fracture of the cartilaginous portion of the trachea . 32

LEDIARD (H. A.), appendix vermiformis in which a pin was lodged . 126
„ congenital fibroma from the neck of a child . . . 223

LISTER (T. D.), a specimen of tubercular ulceration of the stomach from a child 83
„ a specimen of diffuse ulcerative colitis with secondary acute interstitial hepatitis 130
„ a specimen of duodenal ulcer from a case of melæna neonatorum . 111

LORD (J. R.), the pineal gland: its structure; remarks on its pathology; a case of syphilitic enlargement 18

MCFADYEAN (J.), congenital tuberculosis in calves . . . 268
„ discussion on pseudo-tuberculosis 347
„ report of sub-committee on pseudo-tuberculosis . . . 361

MARTIN (S.), discussion on pseudo-tuberculosis . . . 342

Digitized by Google

PAGE

OGLE (C.), (1) sarcoma of pineal body, with diffused melanotic sarcoma of the surface of the cerebrum; (2) tumour of pineal body in a boy . 4

PAKES (W. C. C.) discussion on pseudo-tuberculosis . . . 352
„ and HOWARD (E.), the technique of blood-films . . . 328
PAYNE (J. F.), report of sub-committee on pseudo-tuberculosis . . 361
POTTER (H. P.), crushed fracture of the cervical spine . . 176
POWER (D'ARCY), cystic disease of the breast in a boy aged three years . 225
„ two unusual cases of intussusception 121
POYNTON (F. J.) and STILL (G. F.), the histology of the rheumatic nodule 324

RITCHIE (J.), the relations of chemical composition to germicidal action . 256
ROBINSON (H. B.), "butter" cyst of the breast . . . 227
„ cysts in relation with the sac of an inguinal hernia . . 230
ROLLESTON (H. D.), aneurysm of the splenic artery . . . 55
„ a tumour arising in the region of the socia parotidis . . 66
„ carcinoma of the cardiac orifice of the stomach . . . 99
„ cyst of the adrenal 214
„ gastric ulcer from a patient with granular kidneys . . 75
„ idiopathic hypertrophy of the œsophagus . . . 69
„ large myxoma of the thigh 229
„ liver in hepatic and portal thrombosis 148
„ minute erosion (exulceratio simplex) of the gastric mucosa . . 73
„ myoma of the œsophagus 73
„ primary columnar-celled carcinoma of the tail of the pancreas . 171
„ vacuolated carcinoma of the antrum 249
RUSSELL (A. E.), cysts of the pineal body 15
„ and BUZZARD (E. F.), cysts in the liver containing living *Paramœcia coli* 149

SANTI (P. DE), central sarcoma of os calcis 198
„ a case of multiple fibro-sarcomata of the scalp of nineteen years' duration; removal of growths; recurrence in the lungs . . . 234
SHATTOCK (S. G.), an acromegalic skull and that of a normal giant . 185
„ chromocyte clumping in acute pneumonia and certain other diseases, and the significance of the buffy coat in the shed blood . . 279
„ enterolith from the rectum 134
„ report of sub-committee on pseudo-tuberculosis . . . 361
STILL (G. F.), biliary calculi in children 151
„ congenital hypertrophy of the pylorus 86
„ tubercular ulcer of the stomach in children . . . 76

THOMSON (H. C.), a case of melanotic sarcoma with secondary growths of unusual size in the small intestine 237

VOELCKER (A. F.), an undescended left testicle . . . 183
„ carcinoma of the cardiac end of the stomach . . . 100

WALSHAM (H.), epithelial pearls in the tonsil . . . 65
WARING (H. J.), adeno-lipoma of the submaxillary gland . . 67
„ myeloid tumour of the neck 232

Digitized by Google

PAGE

WASHBOURN (J. W.), discussion on pseudo-tuberculosis . . 344
„ report of sub-committee on pseudo-tuberculosis . . . 361

WEBER (F. P.), acute degeneration of liver cells supervening in the course of chronic cirrhosis. 136
„ an apparent thickening of subcutaneous veins . . . 57
„ contracted kidney with multiple adenomata . . . 179
„ diffuse syphilitic change in the liver 142
„ small lipoma of kidney 181

WETHERED (F. J.), discussion on pseudo-tuberculosis . . 357

WILSON (T. S.), on dilatation of the right ventricle upwards and to the left 41

WOODHEAD (G. S.), discussion on pseudo-tuberculosis; introductory address 331
„ report of sub-committee on pseudo-tuberculosis . . . 361

WOODS-HUTCHINSON, discussion on pseudo-tuberculosis . . 357

PRINTED BY ADLARD AND SON, BARTHOLOMEW CLOSE, LONDON, E.C.

Digitized by Google

Digitized by Google

Digitized by Google

Digitized by Google

UNIVERSITY OF MICHIGAN
3 9015 02103 9790



Digitized by Google